



**PATIENT**

Oreo Bartolotta

**SPECIES**

Canine

**BREED**

Pit Bull Mix

**SEX**

Spayed Female

**AGE**

5 years

**WEIGHT**

70.4 lbs

**INTERPRETED BY**

Beth Johnson, DVM  
 DACVIM

**IMAGING PERFORMED BY**

Rebecca Hamilton

**HOSPITAL NAME**

Newton Veterinary  
 Hospital

**REFERRING VET**

Dr. Timony

**INVOICE**

11169

**DATE**

1/21/2026

**PRESENTING CLINICAL SIGNS**

- Bloody diarrhea, vomiting, decreased drinking

Abnormal PE/Chem/CBC/UA Results: Glob 4.6 ^, GGT 52 ^, TBil 1.2 ^, K 3.5 ^.

**ULTRASONOGRAPHIC EXAMINATION OF THE ABDOMEN**

**Urinary System**

The urinary bladder is adequately distended with anechoic contents. No masses, inflammatory changes, echogenic sediment or cystoliths are observed. The urinary bladder, trigone and visible pelvic urethra are normal in thickness with a smooth mucosal surface.

The right kidney is normal is size (5.74 cm), shape and echogenicity. It has smooth peripheral margination. A hyperechoic band parallel to the corticomedullary border is present. There is a normal 1:3 cortex to medulla ratio with appropriate corticomedullary distinction. There is no evidence of pyelectasia, mineral or infarcts observed.

The left kidney is normal is size (6.52 cm), shape and echogenicity. It has smooth peripheral margination. A hyperechoic band parallel to the corticomedullary border is present. There is a normal 1:3 cortex to medulla ratio with appropriate corticomedullary distinction. There is no evidence of pyelectasia, mineral or infarcts observed.

**Adrenal Glands**

The right adrenal gland is normal in size (1.0 cm at cranial pole and 0.52 cm at caudal pole), shape and overall architecture, echogenicity and echotexture. Visible surrounding vasculature appears normal.

The left adrenal gland is normal in size (0.36 cm at cranial pole and 0.48 cm at caudal pole), shape and overall architecture, echogenicity and echotexture. Visible surrounding vasculature appears normal.

**Spleen**

The spleen is subjectively normal in size with a normal smooth capsular contour. Parenchyma is appropriately finely textured and homogenous with normal echogenicity relative to surrounding tissue (hyperechoic to liver). No focal nodules or masses are observed. Splenic vasculature appears normal.

**Liver**

The liver is subjectively normal in size with normal smooth curvilinear peripheral contour. Parenchyma is appropriately hypoechoic to the spleen in echogenicity and appropriately mildly coarse and homogenous in echotexture. No focal lesions are observed. Visible vasculature and biliary tree appear normal without distension or congestion.

The gallbladder is non-distended in size. The wall is smooth without visible thickening. Luminal contents are primarily anechoic. There is no evidence of cystic or common bile duct dilation.

**Gastrointestinal**

The visible stomach wall is normal in thickness and layering. The lumen of the stomach is empty with no evidence of obstruction, foreign material or infiltrative disease. Pyloric outflow tract appears patent.



<b>PATIENT</b>	The visible small intestines are normal in wall thickness and layering. Small intestinal motility appears adequate (1-3 contractions per min). The lumen of the small intestine is empty with no evidence of obstruction, foreign material or infiltrative disease.
Oreo Bartolotta	
<b>SPECIES</b>	The visible colon is normal in wall thickness (< 0.2 cm) and layering. Contents are consistent with normal formed feces and gas.
Canine	
<b>BREED</b>	<b>Pancreas</b>
Pit Bull Mix	The pancreas that is observed appears appropriately isoechoic to surrounding omental fat. Visible capsule is smooth and normal in contour. Visible pancreatic parenchyma is homogenous and unremarkable. There is no visible pancreatic duct dilation. There is no evidence of active peripancreatic inflammation.
<b>SEX</b>	<b>Free Abdomen</b>
Spayed Female	There is no visible free peritoneal effusion noted in these images.
<b>AGE</b>	There is no apparent pathologic lymphadenopathy noted in these images.
5 years	
<b>WEIGHT</b>	<b>ULTRASONOGRAPHIC FINDINGS</b>
70.4 lbs	<ul style="list-style-type: none"> <li>Bilateral medullary rim sign - This finding is of unknown clinical significance and can be a normal variant, often idiopathic. Medullary rim sign can be present with renal disease including lymphoma, hypercalcemic nephropathy, Leptospirosis, tubular disease, other and should be interpreted in combination with other more specific indications of kidney disease such as isosthenuria, proteinuria, azotemia, etc. This is a common incidental finding in patients with diabetes mellitus.</li> </ul>
<b>INTERPRETED BY</b>	<b>INTERPRETATION OF THE FINDINGS &amp; FURTHER RECOMMENDATIONS</b>
Beth Johnson, DVM DACVIM	If not recently evaluated, a urinalysis and, if indicated based on urinalysis results, urine culture is recommended. If protein is present in an otherwise quiet sediment, protein quantification with a urine protein to creatinine ration is recommended.
<b>IMAGING PERFORMED BY</b>	Microscopic or early emerging bowel disease and/or even mild emerging pancreatitis, while not visible ultrasonographically, can't be definitively ruled out.
Rebecca Hamilton	Therefore, additional recommendations include:
<b>HOSPITAL NAME</b>	<ul style="list-style-type: none"> <li>A routine fecal/giardia exam is recommended if not recently evaluated.</li> <li>A gastrointestinal malabsorption panel (including cobalamin, folate, TLI and PLI) to Texas A&amp;M GI Laboratory is recommended for further evaluation of GI and pancreatic function.</li> <li>A fecal enteropathogen PCR panel to Texas A&amp;M GI Laboratory could be considered for further evaluation of possible infectious disease. Contact lab for recommendations on how long to discontinue antibiotics (if indicated) prior to obtaining a stool sample for submission.</li> <li>A baseline cortisol is recommended. If baseline cortisol is less than 2, a full ACTH stimulation test is recommended to rule out hypoadrenocorticism.</li> </ul>
Newton Veterinary Hospital	
<b>REFERRING VET</b>	
Dr. Timony	
<b>INVOICE</b>	
11169	
<b>DATE</b>	
1/21/2026	In the meantime:



**PATIENT**

Oreo Bartolotta

**SPECIES**

Canine

**BREED**

Pit Bull Mix

**SEX**

Spayed Female

**AGE**

5 years

**WEIGHT**

70.4 lbs

**INTERPRETED BY**

Beth Johnson, DVM  
DACVIM

**IMAGING PERFORMED BY**

Rebecca Hamilton

**HOSPITAL NAME**

Newton Veterinary  
Hospital

**REFERRING VET**

Dr. Timony

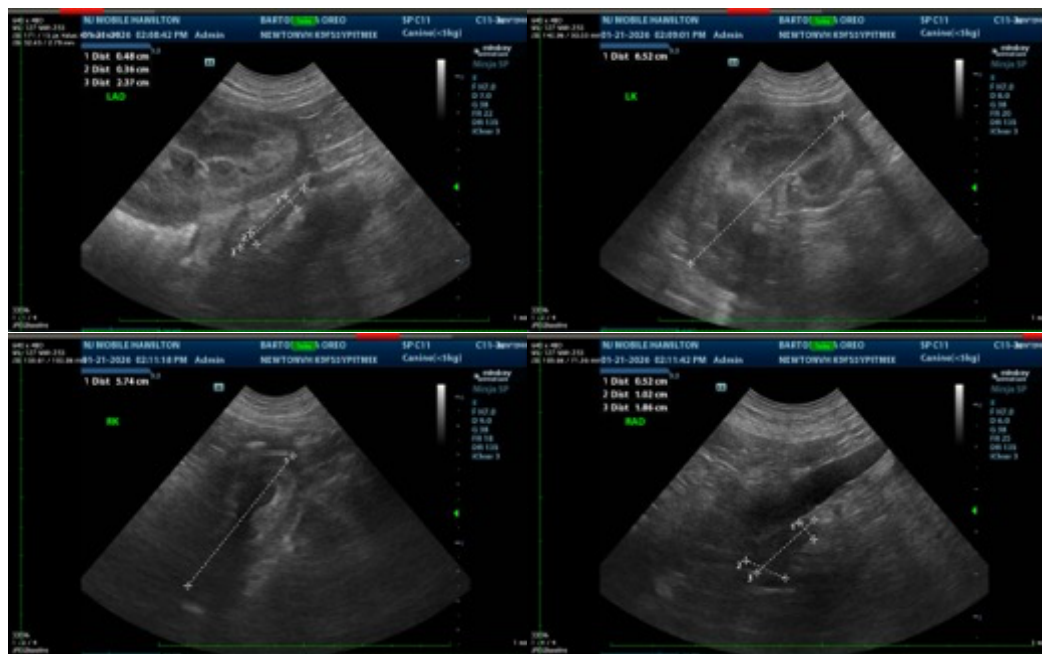
**INVOICE**

11169

**DATE**

1/21/2026

- Supportive/symptomatic medical management of clinical signs is recommended, including anti-emetics, gastroprotectants (+/- sucralfate, especially with any history of hematemesis), an appetite stimulant and fluid therapy if indicated, etc.
- Additionally, empirical deworming with a 5-day course of Panacur is recommended.
- A full course of empirical Helicobacter triple therapy could be considered.
- A probiotic, such as visbiome or proviable, may be helpful.
- Finally, if tolerated, a transition in diet could be considered, based on trial-and-error response with some options to consider including a gastrointestinal biome diet vs a hydrolyzed protein diet (sometimes several trials with different brands are necessary) vs an easy to digest, bland or low-fat diet vs other.



The information and recommendations provided are based on the images presented by the referring veterinarian/sonographer. No evaluation can be communicated regarding pathology that was not visible in the image/video clips provided.

Thank you for this referral. If the clinical or image interpretation does not parallel your findings or if I can be of any further assistance please contact me.

**Beth Johnson, DVM, DACVIM**  
info@sonopath.com