



PATIENT

Leia Williams

SPECIES

Canine

BREED

Yorkshire Terrier

SEX

FS

AGE

12 years

WEIGHT

6 lbs

INTERPRETED BY

Beth Johnson, DVM
DACVIM

IMAGING PERFORMED BY

Dr. Julia Bakker

HOSPITAL NAME

Orange Blossom
Veterinary Imaging

REFERRING VET

Dr. Alexandra Villarreal

INVOICE

11178

DATE

1/21/2026

PRESENTING CLINICAL SIGNS

- Chronic diarrhea - antibiotic responsive vs neoplasia vs IBD vs lymphangiectasia vs other.
- Chronic gastroenteritis Azotemia - renal vs pre-renal vs post renal.
- GI panel shows elevated B12 and TLI.

Abnormal PE/Chem/CBC/UA Results: B12 999 TLI >50.

ULTRASONOGRAPHIC EXAMINATION OF THE ABDOMEN

Urinary System

The urinary bladder is adequately distended with anechoic contents. No masses, inflammatory changes, echogenic sediment or cystoliths are observed. The urinary bladder, trigone and visible pelvic urethra are normal in thickness with a smooth mucosal surface.

Chronic Kidney Disease -

Left kidney is small in size (2.55 cm), right kidney is normal in size (3.32 cm), irregular and diffusely echogenic with decreased corticomedullary distinction and poor visualization of internal architecture. There is no pyelectasia noted and no mineral is observed.

Adrenal Glands

The right adrenal gland is normal in size (0.49 cm at cranial pole and 0.57 cm at caudal pole), shape and overall architecture, echogenicity and echotexture. Visible surrounding vasculature appears normal.

The left adrenal gland is normal in size (0.4 cm at cranial pole and 0.4 cm at caudal pole), shape and overall architecture, echogenicity and echotexture. Visible surrounding vasculature appears normal.

Spleen

The spleen is subjectively normal in size with a normal smooth capsular contour. Parenchyma is appropriately finely textured and homogenous with normal echogenicity relative to surrounding tissue (hyperechoic to liver). No focal nodules or masses are observed. Splenic vasculature appears normal.

Liver

The liver is subjectively normal in size with normal smooth curvilinear peripheral contour. Parenchyma is appropriately hypoechoic to the spleen in echogenicity and appropriately mildly coarse and homogenous in echotexture. No focal lesions are observed. Visible vasculature and biliary tree appear normal without distension or congestion.

Gallbladder is moderately distended with anechoic bile as well as suspended and gravity dependent echogenic debris. The wall is smooth without visible thickening. There is no evidence of cystic or CBD dilation. There is no evidence of effusion or inflammation.

Gastrointestinal

The visible stomach wall is normal in thickness and layering. The lumen of the stomach is mildly distended with echogenic non-shadowing luminal contents and gas consistent with normal ingesta. There is no evidence of obstruction or foreign material noted. Pyloric outflow tract appears patent.



PATIENT

Leia Williams

The visible small intestines are normal in wall thickness and layering. Small intestinal motility appears adequate (1-3 contractions per min). The lumen of the small intestine is empty with no evidence of obstruction, foreign material or infiltrative disease.

SPECIES

Canine

The visible colon is normal in wall thickness (< 0.2 cm) and layering. Contents are consistent with normal formed feces and gas.

Pancreas

BREED

Yorkshire Terrier

The pancreas that is observed appears appropriately isoechoic to surrounding omental fat. Visible capsule is smooth and normal in contour. Visible pancreatic parenchyma is homogenous and unremarkable. There is no visible pancreatic duct dilation. There is no evidence of active peripancreatic inflammation.

SEX

FS

Free Abdomen

AGE

12 years

There is no visible free peritoneal effusion noted in these images.

There is no apparent pathologic lymphadenopathy noted in these images.

ULTRASONOGRAPHIC FINDINGS

WEIGHT

6 lbs

- Mild gallbladder debris - Cholecystic debris is of unknown clinical significance. It can be seen with biliary stasis from fasting or illness. Cholecystic debris is not necessarily related to hepatobiliary disease. Echogenic bile is most commonly an incidental finding in dogs and should be interpreted in combination with clinical signs such as nausea, inappetence, cranial abdominal discomfort and/or laboratory changes such as increased ALP and/or increased Tbili.
- Moderate chronic kidney disease changes, most significant visibly in the left kidney.

INTERPRETED BY

Beth Johnson, DVM
DACVIM

INTERPRETATION OF THE FINDINGS & FURTHER RECOMMENDATIONS

If not recently evaluated, a urinalysis and, if indicated based on urinalysis results, urine culture is recommended. If protein is present in an otherwise quiet sediment, protein quantification with a urine protein to creatinine ration is recommended.

A blood pressure is also recommended.

A routine fecal/giardia exam is recommended if not recently evaluated.

A fecal enteropathogen PCR panel to Texas A&M GI Laboratory could be considered for further evaluation of possible infectious disease. Contact lab for recommendations on how long to discontinue antibiotics (if indicated) prior to obtaining a stool sample for submission.

INVOICE

11178

+/- A baseline cortisol is recommended. If baseline cortisol is less than 2, a full ACTH stimulation test is recommended to rule out hypoadrenocorticism.

DATE

1/21/2026

In the meantime, in addition to beginning medical management for suspected emerging chronic kidney disease, if it's appropriate based on patient's full history and workup, supportive/symptomatic medical management of clinical signs is recommended, including a probiotic (such as visbiome or proviable), empirical deworming with a 5-day course of Panacur and, if tolerated, a transition in diet, based on trial-and-error response, beginning possibly with a gastrointestinal biome diet vs a hydrolyzed protein



PATIENT

Leia Williams

SPECIES

Canine

BREED

Yorkshire Terrier

SEX

FS

AGE

12 years

WEIGHT

6 lbs

INTERPRETED BY

Beth Johnson, DVM
DACVIM

IMAGING PERFORMED BY

Dr. Julia Bakker

HOSPITAL NAME

Orange Blossom Veterinary Imaging

REFERRING VET

Dr. Alexandra Villarreal

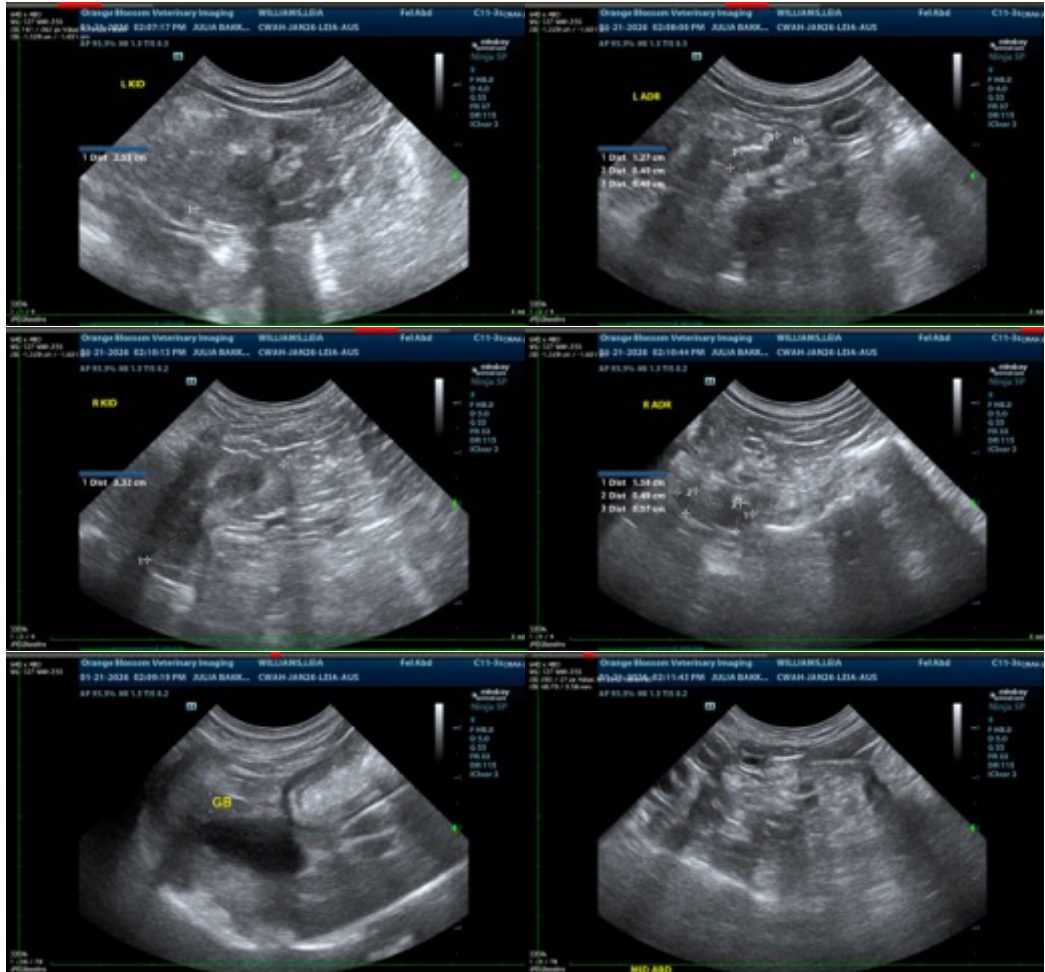
INVOICE

11178

DATE

1/21/2026

diet vs other. Some patients respond to one brand/version of a hydrolyzed protein diet better than another brand, so several brand attempts may be required.



The information and recommendations provided are based on the images presented by the referring veterinarian/sonographer. No evaluation can be communicated regarding pathology that was not visible in the image/video clips provided.

Thank you for this referral. If the clinical or image interpretation does not parallel your findings or if I can be of any further assistance please contact me.

Beth Johnson, DVM, DACVIM
info@sonopath.com