



PATIENT

Tucker Burt

SPECIES

Canine

BREED

Border Collie

SEX

Neutered Male

AGE

8 Years

WEIGHT

22.9

INTERPRETED BY

Beth Johnson, DVM
DACVIM

IMAGING PERFORMED BY

Dr. Gira

HOSPITAL NAME

Sabadilla Animal Clinic

REFERRING VET

Dr. Asemadahun

INVOICE

72284

DATE

1/20/26

PRESENTING CLINICAL SIGNS

Persistent fever, anorexia and lethargy for the past 5 days. Elevated pancreatic lipase. No coughing or diarrhea. Episodes of retching that was largely unproductive.

ULTRASONOGRAPHIC EXAMINATION OF THE ABDOMEN

Urinary System

The urinary bladder is adequately distended with anechoic contents. No masses, inflammatory changes, echogenic sediment or cystoliths are observed. The urinary bladder, trigone and visible pelvic urethra are normal in thickness with a smooth mucosal surface.

Prostate is normal in size, echotexture and echogenicity for a neutered male.

The right kidney is normal is size (5.69 cm), shape and echogenicity. It has smooth peripheral margination. There is a normal 1:3 cortex to medulla ratio with appropriate corticomedullary distinction. There is no evidence of pyelectasia, mineral or infarcts observed.

The left kidney is normal is size (5.8 cm), shape and echogenicity. It has smooth peripheral margination. There is a normal 1:3 cortex to medulla ratio with appropriate corticomedullary distinction. There is no evidence of pyelectasia or mineral observed. In the lateral aspect of the left kidney there is a small indentation that may represent a small chronic infarct.

Adrenal Glands

The right adrenal gland is normal in size (0.73 cm at cranial pole and 0.54 cm at caudal pole), shape and overall architecture, echogenicity and echotexture. Visible surrounding vasculature appears normal.

The left adrenal gland is normal in size (0.58 cm at cranial pole and 0.54 cm at caudal pole), shape and overall architecture, echogenicity and echotexture. Visible surrounding vasculature appears normal.

Spleen

The spleen is subjectively normal in size with a normal smooth capsular contour. Parenchyma is appropriately finely textured and homogenous with normal echogenicity relative to surrounding tissue (hyperechoic to liver). No focal nodules or masses are observed. Splenic vasculature appears normal.

Liver

The liver is subjectively normal in size with normal smooth curvilinear peripheral contour. Parenchyma is appropriately hypoechoic to the spleen in echogenicity and appropriately mildly coarse and homogenous in echotexture. No focal lesions are observed. Visible vasculature and biliary tree appear normal without distension or congestion.

Gallbladder is moderately distended with anechoic bile as well as suspended and gravity dependent echogenic debris. The wall is smooth without visible thickening. There is no evidence of cystic or CBD dilation. There is no evidence of effusion or inflammation.

Gastrointestinal

The visible stomach wall is normal in thickness and layering. The lumen of the stomach is empty with no evidence of obstruction, foreign material or infiltrative disease. Pyloric outflow tract appears patent.



PATIENT

Tucker Burt

The visible small intestines are normal in wall thickness and layering. Small intestinal motility appears adequate (1-3 contractions per min). The lumen of the small intestine is empty with no evidence of obstruction, foreign material or infiltrative disease.

SPECIES

Canine

The visible colon is normal in wall thickness (< 0.2 cm) and layering. The lumen is diffusely mildly distended with soft stool.

Pancreas

BREED

Border Collie

The observed pancreas appears appropriately isoechoic to surrounding omental fat. The capsule is mildly irregular in shape. Parenchyma is mildly heterogenous and coarse. There is no visible pancreatic duct dilation. There is no evidence of active peripancreatic inflammation.

SEX

Neutered Male

Free Abdomen

There is no visible free peritoneal effusion noted in these images.

AGE

8 Years

There is no apparent pathologic lymphadenopathy noted in these images.

ULTRASONOGRAPHIC FINDINGS

WEIGHT

22.9

- Moderate gallbladder debris - Cholecystic debris is of unknown clinical significance. It can be seen with biliary stasis from fasting or illness. Cholecystic debris is not necessarily related to hepatobiliary disease. Echogenic bile is most commonly an incidental finding in dogs and should be interpreted in combination with clinical signs such as nausea, inappetence, cranial abdominal discomfort and/or laboratory changes such as increased ALP and/or increased Tbili.
- Suspect emerging soft stool or diarrhea.
- Pancreatic age-related remodeling/Chronic pancreatitis – Mild irregularities are consistent with benign age-related change. Low-grade smoldering chronic pancreatitis cannot be ruled out and should be suspected in the face of appropriate clinical signs.
- Possible small chronic infarct in the left kidney.

INTERPRETED BY

Beth Johnson, DVM
DACVIM

IMAGING PERFORMED BY

Dr. Gira

HOSPITAL NAME

Sabadilla Animal Clinic

INTERPRETATION OF THE FINDINGS & FURTHER RECOMMENDATIONS

The pancreatic changes described above are very subtle/mild and subjectively not definitively causative for patient's reported fever, anorexia, etc. Therefore, further workup/diagnostics potentially outside the abdomen and potentially directed towards the now resolved leukopenia could be considered, including comprehensive infectious disease evaluation.

REFERRING VET

Dr. Asemadahun

Three view thoracic radiographs are recommended for further assessment of cardio-pulmonary status as well as to further evaluate for any evidence of metastatic disease, if not recently evaluated.

INVOICE

72284

If gastrointestinal signs are present, which I suspect, then additionally a fecal enteropathogen PCR panel to Texas A&M GI Laboratory could be considered for further evaluation of possible infectious disease. Contact lab for recommendations on how long to discontinue antibiotics (if indicated) prior to obtaining a stool sample for submission.

DATE

1/20/26

A gastrointestinal malabsorption panel (including cobalamin, folate, TLI and PLI) to Texas A&M GI Laboratory is recommended for further evaluation of GI and pancreatic function.



PATIENT

Tucker Burt

SPECIES

Canine

BREED

Border Collie

SEX

Neutered Male

AGE

8 Years

WEIGHT

22.9

INTERPRETED BY

Beth Johnson, DVM
DACVIM

IMAGING PERFORMED BY

Dr. Gira

HOSPITAL NAME

Sabadilla Animal Clinic

REFERRING VET

Dr. Asemadahun

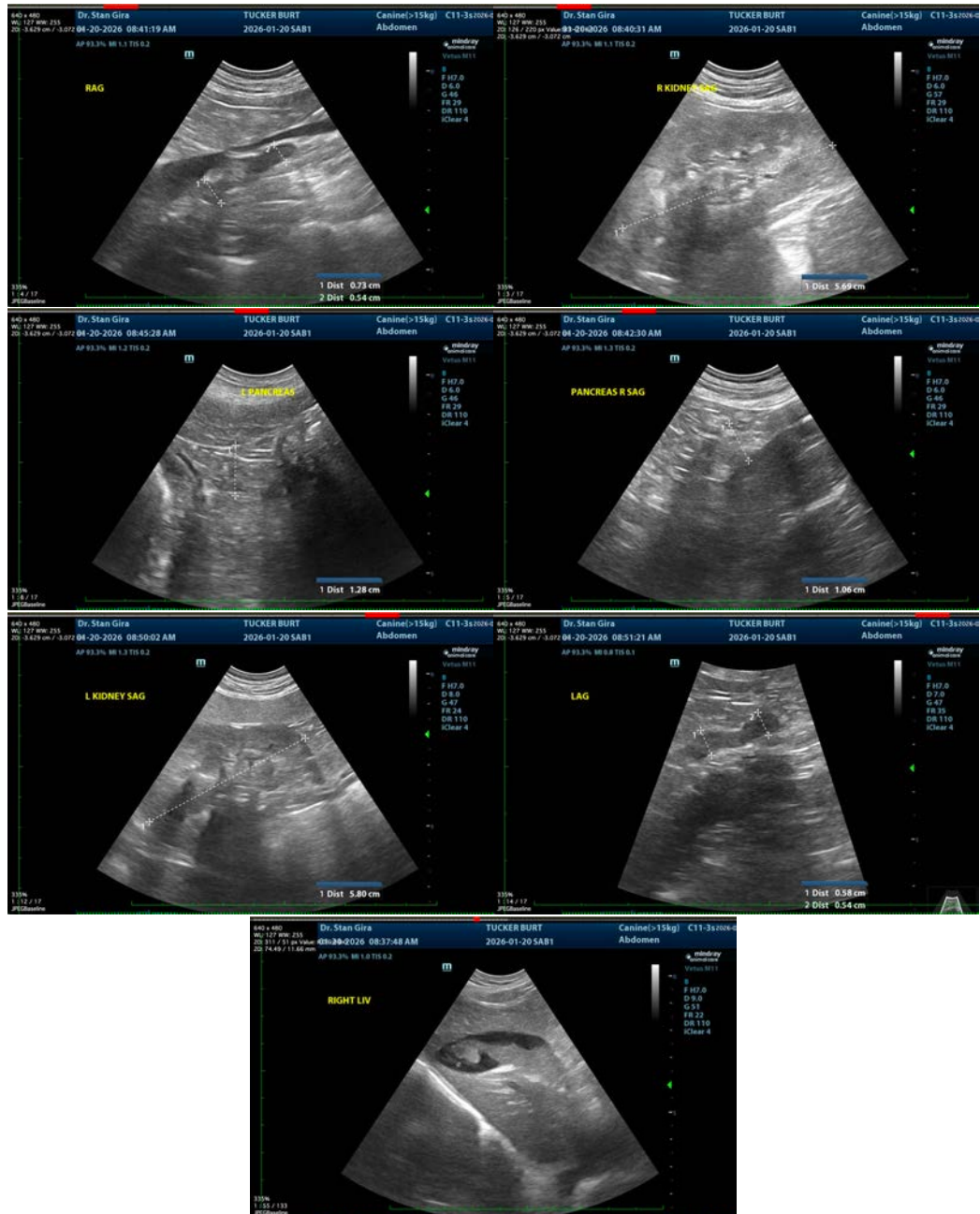
INVOICE

72284

DATE

1/20/26

Other than supportive/symptomatic medical management of clinical signs, further diagnostic and treatment recommendations are largely dependent on results of the above.





PATIENT

Tucker Burt

SPECIES

Canine

BREED

Border Collie

SEX

Neutered Male

AGE

8 Years

WEIGHT

22.9

INTERPRETED BY

Beth Johnson, DVM
DACVIM

IMAGING PERFORMED BY

Dr. Gira

HOSPITAL NAME

Sabadilla Animal Clinic

REFERRING VET

Dr. Asemadahun

INVOICE

72284

DATE

1/20/26

The information and recommendations provided are based on the images presented by the referring veterinarian/sonographer. No evaluation can be communicated regarding pathology that was not visible in the image/video clips provided.

Thank you for this referral. If the clinical or image interpretation does not parallel your findings or if I can be of any further assistance please contact me.

Beth Johnson, DVM, DACVIM
info@sonopath.com