

**DATE**

1/2/23

PRESENTING CLINICAL SIGNS

History: Elevated liver enzymes; ALT 142.

PATIENT

Mickey Bennett

Current Medications: SamE suspension 90mg/mL + Milk Thistle 10mg/mL 1 mL SID for 30 days.

Date of Previous IntraPet Ultrasound: No previous.

Sedation: Not required to complete full diagnostic ultrasound.

Stat Report: Not requested.

SPECIES

Feline

Imaging Performed By: Rachel Brillhart, RDMS.

BREED

DSH

Urinary System

Urinary bladder is adequately distended with anechoic contents. No masses, inflammatory changes, echogenic sediment or cystoliths are observed. The urinary bladder, trigone and visible pelvic urethra are normal in thickness with a smooth mucosal surface.

SEX

Spayed Female

Left kidney is normal is size (3.5 cm), shape and echogenicity. It has smooth peripheral margination. There is a normal 1:3 cortex to medulla ratio with appropriate corticomedullary distinction. There is no evidence of pyelectasia or infarcts observed. Non-obstructive linear multifocal hyperechoic diverticular foci with acoustic shadowing are noted

AGE

9/9/09

Right kidney is normal is size (3.9 cm), shape and echogenicity. It has smooth peripheral margination. There is a normal 1:3 cortex to medulla ratio with appropriate corticomedullary distinction. There is no evidence of pyelectasia observed. A small chronic infarct was noted in the right kidney. Non-obstructive linear multifocal hyperechoic diverticular foci with acoustic shadowing are noted

WEIGHT

9.7 Pounds

Adrenal Glands

Left adrenal gland is normal in size (0.38 cm), shape and overall architecture, echogenicity and echotexture. Visible surrounding vasculature appears normal.

Right adrenal gland is normal in size (0.44 cm), shape and overall architecture, echogenicity and echotexture. Visible surrounding vasculature appears normal.

INTERPRETED BY

Beth Johnson, DVM

DACVIM

HOSPITAL NAME**Spleen**

Spleen is subjectively normal in size with a normal smooth capsular contour. Parenchyma is appropriately finely textured and homogenous with normal echogenicity relative to surrounding tissue (hyperechoic to liver). No focal nodules or masses are observed. Splenic vasculature appears normal.

Liver

Liver is subjectively normal in size with normal smooth curvilinear peripheral contour. Parenchyma is appropriately hypoechoic to the spleen in echogenicity and appropriately mildly coarse and homogenous in echotexture. No focal lesions are observed. Visible vasculature and biliary tree appear normal without distension or congestion.

REFERRING VET

Dr. Esdaile

INVOICE

20343

Gallbladder is moderately distended with anechoic bile as well as suspended and gravity dependent echogenic debris. The wall is smooth without visible thickening. There is no evidence of cystic or CBD dilation. There is no evidence of effusion or inflammation.

Gastrointestinal

The visible stomach wall is normal in thickness and layering. The lumen of the stomach is empty with no evidence of obstruction, foreign material or infiltrative disease. Pyloric outflow tract appears patent.

The visible small intestine demonstrates areas of very mildly thick muscularis layer relative to mucosa (disruption of the normal 1:3 muscularis:mucosa ratio). Small intestinal submucosa is slightly irregular, thick and hyperechoic, without evident loss of layering appreciated. The lumen of the small intestine is empty with no evidence of obstruction or foreign material.

The visible colon is normal in wall thickness and layering. Contents are consistent with normal formed feces and gas.

Pancreas

The observed pancreas appears appropriately isoechoic to surrounding omental fat. Visible capsule is smooth and normal in contour. Visible pancreatic parenchyma is homogenous and unremarkable. There is no visible pancreatic duct dilation. There is no evidence of active peripancreatic inflammation.

Free Abdomen

There is no evidence of peritoneal effusion.

The mesenteric lymph nodes are prominent in size with swollen capsular contour. Normal elongated shape (length to width ratio) is maintained. There is no loss of parenchymal detail.

ULTRASONOGRAPHIC FINDINGS

Primary Findings

- Mild inflammatory bowel disease (IBD) pattern – Thick muscularis has been reported with infiltrative bowel disease including both benign inflammatory disease as well as infiltrative neoplasia such as lymphoma. No aggressive lymphadenopathy, loss of layering, etc. is noted to make lymphoma more probable, but lymphoma cannot be definitively ruled out without tissue sampling.
- Reactive mesenteric lymph nodes – infiltrative neoplastic disease cannot be ruled out but is considered less likely.

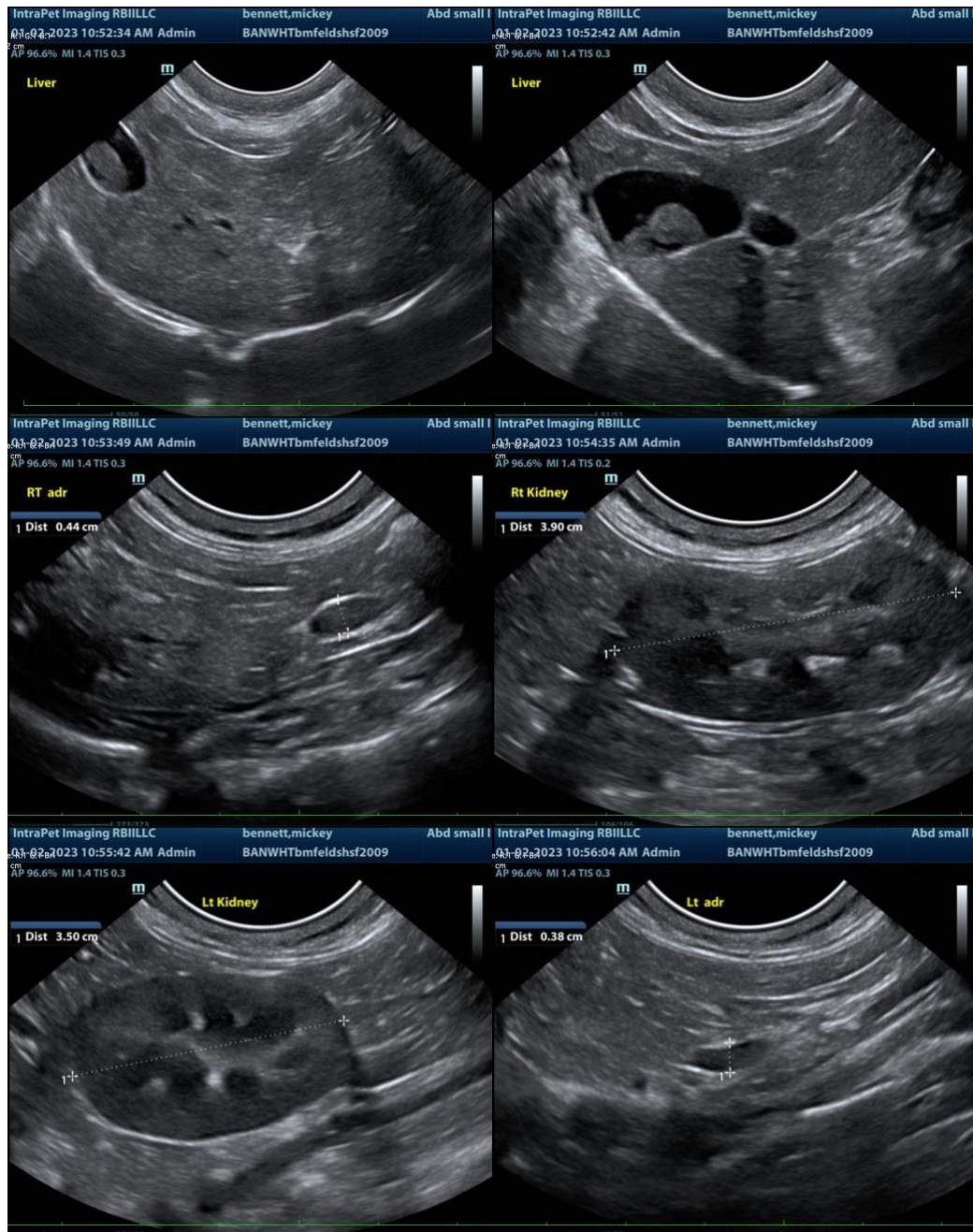
Secondary Findings

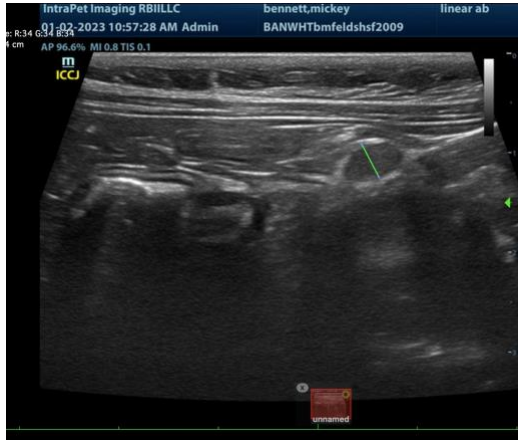- Gallbladder debris – Cholecystic debris is of unknown clinical significance. It can be seen with biliary stasis from fasting or illness, however, it can also be associated with hepatobiliary disease in cats and should be interpreted in combination with clinical signs such as nausea, inappetence, cranial abdominal discomfort and/or laboratory changes such as increased ALP and/or increased Tbili.
- Nonobstructive dystrophic mineralization bilaterally and a right kidney infarct

INTERPRETATION OF THE FINDINGS & FURTHER RECOMMENDATIONS

The findings described above are relatively mild and potentially insignificant without supporting clinical signs. Having said that, further evaluation of gastrointestinal function is recommended with a gastrointestinal malabsorption panel (including cobalamin, folate, TLI and PLI) to Texas A&M GI Laboratory.

Given the mildly increased ALT, however, the next diagnostic recommendation is a T4 and free T4 to rule out hyperthyroidism as a cause for mildly increased ALT. If hyperthyroidism is not diagnosed and ALT increases persist beyond hepatic nutraceutical management, etc., and/or progress, a fine needle aspirate of the liver is recommended if patients coagulation status is appropriate.





The information and recommendations provided are based on the images presented by the referring veterinarian. No evaluation can be communicated regarding pathology that was not visible in the image/video clips provided.

Thank you for this referral. If the clinical or image interpretation does not parallel your findings or if I can be of any further assistance please contact me.

Beth Johnson, DVM DACVIM
Beth.Johnson@SonoPath.com