

**DATE**

1/2/23

**PRESENTING CLINICAL SIGNS**

Possible weight loss but owner thinks it is an error on our part. litter pan aversion.

**PATIENT**

Harley Bridgeman

Current Medications: None.

Lab Results: mild elevations in albumin and liver values

Date of Previous IntraPet Ultrasound: No previous.

Sedation: Not required to complete full diagnostic ultrasound.

Stat Report: Not requested.

Imaging Performed By: Rachel Brillhart, RDMS.

**SPECIES**

Feline

**BREED**

DSH

**SEX**

Spayed Female

**AGE**

7/15/2009

**WEIGHT**

14.5 Pounds

**INTERPRETED BY**

Beth Johnson, DVM  
DACVIM

**HOSPITAL NAME**

Honeygo AH

**REFERRING VET**

Dr. Wright

**INVOICE**

20337

**ULTRASONOGRAPHIC EXAMINATION OF THE ABDOMEN****Urinary System**

Urinary bladder is adequately distended with anechoic contents. No masses, inflammatory changes, echogenic sediment or cystoliths are observed. The urinary bladder, trigone and visible pelvic urethra are normal in thickness with a smooth mucosal surface.

Kidneys are overall normal in size and shape with smooth peripheral margination. A normal 1:3 cortex to medulla ratio is maintained. The medulla and cortices are uniform in texture with some mild increased cortical echogenicity and mild loss of corticomedullary distinction, expected in this age patient. There is no evidence of pyelectasia, mineral or infarcts observed. The left kidney measures 4.4 cm. The right kidney measures 4.49 cm.

**Adrenal Glands**

Left adrenal gland is normal in size (0.41 cm), shape and overall architecture, echogenicity and echotexture. Visible surrounding vasculature appears normal.

Right adrenal gland is normal in size (0.58 cm), shape and overall architecture, echogenicity and echotexture. Visible surrounding vasculature appears normal.

**Spleen**

Spleen is subjectively normal in size with a normal smooth capsular contour. Parenchyma is appropriately finely textured and homogenous with normal echogenicity relative to surrounding tissue (hyperechoic to liver). Multifocal well-demarcated hyperechoic homogenous nodules are noted. Splenic vasculature appears normal.

**Liver**

Liver is subjectively enlarged (swollen contour) without disruption of architecture. It has a normal homogenous echotexture. Parenchyma is diffusely hyperechoic characterized by less prominent than normal portal vein walls and increased echogenicity relative to the spleen and falciform fat. No focal lesions are observed. Visible vasculature and biliary tree appear normal without distension or congestion.

Gallbladder is non-distended in size. The wall is smooth without visible thickening. Luminal contents are primarily anechoic. There is no evidence of cystic or common bile duct dilation.

**Gastrointestinal**

The visible stomach wall is normal in thickness and layering. The lumen of the stomach is empty with no evidence of obstruction, foreign material or infiltrative disease. Pyloric outflow tract appears patent.

The visible small intestines are normal in wall thickness and layering. Small intestinal motility appears adequate (1-3 contractions per min). The lumen of the small intestine is empty with no evidence of obstruction, foreign material or infiltrative disease. The visible colon is normal in wall thickness and layering. Contents are consistent with normal formed feces and gas.

### ***Pancreas***

The observed pancreas appears appropriately isoechoic to surrounding omental fat. The capsule is mildly irregular in shape. Parenchyma is mildly heterogenous and coarse. There is no visible pancreatic duct dilation. There is no evidence of active peripancreatic inflammation.

### ***Free Abdomen***

There is no evidence of peritoneal effusion.

The mesenteric lymph nodes are prominent in size with swollen capsular contour. Normal elongated shape (length to width ratio) is maintained. There is no loss of parenchymal detail.

## **ULTRASONOGRAPHIC FINDINGS**

### **Primary Findings**

- Hyperechoic hepatomegaly – This appearance is most consistent with benign hepatic lipidosis. Infiltrative disease such as amyloidosis or round cell neoplasia, such as mast cell tumor or less likely, lymphoma, is also possible.
- Reactive mesenteric lymph nodes – infiltrative neoplastic disease cannot be ruled out but is considered less likely.

### **Secondary Findings**

- Age-related kidney changes
- Hyperechoic splenic nodules – most consistent with benign myelolipomas. Other differentials such as fibrosis or calcification caused by old hematomas or infarcts, chronic inflammation, granulomatous disease or metastatic disease cannot be ruled out, but are considered less likely.
- Pancreatic age-related remodeling – Mild irregularities are consistent with benign age-related change. Low-grade smoldering chronic pancreatitis cannot be ruled out and should be suspected in the face of appropriate clinical signs.

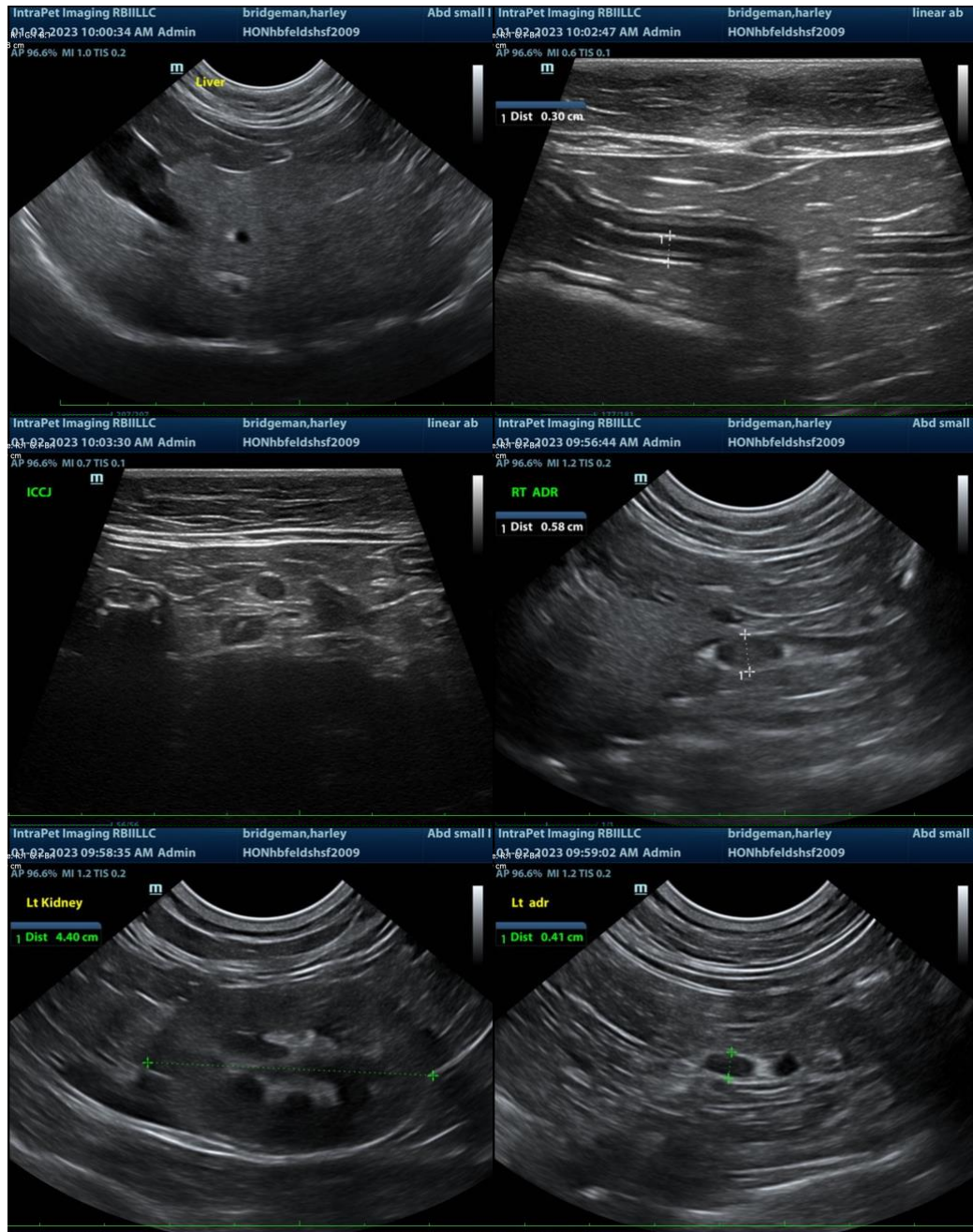
## **INTERPRETATION OF THE FINDINGS & FURTHER RECOMMENDATIONS**

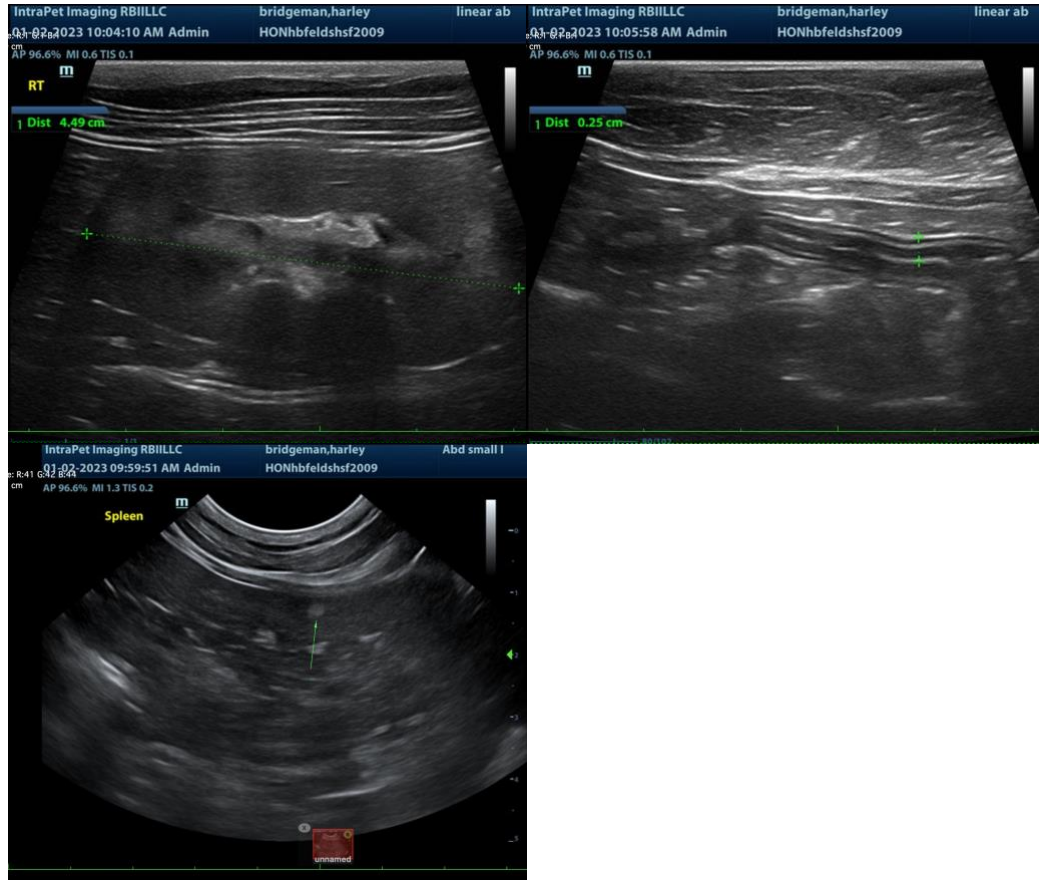
Given the appearance of this patient's liver, which can be seen with hepatic lipidosis, it could be that decreased appetite/anorexia is the cause of the reported weight loss. It can be difficult to determine daily caloric intake in a cat, especially in multiple cat household, but, if possible, close evaluation of this patient for possibly decreased appetite is recommended.

In the meantime, a fine needle aspirate of the liver could be considered if patient's coagulation status is appropriate.

Additionally, thyroid testing is recommended if not recently evaluated, i.e., T-4 and free T-4, as is, given the

mesenteric lymphadenopathy, a gastrointestinal malabsorption panel (including cobalamin, folate, TLI and PLI) to Texas A&M GI Laboratory for further evaluation of GI and pancreatic function.





The information and recommendations provided are based on the images presented by the referring veterinarian. No evaluation can be communicated regarding pathology that was not visible in the image/video clips provided.

Thank you for this referral. If the clinical or image interpretation does not parallel your findings or if I can be of any further assistance please contact me.

**Beth Johnson, DVM DACVIM**  
Beth.Johnson@SonoPath.com