



PATIENT PRESENTING CLINICAL SIGNS

PATIENT Shadowe Collett P is a 13 year old FS Rat Terrier Mix that initially presented for abdominal distension , diarrhea and inappetence on 1/17/22. 800 ml serosanguinous fluid drained from abdomen on 1/17/22. Presented for AUS on 1/19/22. Patient doing well post abdominocentesis.

SPECIES Abnormal PE/Chem/CBC/UA Results: ALP 362 HIGH 20-150 U/L ALT 148 HIGH 10-118 U/L PHOS 7.2 HIGH 2.9-6.6 mg/dL GLU 129 HIGH 60-110 mg/dL K+ 6.1 HIGH 3.7-5.8 mmol/L TP 5.2
Canine LOW 5.4-8.2 g/dL GLOB 2 LOW 2.3-5.2 g/dL

ULTRASONOGRAPHIC EXAMINATION OF THE ABDOMEN

BREED

Urinary System

BREED Rat Terrier X Urinary bladder is moderately distended with anechoic contents. No masses, inflammatory changes, echogenic sediment or cystoliths are observed. The urinary bladder, trigone and visible pelvic urethra are normal in thickness with a smooth mucosal surface.

SEX

SEX Spayed Female Right kidney is normal in size (5.2 cm), shape and echogenicity. It has smooth peripheral margination. There is a normal 1:3 cortex to medulla ratio with appropriate corticomedullary distinction. There is no evidence of pyelectasia, mineral or infarcts observed.

AGE

AGE 13 Years Left kidney is normal in size (4.4 cm), shape and echogenicity. It has smooth peripheral margination. There is a normal 1:3 cortex to medulla ratio with appropriate corticomedullary distinction. There is no evidence of pyelectasia, mineral or infarcts observed.

WEIGHT

Adrenal Glands

WEIGHT 32 Pounds Right adrenal gland is normal in size (1.8 cm long x 0.7 cm at the cranial pole and 0.7 cm at the caudal pole), shape and contour. Corticomedullary structure is unremarkable. Visible surrounding vasculature appears normal.

INTERPRETED BY

Left adrenal gland is normal in size (0.8 cm at the caudal pole, the cranial pole is not well visualized in these images), shape and contour. Corticomedullary structure is unremarkable. Visible surrounding vasculature appears normal.

Beth Johnson, DVM
DACVIM

Spleen

Spleen is subjectively normal in size with a normal smooth capsular contour. Parenchyma is appropriately finely textured and homogenous with normal echogenicity relative to surrounding tissue (hyperechoic to liver). Multifocal well-demarcated hyperechoic homogenous nodules are present. Splenic vasculature appears normal.

HOSPITAL NAME

Craig Road AH

Liver

REFERRING VET

Liver is subjectively enlarged with rounded margins. Parenchyma is heterogenous characterized by multiple poorly defined hypoechoic nodules within otherwise hyperechoic liver parenchyma. Visible vasculature appears normal.

Dr. Ukachi Ugorji

INVOICE NUMBER

34367

DATE

1/19/22

The gallbladder is moderately distended with anechoic bile and gravity dependent echogenic sediment. The wall is smooth without visible thickening. There is no evidence of cystic or CBD dilation. There is no evidence of effusion or inflammation.



PATIENT *Gastrointestinal*

Shadowe Collett The stomach wall is normal in thickness (canine < 0.5 cm and feline < 0.4 cm) and layering. The lumen of the stomach is empty with no evidence of obstruction, foreign material or infiltrative disease. Pyloric outflow tract appears patent.

SPECIES

Canine The visible small intestines are normal in wall thickness and layering (canine duodenum < 0.5 cm and feline duodenum < 0.4 cm; other < 0.3 cm). Small intestinal motility appears adequate (1-3 contractions per min). The lumen of the small intestine is empty with no evidence of obstruction, foreign material or infiltrative disease.

BREED

Rat Terrier X The visible colon is normal in wall thickness (< 0.2 cm) and layering. Contents are consistent with normal formed feces and gas.

Pancreas

SEX No pancreatic pathology is visible in these images.

Spayed Female

Free Abdomen

There is a scant amount of anechoic free fluid. There is no apparent lymphadenopathy.

AGE

13 Years

ULTRASONOGRAPHIC FINDINGS

- Heterogenous liver – Differentials for hepatic changes include both benign steroid (vacuolar) hepatopathy or extramedullary hematopoiesis as well as infiltrative round cell or metastatic neoplasia.

WEIGHT

32 Pounds

- Hyperechoic splenic nodules – most consistent with benign myelolipomas. Other differentials such as fibrosis or calcification caused by old hematomas or infarcts, chronic inflammation, granulomatous disease or metastatic disease cannot be ruled out, but are less likely.

INTERPRETED BY

Beth Johnson, DVM
DACVIM

- Gallbladder debris - Cholecystic debris is of unknown clinical significance. It can be seen with biliary stasis from fasting or illness. Cholecystic debris is not necessarily related to hepatobiliary disease. Echogenic bile is most commonly an incidental finding in dogs and should be interpreted in combination with clinical signs such as nausea, inappetence, cranial abdominal discomfort and/or laboratory changes such as increased ALP and/or increased Tbili.

HOSPITAL NAME

Craig Road AH

- Scant amount of anechoic free fluid

INTERPRETATION OF THE FINDINGS & FURTHER RECOMMENDATIONS

REFERRING VET

Dr. Ukachi Ugorji

Recommendations include a fine needle aspirate of the liver if patient's coagulation status is appropriate, as well as fluid analysis and cytology. Given this patient's low total protein and history of diarrhea, recommendations also include a gastrointestinal malabsorption panel to include TLI, PLI, folate and cobalamin to Texas A&M Gi laboratory. If albumin is low, bile acids could also be considered to help determine a cause of low albumin, which is one differential for the abdominal fluid. A urinalysis is also recommended, and if sediment is clear, but protein is present, then urine protein/creatinine ratio is also recommended.

INVOICE NUMBER

34367

DATE

1/19/22



PATIENT

Shadowe Collett

In the meantime, recommendations include transition to a low-fat diet as well as broad-spectrum antibiotics and liver support in the form of Denamarin and Ursodiol. Infiltrative neoplasia is a concern given the fluid and the liver changes. If cytology of the fluid and/or liver aspirates is non-diagnostic, next steps may include a liver biopsy. Thoracic radiographs are also recommended to further assess cardiopulmonary status as well as to look for any evidence of cardiomegaly or metastatic disease, as well as to assess for concurrent pleural effusion.

SPECIES

Canine

BREED

Rat Terrier X

SEX

Spayed Female

AGE

13 Years

WEIGHT

32 Pounds

INTERPRETED BY

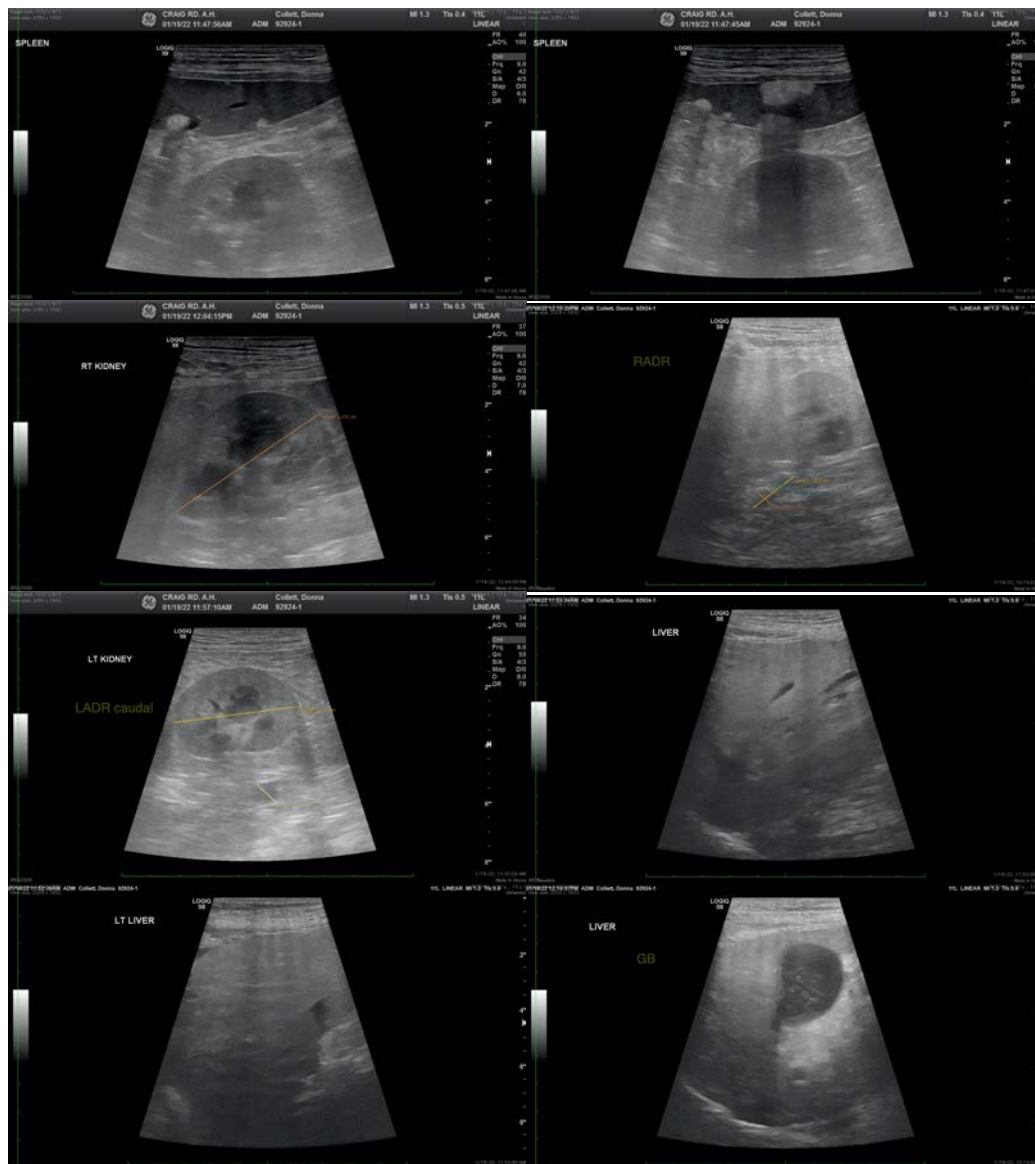
Beth Johnson, DVM
DACVIM

HOSPITAL NAME

Craig Road AH

REFERRING VET

Dr. Ukachi Ugorji



INVOICE NUMBER

34367

DATE

1/19/22



PATIENT

Shadowe Collett

SPECIES

Canine

BREED

Rat Terrier X

SEX

Spayed Female

AGE

13 Years

WEIGHT

32 Pounds

INTERPRETED BY

Beth Johnson, DVM
DACVIM

HOSPITAL NAME

Craig Road AH

REFERRING VET

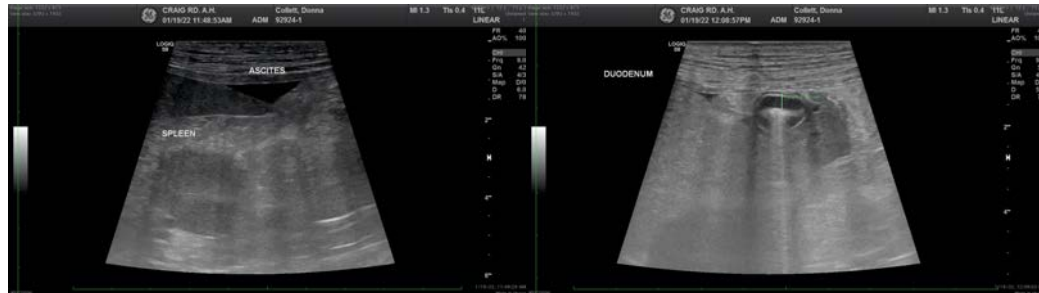Dr. Ukachi Ugorji

INVOICE NUMBER

34367

DATE

1/19/22



The information and recommendations provided are based on the images presented by the referring veterinarian. No evaluation can be communicated regarding pathology that was not visible in the image/video clips provided.

Thank you for this referral. If the clinical or image interpretation does not parallel your findings or if I can be of any further assistance please contact me.

Beth Johnson, DVM, DACVIM
Beth.Johnson@sonopath.com