



PATIENT

Uggs Duff

SPECIES

Feline

BREED

DLH

SEX

Neutered Male

AGE

12 Years

WEIGHT

14.5 Pounds

INTERPRETED BY

Beth Johnson, DVM
DACVIM

IMAGING PERFORMED BY

Dr. Katie Buss

HOSPITAL NAME

Kings Vet Hospital

REFERRING VET

Dr. Katie Freson

INVOICE

44325

DATE

1/18/23

PRESENTING CLINICAL SIGNS

1/3- constipation, gagging, repeat episodes since then, improves with supportive care and enema, on miralax, catlax and HP now. Normal B/W on 1/3.

ULTRASONOGRAPHIC EXAMINATION OF THE ABDOMEN

Urinary System

The urinary bladder is moderately distended with anechoic contents. No masses, inflammatory changes, echogenic sediment or cystoliths are observed. The urinary bladder, trigone and visible pelvic urethra are normal in thickness with a smooth mucosal surface.

The right kidney is normal in size (3.97 cm), shape and echogenicity. It has smooth peripheral margination. There is a normal 1:3 cortex to medulla ratio with appropriate corticomedullary distinction. There is no evidence of pyelectasia, mineral or infarcts observed.

The left kidney is normal in size (3.97 cm), shape and echogenicity. It has smooth peripheral margination. There is a normal 1:3 cortex to medulla ratio with appropriate corticomedullary distinction. There is no evidence of pyelectasia, mineral or infarcts observed.

Adrenal Glands

The adrenal glands are unable to be well visualized in these images.

Spleen

The spleen is subjectively normal in size with a normal smooth capsular contour. Parenchyma is appropriately finely textured and homogenous with normal echogenicity relative to surrounding tissue (hyperechoic to liver). No focal nodules or masses are observed. Splenic vasculature appears normal.

Liver

The liver is subjectively normal in size with normal smooth curvilinear peripheral contour. Parenchyma is appropriately hypoechoic to the spleen in echogenicity and appropriately mildly coarse and homogenous in echotexture. No focal lesions are observed. Visible vasculature and biliary tree appear normal without distension or congestion.

The gallbladder is non-distended in size. The wall is smooth without visible thickening. Luminal contents are primarily anechoic. Tortuous cystic and common bile duct noted, non-pathologically distended, which can be a normal anatomic variant in a senior cat, especially given this patient's reported normal lab work.

Gastrointestinal

The stomach wall is normal in thickness (canine < 0.5 cm and feline < 0.4 cm) and layering. The lumen of the stomach is empty with no evidence of obstruction, foreign material or infiltrative disease. Pyloric outflow tract appears patent.

The visible small intestines are normal in wall thickness and layering (canine duodenum < 0.5 cm and feline duodenum < 0.4 cm; other < 0.3 cm). Small intestinal motility appears adequate (1-3 contractions per min). The lumen of the small intestine is empty with no evidence of obstruction, foreign material or infiltrative disease.

The visible colon is normal in wall thickness (< 0.2 cm) and layering. Contents are consistent with normal formed feces and gas.



PATIENT

Uggs Duff

SPECIES

Feline

BREED

DLH

SEX

Neutered Male

AGE

12 Years

WEIGHT

14.5 Pounds

INTERPRETED BY

Beth Johnson, DVM
DACVIM

IMAGING PERFORMED BY

Dr. Katie Buss

HOSPITAL NAME

Kings Vet Hospital

REFERRING VET

Dr. Katie Freson

INVOICE

44325

DATE

1/18/23

Pancreas

The pancreatic parenchyma is appropriately isoechoic to surrounding tissue. Visible capsule is smooth and normal in contour. There is no visible pancreatic duct dilation. There is no evidence of active peripancreatic inflammation.

Free Abdomen

There is no evidence of free peritoneal effusion noted in these images.

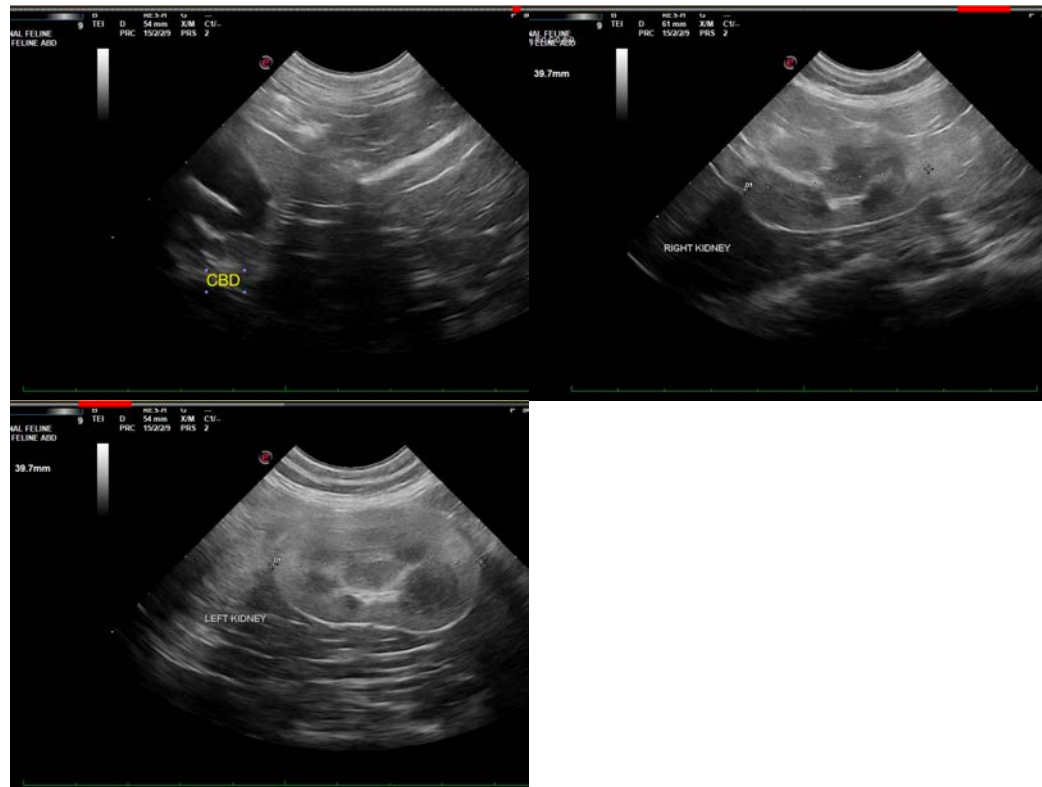
There is no apparent lymphadenopathy noted in these images.

ULTRASONOGRAPHIC FINDINGS

- Relatively unremarkable/normal abdomen

INTERPRETATION OF THE FINDINGS & FURTHER RECOMMENDATIONS

If the patient is clinically doing well on medical management for the reported constipation, then continued medical management is recommended. If clinical signs are still present or return, if tolerated, a transition in diet from the hydrolyzed protein diet to a fiber response or colitis diet could be considered. Additionally, Cisapride could be considered if necessary to help maintain clinical signs.





PATIENT

Uggs Duff

The information and recommendations provided are based on the images presented by the referring veterinarian/sonographer. No evaluation can be communicated regarding pathology that was not visible in the image/video clips provided.

SPECIES

Feline

Thank you for this referral. If the clinical or image interpretation does not parallel your findings or if I can be of any further assistance please contact me.

BREED

DLH

Beth Johnson, DVM, DACVIM
Beth.Johnson@sonopath.com

SEX

Neutered Male

AGE

12 Years

WEIGHT

14.5 Pounds

INTERPRETED BY

Beth Johnson, DVM
DACVIM

IMAGING PERFORMED BY

Dr. Katie Buss

HOSPITAL NAME

Kings Vet Hospital

REFERRING VET

Dr. Katie Freson

INVOICE

44325

DATE

1/18/23