



PATIENT

Kenzi Polcser

SPECIES

Canine

BREED

Cocker Spaniel

SEX

Spayed Female

AGE

12 Years 9 Months

WEIGHT

15

INTERPRETED BY

Beth Johnson, DVM
DACVStanglein Vet
ClinicIM

IMAGING PERFORMED BY

Jessica Green

HOSPITAL NAME

Stanglein Vet Clinic

REFERRING VET

Dr. Erin Rothrock

INVOICE

44313

DATE

1/18/23

PRESENTING CLINICAL SIGNS

P has a history of decreased proteins, chronic diarrhea and vomiting. P has historically done well on steroids and supportive care but will have recurrence of diarrhea and GI signs when prednisone is stopped or decreased... Current meds: prednisone, clindamycin, ofloxacin Ophthalmic drops, metronidazole PRN.

Abnormal PE/Chem/CBC/UA Results

WBC 38.0(h), PLT 1183(H), Neut 34580 (H), Mono 1900(H), Total protein 3.9 (L), Albumin 1.7 (L), Crt 0.4 (L) BUN 30 (H).

ULTRASONOGRAPHIC EXAMINATION OF THE ABDOMEN

Urinary System

Urinary bladder is adequately distended. It has a normal uniform wall thickness. Contents include primarily anechoic fluid with occasional echogenic non-shadowing debris, most consistent with exfoliated cells, mucous and/or small blood clots. Both sterile inflammation as well as urinary tract infection can also present with echogenic debris. No masses or cystoliths are observed. The trigone and visible pelvic urethra are normal in thickness with a smooth mucosal surface.

The right kidney is normal in size (4.91 cm), shape and echogenicity. It has smooth peripheral margination. There is a normal 1:3 cortex to medulla ratio with appropriate corticomedullary distinction. There is no evidence of pyelectasia, mineral or infarcts observed.

The left kidney is normal in size (5.25 cm), shape and echogenicity. It has smooth peripheral margination. There is a normal 1:3 cortex to medulla ratio with appropriate corticomedullary distinction. There is no evidence of pyelectasia, mineral or infarcts observed.

Adrenal Glands

The right adrenal gland is normal in size (0.42 cm at the cranial pole and 0.40 cm at the caudal pole), shape and contour. Corticomedullary structure is unremarkable. Visible surrounding vasculature appears normal.

The left adrenal gland is normal in size (1.46 cm long x 0.39 cm at the cranial pole and 0.38 cm at the caudal pole), shape and contour. Corticomedullary structure is unremarkable. Visible surrounding vasculature appears normal.

Spleen

The spleen is subjectively normal in size with a normal smooth capsular contour. Parenchyma is appropriately finely textured and homogenous with normal echogenicity relative to surrounding tissue (hyperechoic to liver). No focal nodules or masses are observed. Splenic vasculature appears normal.

Liver

Liver is subjectively enlarged (swollen contour) without disruption of architecture. It has a normal homogenous echotexture. Parenchyma is diffusely hyperechoic characterized by less prominent than normal portal vein walls and increased echogenicity relative to the spleen and falciform fat. No focal lesions are observed. Visible vasculature and biliary tree appear normal without distension or congestion.



PATIENT

Kenzi Polcser

Gallbladder is moderately distended with anechoic bile as well as moderate suspended and gravity dependent echogenic debris. The wall is smooth without visible thickening. There is no evidence of cystic or CBD dilation. There is no evidence of effusion or inflammation.

SPECIES

Canine

Gastrointestinal

The stomach wall is normal in thickness (canine < 0.5 cm and feline < 0.4 cm) and layering. The lumen of the stomach is empty with no evidence of obstruction, foreign material or infiltrative disease. Pyloric outflow tract appears patent.

BREED

Cocker Spaniel

The visible small intestines are normal in wall thickness and layering. Hyperechoic mucosal fogging or speckling is noted. Small intestinal motility appears adequate (1-3 contractions per min). The lumen is mildly distended with echogenic non-shadowing luminal contents and gas consistent with normal ingesta. There is no evidence of obstruction or foreign material noted.

SEX

Spayed Female

The visible colon is normal in wall thickness (< 0.2 cm) and layering. Contents are consistent with normal formed feces and gas.

AGE

12 Years 9 Months

Pancreas

The pancreatic parenchyma is appropriately isoechoic to surrounding tissue. Visible capsule is smooth and normal in contour. There is no visible pancreatic duct dilation. There is no evidence of active peripancreatic inflammation.

WEIGHT

15

Free Abdomen

INTERPRETED BY

Beth Johnson, DVM
DACVStanglein Vet
ClinicIM

A scant amount of anechoic free fluid is present.

In the mid abdomen, medial to both kidneys, there are ovoid structures with a cavitated/cystic appearance, most consistent with cavitated renal lymph nodes.

IMAGING PERFORMED BY

Jessica Green

ULTRASONOGRAPHIC FINDINGS

- **Hyperechoic hepatomegaly** - This appearance is non-specific and most consistent with a benign steroid (endocrine) or vacuolar hepatopathy or reactive or idiopathic hepatopathy. Inflammatory and/or infiltrative disease (such as round cell neoplasia) are also possible, but considered less likely.
- **Moderate gallbladder debris** - Cholecystic debris is of unknown clinical significance. It can be seen with biliary stasis from fasting or illness. Cholecystic debris is not necessarily related to hepatobiliary disease. Echogenic bile is most commonly an incidental finding in dogs and should be interpreted in combination with clinical signs such as nausea, inappetence, cranial abdominal discomfort and/or laboratory changes such as increased ALP and/or increased Tbili.
- **Mucosal speckling** - Mucosal speckling is often present with inflammatory bowel disease (IBD). It is not specific for type or severity of disease. Mild speckling change can occur as a normal patient variant in the post-prandial state. The appearance of this change is faint, but is likely masked in severity due to patient's current steroid regimen.
- Scant amount of anechoic free fluid - consistent with this patient's hypoalbuminemia.
- Mid abdominal cystic structures - These structures appear to be cystic renal lymph nodes, which is a finding that can occur with chronic kidney infections, etc. Infiltrative neoplasia can't be ruled out but is considered less likely.

HOSPITAL NAME

Stanglein Vet Clinic

REFERRING VET

Dr. Erin Rothrock

INVOICE

44313

DATE

1/18/23



PATIENT

Kenzi Polcser

SPECIES

Canine

BREED

Cocker Spaniel

SEX

Spayed Female

AGE

12 Years 9 Months

WEIGHT

15

INTERPRETED BY

Beth Johnson, DVM
DACVStanglein Vet
ClinicIM

IMAGING PERFORMED BY

Jessica Green

HOSPITAL NAME

Stanglein Vet Clinic

REFERRING VET

Dr. Erin Rothrock

INVOICE

44313

DATE

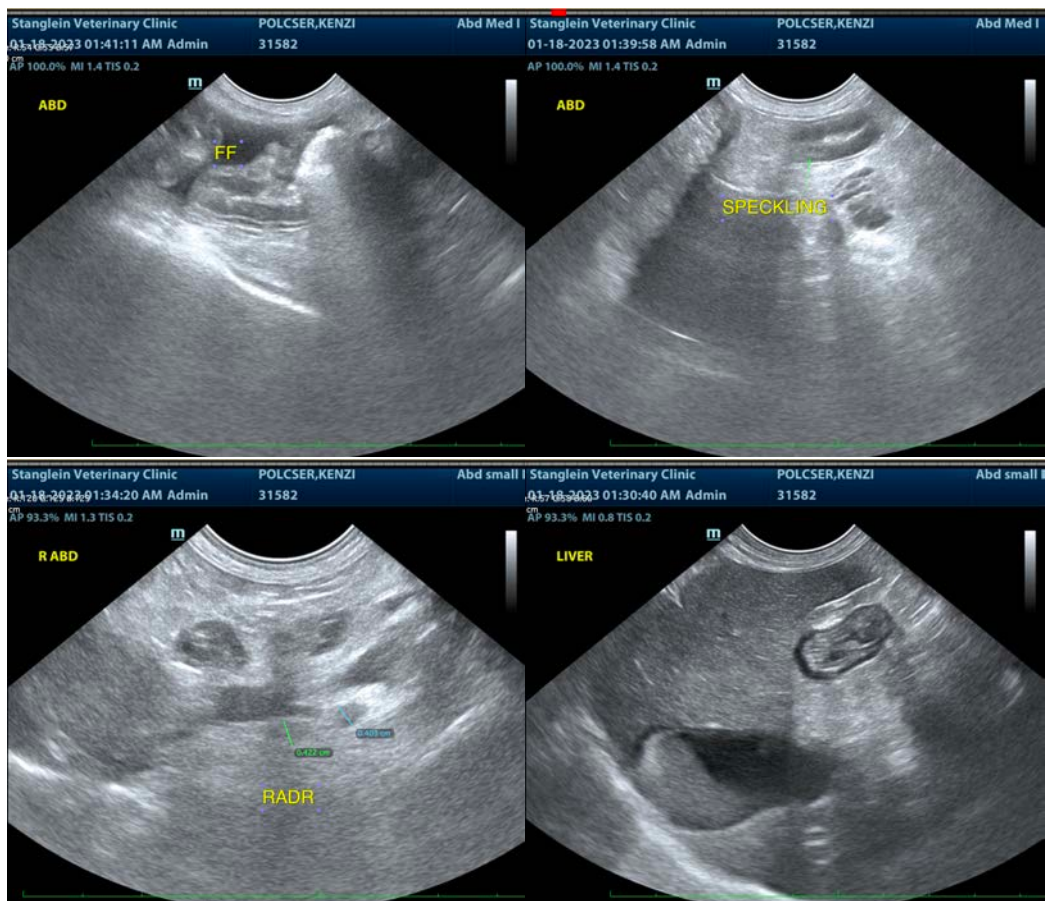
1/18/23

INTERPRETATION OF THE FINDINGS & FURTHER RECOMMENDATIONS

The pathology described above is, in general, pathology expected with chronic steroid administration as well as the previously diagnosed protein losing enteropathy bowel disease. The suspected lymph nodes near the kidneys may suggest chronic kidney infections. Therefore, if not recently evaluated, a urinalysis and, if indicated based on urinalysis results, urine culture are recommended. If protein is present in an otherwise quiet sediment, protein quantification with a urine protein to creatinine ration is recommended. Additionally, a fine needle aspirate of the cystic structures could be considered if patient's coagulation status is appropriate, to rule out a different infiltrative and/or even neoplastic disease.

Given this patient's reported inability to come off steroids without return in clinical signs, further evaluation to see if other alternative therapies may help reduce or eliminate steroids, including a fecal exam and a gastrointestinal malabsorption panel (including cobalamin, folate, TLI and PLI) to Texas A&M GI Laboratory, as well as potentially a fecal enteropathogen PCR panel to Texas A&M GI Laboratory are all recommended.

Pending results, cobalamin supplementation may help reduce or eliminate the necessity for steroids. If not already in place, transition to an ultra low-fat diet (if tolerated) is recommended. Empirical deworming with a 5-day course of Panacur is recommended, as is a probiotic such as Visbiome or Provable. Ultimately, if that still doesn't help, the addition of a 2nd immunosuppressant such as modified cyclosporin, azathioprine, etc. could be considered to allow further tapering and ideally discontinuation of the steroids.





PATIENT

Kenzi Polcser

SPECIES

Canine

BREED

Cocker Spaniel

SEX

Spayed Female

AGE

12 Years 9 Months

WEIGHT

15

INTERPRETED BY

Beth Johnson, DVM
DACVStanglein Vet
ClinicIM

IMAGING PERFORMED BY

Jessica Green

HOSPITAL NAME

Stanglein Vet Clinic

REFERRING VET

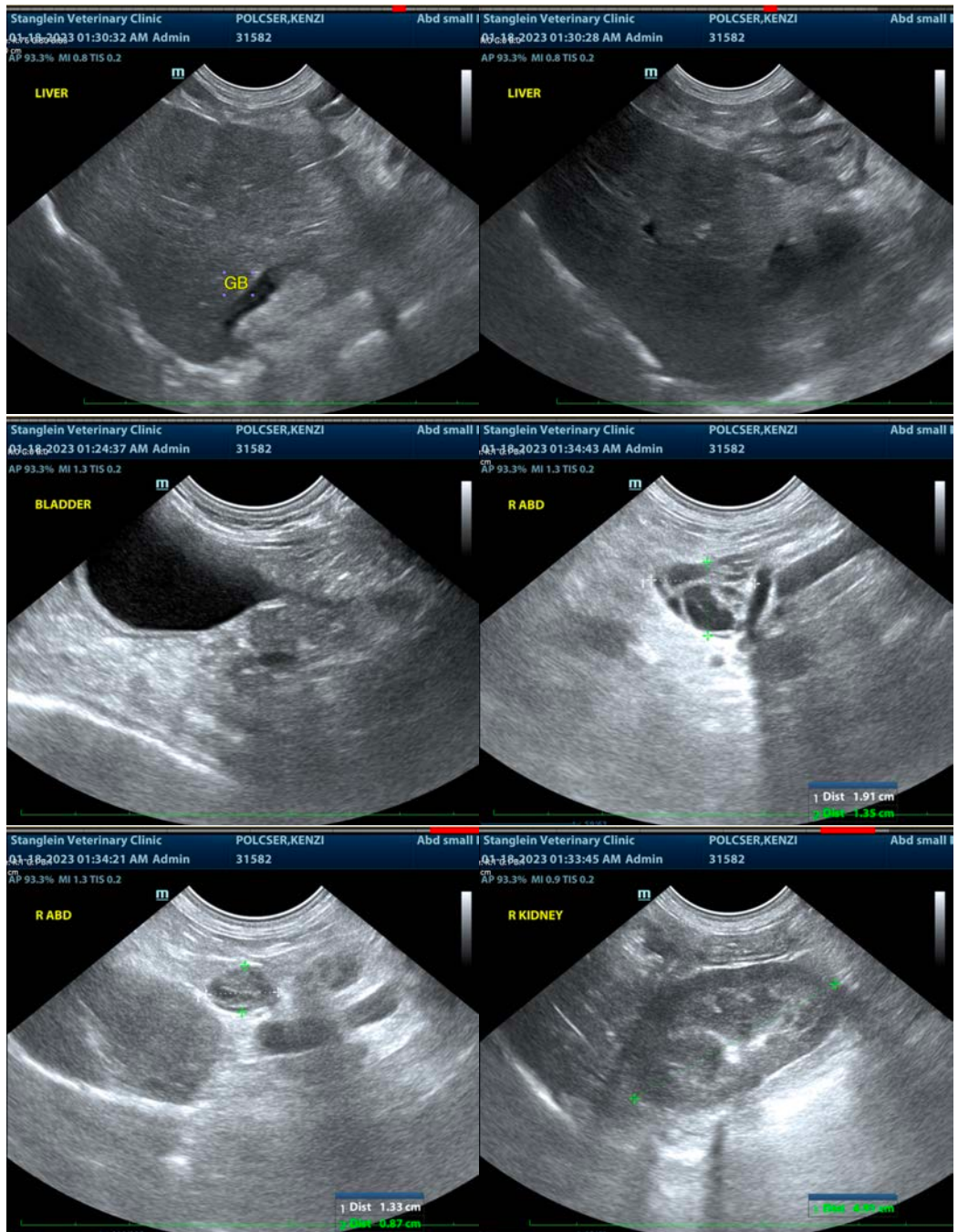
Dr. Erin Rothrock

INVOICE

44313

DATE

1/18/23





PATIENT

Kenzi Polcser

SPECIES

Canine

BREED

Cocker Spaniel

SEX

Spayed Female

AGE

12 Years 9 Months

WEIGHT

15

INTERPRETED BY

Beth Johnson, DVM
DACVStanglein Vet
ClinicIM

IMAGING PERFORMED BY

Jessica Green

HOSPITAL NAME

Stanglein Vet Clinic

REFERRING VET

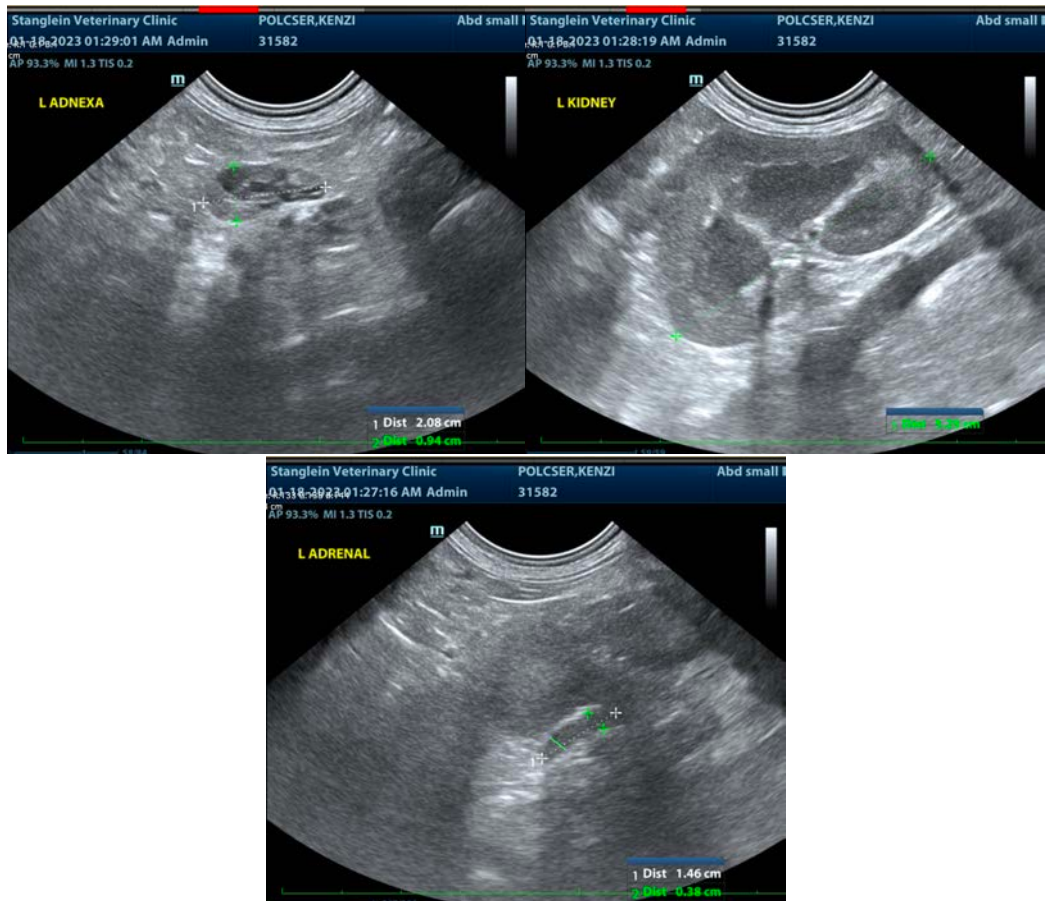
Dr. Erin Rothrock

INVOICE

44313

DATE

1/18/23



The information and recommendations provided are based on the images presented by the referring veterinarian/sonographer. No evaluation can be communicated regarding pathology that was not visible in the image/video clips provided.

Thank you for this referral. If the clinical or image interpretation does not parallel your findings or if I can be of any further assistance please contact me.

Beth Johnson, DVM, DACVIM
Beth.Johnson@sonopath.com