SonoPath
Clinical Sonography & Telecytology

EDUCATIONAL TELECONSULTATION SERVICES™

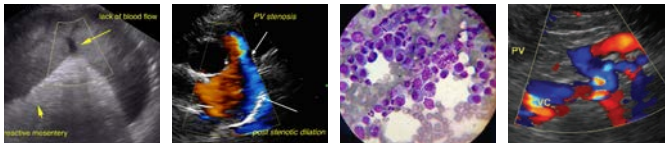

SonoPath.com™
1-800-838-4268 info@sonopath.com

PATIENT
Joey Sutton

SPECIES
Feline

BREED
DSH

SEX
Neutered Male

AGE
11 Years

WEIGHT
14.12

INTERPRETED BY
Beth Johnson, DVM
DACVIM

IMAGING PERFORMED BY
Adrianne Waffle

HOSPITAL NAME
Torch Lake VC

REFERRING VET
Dr. Janice (East Bay)

INVOICE
44315

DATE
1/18/23

PRESENTING CLINICAL SIGNS

HX of elevated globulin. Tender to abdomen. Bladder distended. P has been urinating on floor. Was seen on ER, UA - No UTI. A fast scan suggestive of thicken ureter. Gravy like consistency in stools.

ULTRASONOGRAPHIC EXAMINATION OF THE ABDOMEN

Urinary System

The urinary bladder is moderately distended with anechoic contents. No masses, inflammatory changes, echogenic sediment or cystoliths are observed. The urinary bladder, trigone and visible pelvic urethra are normal in thickness with a smooth mucosal surface.

The right kidney is normal in size (4.83 cm), shape and echogenicity. It has smooth peripheral margination. There is a normal 1:3 cortex to medulla ratio with appropriate corticomedullary distinction. There is no evidence of pyelectasia, mineral or infarcts observed.

The left kidney is normal in size (4.8 cm), shape and echogenicity. It has smooth peripheral margination. There is a normal 1:3 cortex to medulla ratio with appropriate corticomedullary distinction. There is no evidence of pyelectasia, mineral or infarcts observed.

Adrenal Glands

The area of the right adrenal gland is examined without evident adrenal gland pathology.

The left adrenal gland is normal in size (0.52 cm), shape and contour. Corticomedullary structure is unremarkable. Visible surrounding vasculature appears normal.

Spleen

The spleen is subjectively normal in size with a normal smooth capsular contour. Parenchyma is appropriately finely textured and homogenous with normal echogenicity relative to surrounding tissue (hyperechoic to liver). No focal nodules or masses are observed. Splenic vasculature appears normal.

Liver

Liver is subjectively enlarged (swollen contour) without disruption of architecture. It has a normal homogenous echotexture. Parenchyma is diffusely hyperechoic characterized by less prominent than normal portal vein walls and increased echogenicity relative to the spleen and falciform fat. No focal lesions are observed. Visible vasculature and biliary tree appear normal without distension or congestion.

The gallbladder is non-distended in size. The wall is smooth without visible thickening. Luminal contents are primarily anechoic. There is no evidence of cystic or common bile duct dilation.

Gastrointestinal

The stomach wall is normal in thickness (canine < 0.5 cm and feline < 0.4 cm) and layering. The lumen of the stomach is empty with no evidence of obstruction, foreign material or infiltrative disease. Pyloric outflow tract appears patent.

The visible small intestines are normal in wall thickness and layering (canine duodenum < 0.5 cm and feline duodenum < 0.4 cm; other < 0.3 cm). Small intestinal motility appears adequate (1-3 contractions per min). The lumen of the small intestine is empty with no evidence of obstruction, foreign material or infiltrative disease.

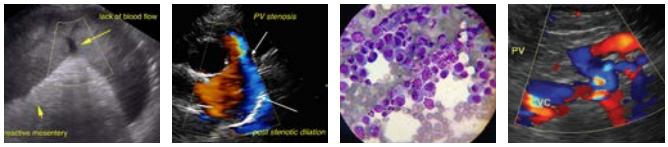

SonoPath.com™
1-800-838-4268 info@sonopath.com

PATIENT
Joey Sutton

SPECIES
Feline

BREED
DSH

SEX
Neutered Male

AGE
11 Years

WEIGHT
14.12

INTERPRETED BY
Beth Johnson, DVM DACVIM

IMAGING PERFORMED BY
Adrianne Waffle

HOSPITAL NAME
Torch Lake VC

REFERRING VET
Dr. Janice (East Bay)

INVOICE
44315

DATE
1/18/23

The visible colon is normal in wall thickness (< 0.2 cm) and layering. Contents are consistent with normal formed feces and gas.

Pancreas

Pancreas is prominent (enlarged) in size, hypoechoic to surrounding tissue and has a mildly irregular undulating contour. Parenchyma is coarse with mixed echogenic remodeling noted. Pancreatic duct dilation is noted.

Free Abdomen

There is no evidence of free peritoneal effusion noted in these images.

Medial to the tail of the spleen, there is a 0.70 cm x 0.80 cm hypoechoic structure surrounded by slightly enhanced hyperechoic mesenteric fat, believed to be an enlarged lymph node.

ULTRASONOGRAPHIC FINDINGS

- **Hyperechoic hepatomegaly** – This appearance is most consistent with benign hepatic lipidosis. Infiltrative disease such as amyloidosis or round cell neoplasia, such as mast cell tumor or less likely, lymphoma, is also possible.
- **Mid abdominal lymphadenopathy** – Both reactive lymphadenopathy as well as infiltrative neoplasia are differentials and cannot be differentiated without tissue sampling.
- Chronic active pancreatitis

INTERPRETATION OF THE FINDINGS & FURTHER RECOMMENDATIONS

There is no visible ultrasonographic evidence of urinary tract disease in this patient at this time. Given the history of soft stool, hyperglobulinemia, combined with the pathology described above, recommendations include further evaluation of gastrointestinal health as well as looking for evidence of infiltrative neoplasia or infectious disease that might result in the hyperglobulinemia. Recommendations include:

A gastrointestinal malabsorption panel (including cobalamin, folate, TLI and PLI) to Texas A&M GI Laboratory is recommended for further evaluation of GI and pancreatic function.

Serum electrophoresis could be considered to further evaluate the hyperglobulinemia.

Pending results, fine needle aspirates of the liver and the enlarged lymph node are recommended if patient's coagulation status is appropriate.

If a diagnosis of infiltrative neoplasia (i.e,. lymphoma) is not diagnosed, comprehensive infectious disease testing is recommended.

In the meantime, further evaluation of sources of orthopedic and/or neurologic pain that may be contributing to reluctance to enter the litter box is recommended.

In the face of negative urine culture(s) and no cystoliths, masses, etc., these urinary signs are most consistent with sterile cystitis or feline lower urinary tract disease (FLUTD).

Recommendations include maximizing water consumption (water fountains, canned food, etc) as well as reducing stress (recommendations can be found at Indoor Cat Initiative out of The Ohio State University CVM). Transition to a urinary health diet such as Royal Canin Urinary SO (or similar) could also be considered.

SonoPath
Clinical Sonography & Telecytology

EDUCATIONAL TELECONSULTATION SERVICES™

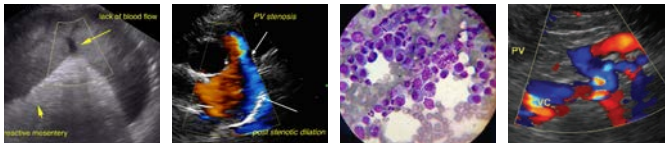

SonoPath.com™
1-800-838-4268 info@sonopath.com

PATIENT

Joey Sutton

SPECIES

Feline

BREED

DSH

SEX

Neutered Male

AGE

11 Years

WEIGHT

14.12

INTERPRETED BY

Beth Johnson, DVM
DACVIM

IMAGING PERFORMED BY

Adrianne Waffle

HOSPITAL NAME

Torch Lake VC

REFERRING VET

Dr. Janice (East Bay)

INVOICE

44315

DATE

1/18/23

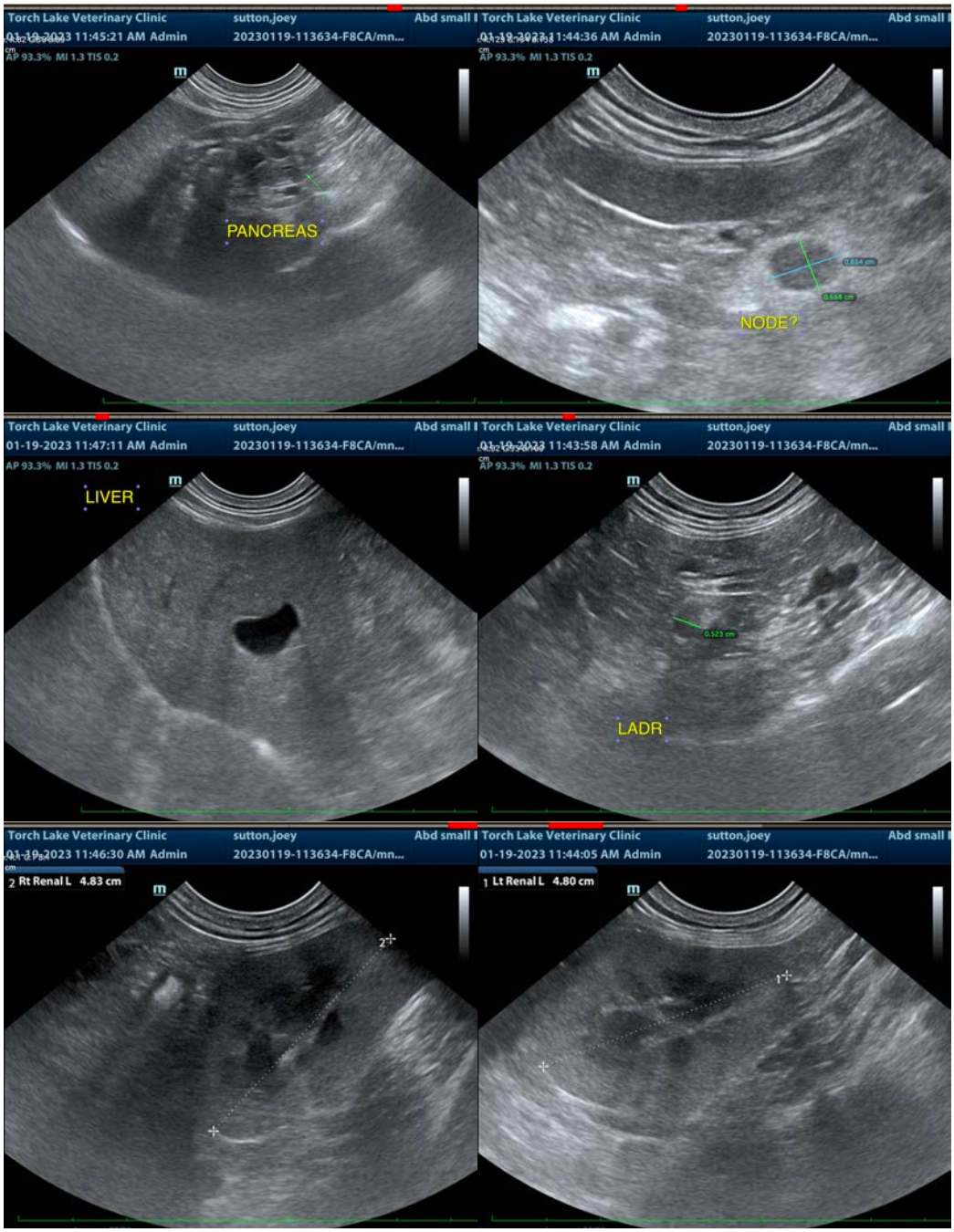

The information and recommendations provided are based on the images presented by the referring veterinarian/sonographer. No evaluation can be communicated regarding pathology that was not visible in the image/video clips provided.

Thank you for this referral. If the clinical or image interpretation does not parallel your findings or if I can be of any further assistance please contact me.

Beth Johnson, DVM, DACVIM
Beth.Johnson@sonopath.com