



PATIENT PRESENTING CLINICAL SIGNS

Elle Vukivic Inappropriate urination, ongoing.

SPECIES ULTRASONOGRAPHIC EXAMINATION OF THE ABDOMEN

Feline Urinary System

The urinary bladder is moderately distended with anechoic contents. No masses, inflammatory changes, echogenic sediment or cystoliths are observed. The urinary bladder, trigone and visible pelvic urethra are normal in thickness with a smooth mucosal surface.

BREED

Ragdoll

SEX

Spayed Female

AGE

5 Years

The right kidney is normal in size (4.07 cm), shape and echogenicity. It has smooth peripheral margination. There is a normal 1:3 cortex to medulla ratio with appropriate corticomedullary distinction. There is no evidence of pyelectasia, mineral or infarcts observed.

The left kidney is normal in size (4.42 cm), shape and echogenicity. It has smooth peripheral margination. There is a normal 1:3 cortex to medulla ratio with appropriate corticomedullary distinction. There is no evidence of pyelectasia, mineral or infarcts observed.

WEIGHT

13 Pounds

Adrenal Glands

The right adrenal gland is normal in size (0.37 cm), shape and contour. Corticomedullary structure is unremarkable. Visible surrounding vasculature appears normal.

INTERPRETED BY

Beth Johnson, DVM
DACVIM

The left adrenal gland is normal in size (0.40 cm), shape and contour. Corticomedullary structure is unremarkable. Visible surrounding vasculature appears normal.

Spleen

The spleen is subjectively normal in size with a normal smooth capsular contour. Parenchyma is appropriately finely textured and homogenous with normal echogenicity relative to surrounding tissue (hyperechoic to liver). No focal nodules or masses are observed. Splenic vasculature appears normal.

IMAGING PERFORMED BY

Kelly Reschny

Liver

The liver is subjectively normal in size with normal smooth curvilinear peripheral contour. Parenchyma is appropriately hypoechoic to the spleen in echogenicity and appropriately mildly coarse and homogenous in echotexture. No focal lesions are observed. Visible vasculature and biliary tree appear normal without distension or congestion.

HOSPITAL NAME

Beech Mobile Services

REFERRING VET

Dr. Beech

The gallbladder is non-distended in size. The wall is smooth without visible thickening. Luminal contents are primarily anechoic. There is no evidence of cystic or common bile duct dilation.

INVOICE

44312

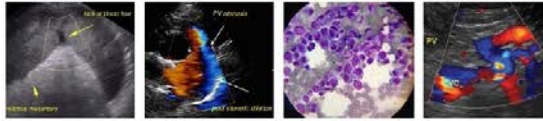
Gastrointestinal

The stomach wall is normal in thickness (canine < 0.5 cm and feline < 0.4 cm) and layering. The lumen of the stomach is empty with no evidence of obstruction, foreign material or infiltrative disease. Pyloric outflow tract appears patent.

DATE

1/18/23

The visible small intestines are normal in wall thickness and layering (canine duodenum < 0.5 cm and feline duodenum < 0.4 cm; other < 0.3 cm). Small intestinal motility appears adequate (1-3 contractions per min). The lumen of the small intestine is empty with no evidence of obstruction, foreign material or infiltrative disease.



PATIENT

The visible colon is normal in wall thickness (< 0.2 cm) and layering. Contents are consistent with normal formed feces and gas.

Elle Vukivic

Pancreas

SPECIES

The pancreatic parenchyma is appropriately isoechoic to surrounding tissue. Visible capsule is smooth and normal in contour. There is no visible pancreatic duct dilation. There is no evidence of active peripancreatic inflammation.

Feline

BREED

Free Abdomen

Ragdoll

There is no evidence of free peritoneal effusion noted in these images.

SEX

There is no apparent lymphadenopathy noted in these images.

Spayed Female

ULTRASONOGRAPHIC FINDINGS

AGE

- Relatively unremarkable/normal abdomen without an evident ultrasonographic explanation for the patient's inappropriate urination.

5 Years

WEIGHT

INTERPRETATION OF THE FINDINGS & FURTHER RECOMMENDATIONS

13 Pounds

If not recently evaluated, a general metabolic health screen is recommended, beginning with CBC/Chem panel, electrolytes, a urinalysis and, if indicated based on urinalysis results, urine culture. If protein is present in an otherwise quiet sediment, protein quantification with a urine protein to creatinine ration is recommended.

INTERPRETED BY

In the face of negative urine culture(s) and no cystoliths, masses, etc., these urinary signs are most consistent with sterile cystitis or feline lower urinary tract disease (FLUTD).

Beth Johnson, DVM
DACVIM

Recommendations include maximizing water consumption (water fountains, canned food, etc) as well as reducing stress (recommendations can be found at Indoor Cat Initiative out of The Ohio State University CVM). Transition to a urinary health diet such as Royal Canin Urinary SO (or similar) could also be considered.

IMAGING PERFORMED BY

Kelly Reschny

HOSPITAL NAME

Beech Mobile Services

REFERRING VET

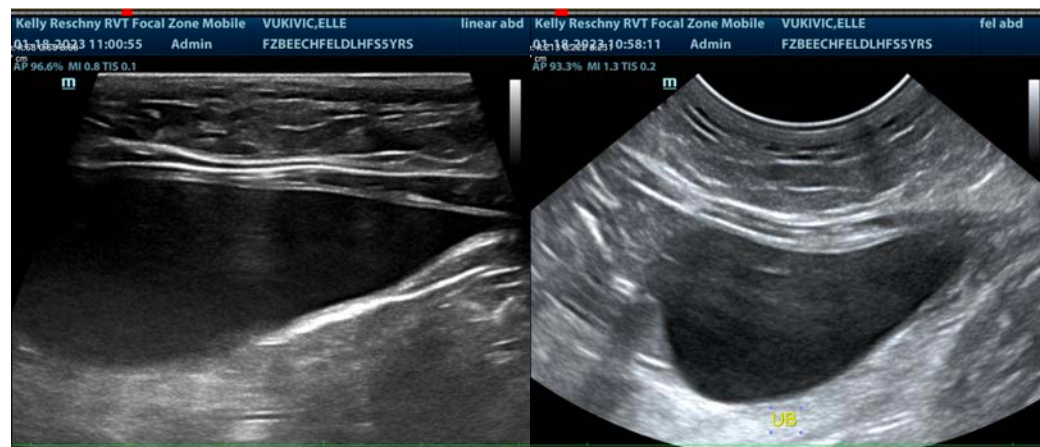
Dr. Beech

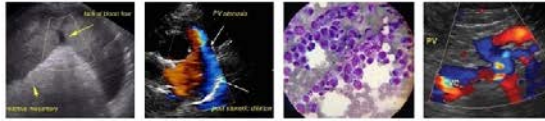
INVOICE

44312

DATE

1/18/23





PATIENT

Elle Vukivic

SPECIES

Feline

BREED

Ragdoll

SEX

Spayed Female

AGE

5 Years

WEIGHT

13 Pounds

INTERPRETED BY

Beth Johnson, DVM
DACVIM

IMAGING PERFORMED BY

Kelly Reschny

HOSPITAL NAME

Beech Mobile Services

REFERRING VET

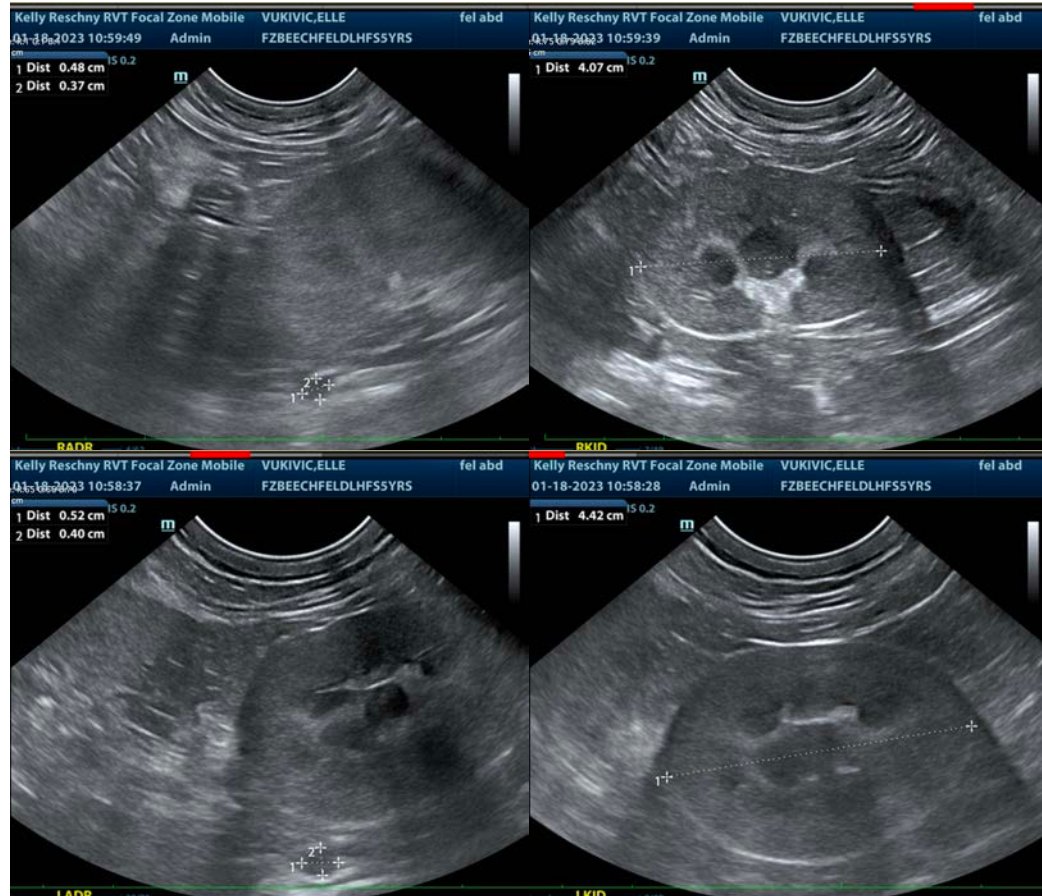
Dr. Beech

INVOICE

44312

DATE

1/18/23



The information and recommendations provided are based on the images presented by the referring veterinarian/sonographer. No evaluation can be communicated regarding pathology that was not visible in the image/video clips provided.

Thank you for this referral. If the clinical or image interpretation does not parallel your findings or if I can be of any further assistance please contact me.

Beth Johnson, DVM, DACVIM
Beth.Johnson@sonopath.com