

**PATIENT**

Scarlett Cracchiolo

SPECIES

Canine

BREED

Shih Tzu

SEX

Spayed Female

AGE

14 Years

WEIGHT

15.92 Pounds

INTERPRETED BYKathleen Sennello DVM,
MS, Diplomate ACVIM
(Small Animal Internal
Medicine)**IMAGING
PERFORMED BY**

Amy Mayhew, LVT

HOSPITAL NAME

SVS Imaging MI

REFERRING VETOxford Vet Hospital –
Dr. Steep**INVOICE**

44270

DATE

1/17/23

PRESENTING CLINICAL SIGNS

Decrease appetite.

Abnormal PE/Chem/CBC/UA Results: UA – free catch, SpG 1.030, protein +1, 3+ Ca Oxylate crystals, no associated increase in RBC, WBC and no bacteria seen UPC is upper end of borderline, Exam WNL

ULTRASONOGRAPHIC EXAMINATION OF THE ABDOMEN**Urinary System**

Urinary bladder is adequately distended. It has a normal uniform wall thickness. Contents include primarily anechoic fluid with occasional echogenic non-shadowing debris, most consistent with exfoliated cells, mucous and/or small blood clots. Both sterile inflammation as well as urinary tract infection can also present with echogenic debris. Several cystoliths are also noted with the largest one measuring 0.52 cm. No masses observed. The trigone and visible pelvic urethra are normal in thickness with a smooth mucosal surface.

Kidneys are overall normal in size and shape with smooth peripheral margination. A normal 1:3 cortex to medulla ratio is maintained. The medulla and cortices are uniform in texture with some mild increased cortical echogenicity and mild loss of corticomedullary distinction, expected in this age patient. There is no evidence of pyelectasia, or infarcts observed. The right kidney measures 4.84 cm. The left kidney measures 4.39 cm. Non-obstructive areas of mineralization/nephroliths are noted in both kidneys.

Adrenal Glands

Adrenal glands are small (flattened contour). Corticomedullary structure is unremarkable. Visible surrounding vasculature appears normal. The caudal pole of the right adrenal gland measures 0.39 cm. The cranial pole is not well visualized in these images. The left adrenal gland measures 0.33 cm at the cranial pole and 0.38 cm at the caudal pole.

Spleen

The spleen is subjectively normal in size with a normal smooth capsular contour. Parenchyma is appropriately finely textured and homogenous with normal echogenicity relative to surrounding tissue (hyperechoic to liver). No focal nodules or masses are observed. Splenic vasculature appears normal.

Liver

The liver is subjectively normal in size with normal smooth curvilinear peripheral contour. Parenchyma is appropriately hypoechoic to the spleen in echogenicity and appropriately mildly coarse and homogenous in echotexture. No focal lesions are observed. Visible vasculature and biliary tree appear normal without distension or congestion.

The gallbladder is non-distended in size. The wall is smooth without visible thickening. Luminal contents are primarily anechoic. There is no evidence of cystic or common bile duct dilation.

Gastrointestinal

Fundic mucosal hypertrophy with hyperechoic mucosa and some mucosal remodeling is noted. There is no loss of mural detail. Layering is normal. There is mild luminal fluid accumulation. No evidence of masses/nodules or foreign material present.

The visible small intestines are normal in wall thickness and layering (canine duodenum < 0.5 cm and feline duodenum < 0.4 cm; other < 0.3 cm). Small intestinal motility appears adequate (1-3 contractions

IMAGING PERFORMED BY

SVS Mobile Imaging MI 734-637-7711
svsimagingmi@gmail.com



PATIENT

Scarlett Cracchiolo

SPECIES

Canine

BREED

Shih Tzu

SEX

Spayed Female

AGE

14 Years

WEIGHT

15.92 Pounds

INTERPRETED BY

Kathleen Sennello DVM,
MS, Diplomate ACVIM
(Small Animal Internal
Medicine)

IMAGING PERFORMED BY

Amy Mayhew, LVT

HOSPITAL NAME

SVS Imaging MI

REFERRING VET

Oxford Vet Hospital –
Dr. Steep

INVOICE

44270

DATE

1/17/23

per min). The lumen of the small intestine is empty with no evidence of obstruction, foreign material or infiltrative disease.

The visible colon is normal in wall thickness (< 0.2 cm) and layering. Contents are consistent with normal formed feces and gas.

Pancreas

The pancreatic parenchyma is appropriately isoechoic to surrounding tissue. Visible capsule is smooth and normal in contour. There is no visible pancreatic duct dilation. There is no evidence of active peripancreatic inflammation.

Free Abdomen

There is no evidence of free peritoneal effusion noted in these images.

There is no apparent lymphadenopathy noted in these images.

PRIMARY FINDINGS

- **Flat adrenal glands** – This can be a normal patient variant and/or a sign of exogenous cortisol administration. If exogenous steroids are not being administered, hypoadrenocorticism (either relative or absolute) should be considered.
- **Gastritis** – Consistent with irritation secondary to dietary indiscretion or intolerance, infection (bacterial, viral, other), parasitic or protozoal disease, toxin, other metabolic disease such as pancreatitis, other. Microulceration cannot be ruled out.

SECONDARY FINDINGS

- Urinary bladder debris with several 0.5 cm cystoliths
- Age related kidney changes with non-obstructive nephroliths bilaterally

INTERPRETATION OF THE FINDINGS & FURTHER RECOMMENDATIONS

A baseline cortisol is recommended. If baseline cortisol is less than 2, a full ACTH stimulation test is recommended to rule out hypoadrenocorticism.

A gastrointestinal malabsorption panel (including cobalamin, folate, TLI and PLI) to Texas A&M GI Laboratory is recommended for further evaluation of GI and pancreatic function.

In the meantime, while awaiting results, an empirical course of antiemetics and antacid therapy such as Omeprazole, as well as empirical deworming with a 5-day course of Panacur is recommended to see if managing mild gastritis helps improve patient appetite. If a diagnosis is not obtained and clinical signs persist, next steps to consider include upper GI gastroscopy/endoscopy for further visual evaluation of the mucosa, and biopsies.

IMAGING PERFORMED BY

SVS Mobile Imaging MI 734-637-7711
svsimagingmi@gmail.com



PATIENT

Scarlett Cracchiolo

SPECIES

Canine

BREED

Shih Tzu

SEX

Spayed Female

AGE

14 Years

WEIGHT

15.92 Pounds

INTERPRETED BY

Kathleen Sennello DVM,
MS, Diplomate ACVIM
(Small Animal Internal
Medicine)

**IMAGING
PERFORMED BY**

Amy Mayhew, LVT

HOSPITAL NAME

SVS Imaging MI

REFERRING VET

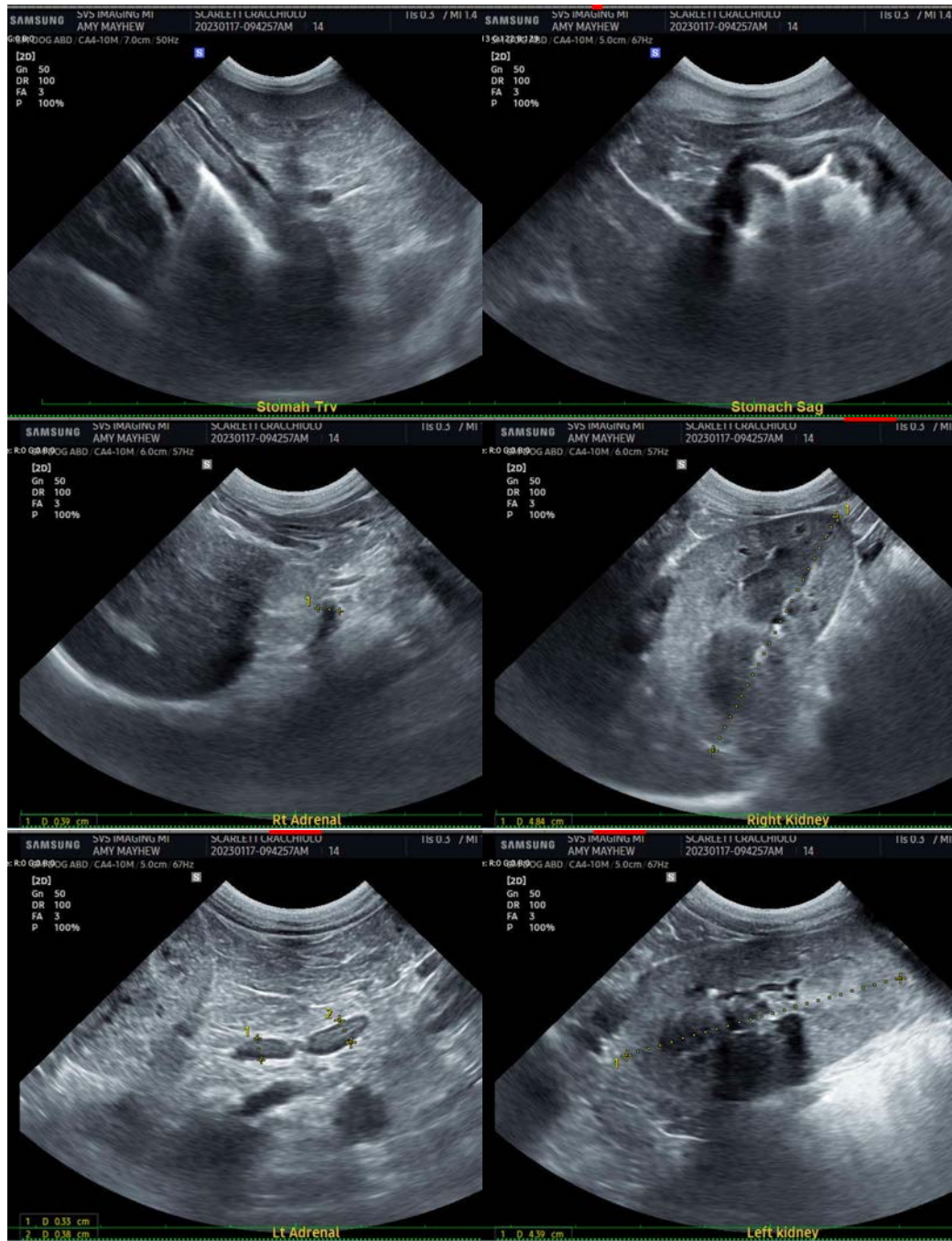
Oxford Vet Hospital –
Dr. Steep

INVOICE

44270

DATE

1/17/23



IMAGING PERFORMED BY

SVS Mobile Imaging MI 734-637-7711
svsimagingmi@gmail.com



EDUCATIONAL TELECONSULTATION SERVICES™
1-800-838-4268 info@sonopath.com SonoPath.com

PATIENT

Scarlett Cracchiolo

SPECIES

Canine

BREED

Shih Tzu

SEX

Spayed Female

AGE

14 Years

WEIGHT

15.92 Pounds

INTERPRETED BY

Kathleen Sennello DVM,
MS, Diplomate ACVIM
(Small Animal Internal
Medicine)

IMAGING PERFORMED BY

Amy Mayhew, LVT

HOSPITAL NAME

SVS Imaging MI

REFERRING VET

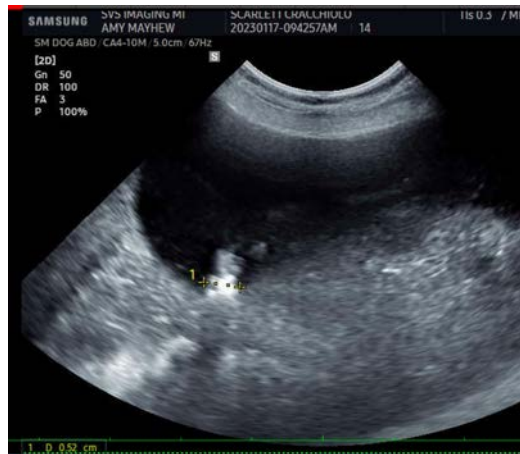Oxford Vet Hospital –
Dr. Steep

INVOICE

44270

DATE

1/17/23



The information and recommendations provided are based on the images presented by the referring veterinarian/sonographer. No evaluation can be communicated regarding pathology that was not visible in the image/video clips provided.

Thank you for this referral. If the clinical or image interpretation does not parallel your findings or if I can be of any further assistance please contact me.

Beth Johnson, DVM, DACVIM
Beth.Johnson@sonopath.com