



PATIENT

Roxy Sanchez

SPECIES

Canine

BREED

Miniature Schnauzer

SEX

Spayed Female

AGE

12 Years

WEIGHT

21 lbs

INTERPRETED BY

Beth Johnson, DVM
DACVIM

IMAGING PERFORMED BY

Gabriel Ferrer, DVM

HOSPITAL NAME

Pulse: Pet Ultrasound

REFERRING VET

Dr. Andrea Montanez

INVOICE

72279

DATE

1/15/26

PRESENTING CLINICAL SIGNS

Presented as a referral for a combine abdominal and echocardiogram to evaluate abdominal distention. Pt started to have abdominal distention and decrease appetite.

Abnormal PE/Chem/CBC/UA Results: Previous abdominal ultrasound BW attached as supporting documents.

ULTRASONOGRAPHIC EXAMINATION OF THE ABDOMEN

Urinary System

Urinary bladder is adequately distended with primarily anechoic contents and occasional echogenic non-shadowing debris. Apical urinary bladder wall is diffusely thick (0.40 cm). Mucosa is hyperechoic and irregular. No masses or cystoliths are observed. The trigone and visible pelvic urethra are normal thickness with a smooth mucosal surface.

Kidneys are overall normal in size and shape with smooth peripheral margination. A normal 1:3 cortex to medulla ratio is maintained. The medulla and cortices are uniform in texture with some mild increased cortical echogenicity and mild loss of corticomedullary distinction, expected in this age patient. There is no evidence of pyelectasia, mineral or infarcts observed. Left measures 5.58 cm. Right measures 5.79 cm.

Adrenal Glands

The right adrenal gland is normal in size (0.75 cm at cranial pole and 0.62 cm at caudal pole), shape and overall architecture, echogenicity and echotexture. Visible surrounding vasculature appears normal.

The left adrenal gland is normal in size (0.43 cm at cranial pole and 0.49 cm at caudal pole), shape and overall architecture, echogenicity and echotexture. Visible surrounding vasculature appears normal.

Spleen

Spleen is subjectively normal in size (1.6 cm thick at the hilus) with a normal smooth capsular contour. Parenchyma is appropriately finely textured and homogenous with normal echogenicity relative to surrounding tissue (hyperechoic to liver). No focal nodules or masses are observed. Multifocal mineral foci are noted. Splenic vasculature appears normal.

Liver

Liver is subjectively enlarged with mildly irregular margins. Parenchyma is mildly heterogenous characterized by multiple poorly defined hypoechoic nodules within otherwise hyperechoic liver parenchyma. Visible vasculature and biliary tree appear normal without distension or congestion

Gallbladder is moderately distended with anechoic bile as well as suspended and gravity dependent echogenic debris. The gallbladder wall is thick and edematous characterized by an intramural hypo to anechoic rim or "double rim effect or halo sign". There is no evidence of cystic or CBD dilation. There is no evidence of effusion or inflammation.

Gastrointestinal

The visible stomach wall is normal in thickness and layering. The lumen of the stomach is empty with no evidence of obstruction, foreign material or infiltrative disease. Pyloric outflow tract appears patent.



PATIENT

Roxy Sanchez

The visible small intestines are normal in wall thickness and layering. Small intestinal motility appears adequate (1-3 contractions per min). The lumen of the small intestine is empty with no evidence of obstruction, foreign material or infiltrative disease.

SPECIES

Canine

The visible colon is normal in wall thickness (< 0.2 cm) and layering. Contents are consistent with normal formed feces and gas.

BREED

Miniature Schnauzer

Pancreas

The pancreas that is observed appears appropriately isoechoic to surrounding omental fat. Visible capsule is smooth and normal in contour. Visible pancreatic parenchyma is homogenous and unremarkable. There is no visible pancreatic duct dilation. There is no evidence of active peripancreatic inflammation.

SEX

Spayed Female

Free Abdomen

There is a moderate to large amount of anechoic free fluid present in these images.

AGE

12 Years

There is no apparent pathologic lymphadenopathy noted in these images.

WEIGHT

21 lbs

PRIMARY FINDINGS

- Spleen mineralization – This is a benign change but can be associated with endocrinopathies, especially hyperadrenocorticism.
- Mildly heterogenous liver – These changes are most consistent with benign processes such as nodular hyperplasia, steroid (vacuolar) hepatopathy, extramedullary hematopoiesis or possibly chronic inflammatory disease and less commonly infiltrative round cell or metastatic neoplasia.
- Moderate gallbladder debris - Cholecystic debris is of unknown clinical significance. It can be seen with biliary stasis from fasting or illness. Cholecystic debris is not necessarily related to hepatobiliary disease. Echogenic bile is most commonly an incidental finding in dogs and should be interpreted in combination with clinical signs such as nausea, inappetence, cranial abdominal discomfort and/or laboratory changes such as increased ALP and/or increased Tbili.
- Gallbladder “halo sign” – GB wall edema is a non-specific change and can be seen with any underlying etiology (ie vasculitis, hypoalbuminemia, CHF, other) that results in edema, as well as immune-mediated disease, anaphylactic shock, other. Cholecystitis cannot be ruled out.
- The moderate to large amount of free fluid is of unknown origin. Differentials (unless already ruled out) could include increased hydrostatic pressure (cardiac disease and/or vascular or lymph blockage), decreased oncotic pressure (low albumin), vasculitis, paraneoplastic fluid, rupture/leakage of/from an organ (GI, GB, UB, other), blood (hemoabdomen), other.

INTERPRETED BY

Beth Johnson, DVM
DACVIM

IMAGING PERFORMED BY

Gabriel Ferrer, DVM

HOSPITAL NAME

Pulse: Pet Ultrasound

REFERRING VET

Dr. Andrea Montanez

INVOICE

72279

DATE

1/15/26

SECONDARY FINDINGS

- Chronic Cystitis - Urinary bladder wall changes are most consistent with chronic cystitis. Infiltrative neoplasia cannot be ruled out but is considered less likely give the location and diffuse nature of the changes.
- Age related kidney changes.



PATIENT

Roxy Sanchez

SPECIES

Canine

BREED

Miniature Schnauzer

SEX

Spayed Female

AGE

12 Years

WEIGHT

21 lbs

INTERPRETED BY

Beth Johnson, DVM
DACVIM

IMAGING PERFORMED BY

Gabriel Ferrer, DVM

HOSPITAL NAME

Pulse: Pet Ultrasound

REFERRING VET

Dr. Andrea Montanez

INVOICE

72279

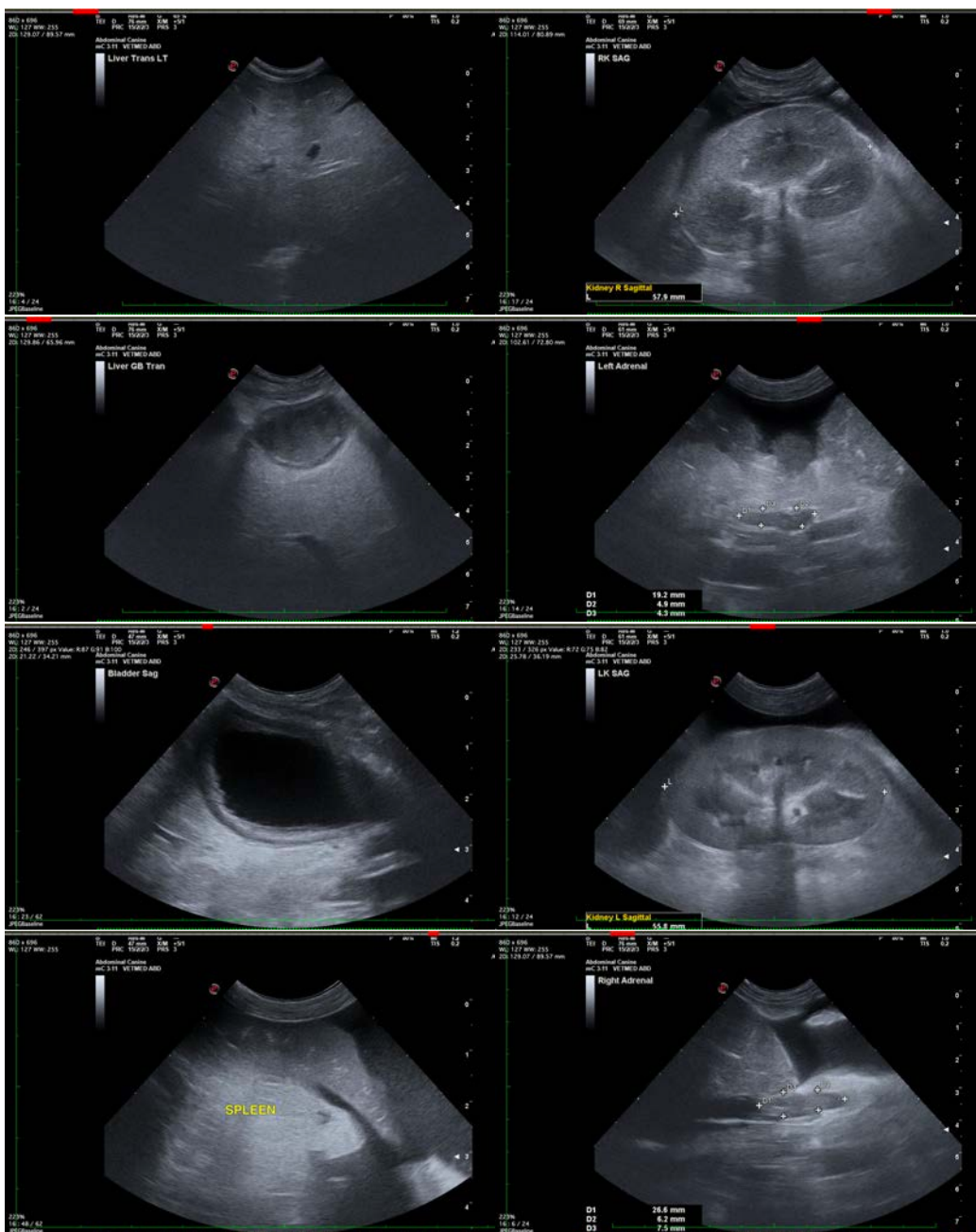
DATE

1/15/26

INTERPRETATION OF THE FINDINGS & FURTHER RECOMMENDATIONS

The changes described above are largely subtle and non-specific with very little change from previous ultrasound except for the large amount of free fluid, which given the patient's cardiac history is likely secondary to that. There is no definitive intraabdominal ultrasonographically visible explanation for the fluid. Therefore, as is reportedly pending, a cardiac evaluation is the next recommended step.

Additionally, or in the meantime, sampling of the free abdominal fluid for analysis and cytology could be considered if patient's coagulation status is appropriate.





PATIENT

Roxy Sanchez

SPECIES

Canine

BREED

Miniature Schnauzer

SEX

Spayed Female

AGE

12 Years

WEIGHT

21 lbs

INTERPRETED BY

Beth Johnson, DVM
DACVIM

IMAGING PERFORMED BY

Gabriel Ferrer, DVM

HOSPITAL NAME

Pulse: Pet Ultrasound

REFERRING VET

Dr. Andrea Montanez

INVOICE

72279

DATE

1/15/26

The information and recommendations provided are based on the images presented by the referring veterinarian/sonographer. No evaluation can be communicated regarding pathology that was not visible in the image/video clips provided.

Thank you for this referral. If the clinical or image interpretation does not parallel your findings or if I can be of any further assistance please contact me.

Beth Johnson, DVM, DACVIM
info@sonopath.com