



## PATIENT

Rosie Montellano

## SPECIES

Feline

## BREED

DLH

## SEX

Spayed Female

## AGE

16 Years

## WEIGHT

7.5 lbs

## INTERPRETED BY

Beth Johnson, DVM  
DACVIM

## IMAGING PERFORMED BY

Jessica Bailes

## HOSPITAL NAME

All Creatures Great &  
Small Veterinary Clinic

## REFERRING VET

Brownsville Animal  
Hospital

## INVOICE

72270

## DATE

1/15/26

## PRESENTING CLINICAL SIGNS

Hx of chronic recurrent UTIs; E. coli cultured 9/2025. Hx of chronic vomiting after eating. More recently lethargy, dehydration noted @ home Persistent azotemia, leukocytosis despite clavamox and enrofloxacin Rx's.

Abnormal PE/Chem/CBC/UA Results: thin BCS, moderate dehydration, otherwise NSF on PE Most recent BW 12/23: Increased SDMA ( 20), increased CREAT ( 2.8), increased BUN ( 54), Leukocytosis ( 27.6) w/ neutrophilia ( 22.4), monocytosis ( 1.06) Lateral thoracic/abdominal radiograph taken 12/26/25: increased liver size, otherwise NSF

## ULTRASONOGRAPHIC EXAMINATION OF THE ABDOMEN

### Urinary System

The urinary bladder is adequately distended with anechoic contents. No masses, inflammatory changes, echogenic sediment or cystoliths are observed. The urinary bladder, trigone and visible pelvic urethra are normal in thickness with a smooth mucosal surface.

Kidneys are bilaterally small, irregular and diffusely echogenic with decreased corticomedullary distinction and poor visualization of internal architecture. There is no pyelectasia noted. Left kidney measures 2.9 cm. Right kidney measures 3.01 cm. Punctate non-obstructive mineral densities are noted bilaterally.

### Adrenal Glands

The right adrenal gland is normal in size (0.33 cm at cranial pole and 0.25 cm at caudal pole), shape and overall architecture, echogenicity and echotexture. Visible surrounding vasculature appears normal.

The left adrenal gland is normal in size (0.31 cm at cranial pole and 0.35 cm at caudal pole), shape and overall architecture, echogenicity and echotexture. Visible surrounding vasculature appears normal.

### Spleen

The spleen is subjectively normal in size with a normal smooth capsular contour. Parenchyma is appropriately finely textured and homogenous with normal echogenicity relative to surrounding tissue (hyperechoic to liver). No focal nodules or masses are observed. Splenic vasculature appears normal.

### Liver

The liver is subjectively normal in size with normal smooth curvilinear peripheral contour. Parenchyma is appropriately hypoechoic to the spleen in echogenicity and appropriately mildly coarse and homogenous in echotexture. No focal lesions are observed. Visible vasculature and biliary tree appear normal without distension or congestion.

The gallbladder is non-distended in size. The wall is smooth without visible thickening. Luminal contents are primarily anechoic. There is no evidence of cystic or common bile duct dilation.

### Gastrointestinal

The visible stomach wall is normal in thickness and layering. The lumen of the stomach is empty with no evidence of obstruction, foreign material or infiltrative disease. Pyloric outflow tract appears patent.



## PATIENT

Rosie Montellano

## SPECIES

Feline

## BREED

DLH

## SEX

Spayed Female

## AGE

16 Years

## WEIGHT

7.5 lbs

## INTERPRETED BY

Beth Johnson, DVM  
DACVIM

## IMAGING PERFORMED BY

Jessica Bailes

## HOSPITAL NAME

All Creatures Great &  
Small Veterinary Clinic

## REFERRING VET

Brownsville Animal  
Hospital

## INVOICE

72270

## DATE

1/15/26

The visible small intestine demonstrates areas of moderately thick muscularis layer relative to mucosa (disruption of the normal 1:3 muscularis:mucosa ratio). Small intestinal submucosa is slightly irregular, thick and hyperechoic. In some images there appears to be less distinct than normal layering in some mid abdominal bowel loops. However, that finding is not confirmed in all views and may be bowel loops and luminal contents overlying each other, making picture "hazy". Distinct loss of layering is difficult to definitively say. The lumen of the small intestine is empty with no evidence of obstruction or foreign material.

The visible colon is normal in wall thickness (< 0.2 cm) and layering. Contents are consistent with normal formed feces and gas.

### **Pancreas**

The pancreas that is observed appears appropriately isoechoic to surrounding omental fat. Visible capsule is smooth and normal in contour. Visible pancreatic parenchyma is homogenous and unremarkable. There is no visible pancreatic duct dilation. There is no evidence of active peripancreatic inflammation.

### **Free Abdomen**

There is no visible free peritoneal effusion noted in these images.

Mesenteric lymph nodes are prominent in size with swollen capsular contour. Normal elongated shape (length to width ratio) is maintained. There is no loss of parenchymal detail.

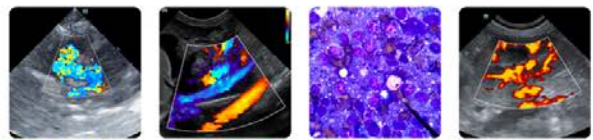
## **ULTRASONOGRAPHIC FINDINGS**

- Moderate inflammatory bowel disease (IBD) pattern – Thick muscularis has been reported with infiltrative bowel disease including both benign inflammatory disease as well as infiltrative neoplasia such as lymphoma. Early or emerging loss of layering in some loops can't be definitively ruled out, which would rank neoplasia such as lymphoma as a higher differential than a benign inflammatory process.
- Reactive mesenteric lymph nodes – infiltrative neoplastic disease cannot be ruled out but is considered less likely.
- Moderate chronic kidney disease changes bilaterally with punctate non-obstructive mineral densities noted bilaterally.

## **INTERPRETATION OF THE FINDINGS & FURTHER RECOMMENDATIONS**

If a urine culture has not been evaluated to guide antibiotic choice, a urine culture is recommended to help rule out that the lack of resolution is due to antibiotic resistance versus other. If the prescribed antibiotics are appropriate for the cultured bacteria, a longer course of antibiotics to manage a possible complicated urinary tract infection, potentially chronic low-grade smoldering pyelonephritis versus other may be warranted. In this approach, a follow up culture a week to 10 days after starting antibiotics is recommended to ensure no change in resistance pattern, secondary organisms, etc., as well as a final culture a week to 10 days after finishing antibiotics to ensure the infection has fully cleared.

Additionally, given patient's reported vomiting combined with the bowel changes noted above:



## PATIENT

Rosie Montellano

## SPECIES

Feline

## BREED

DLH

## SEX

Spayed Female

## AGE

16 Years

## WEIGHT

7.5 lbs

## INTERPRETED BY

Beth Johnson, DVM  
DACVIM

## IMAGING PERFORMED BY

Jessica Bailes

## HOSPITAL NAME

All Creatures Great & Small Veterinary Clinic

## REFERRING VET

Brownsville Animal Hospital

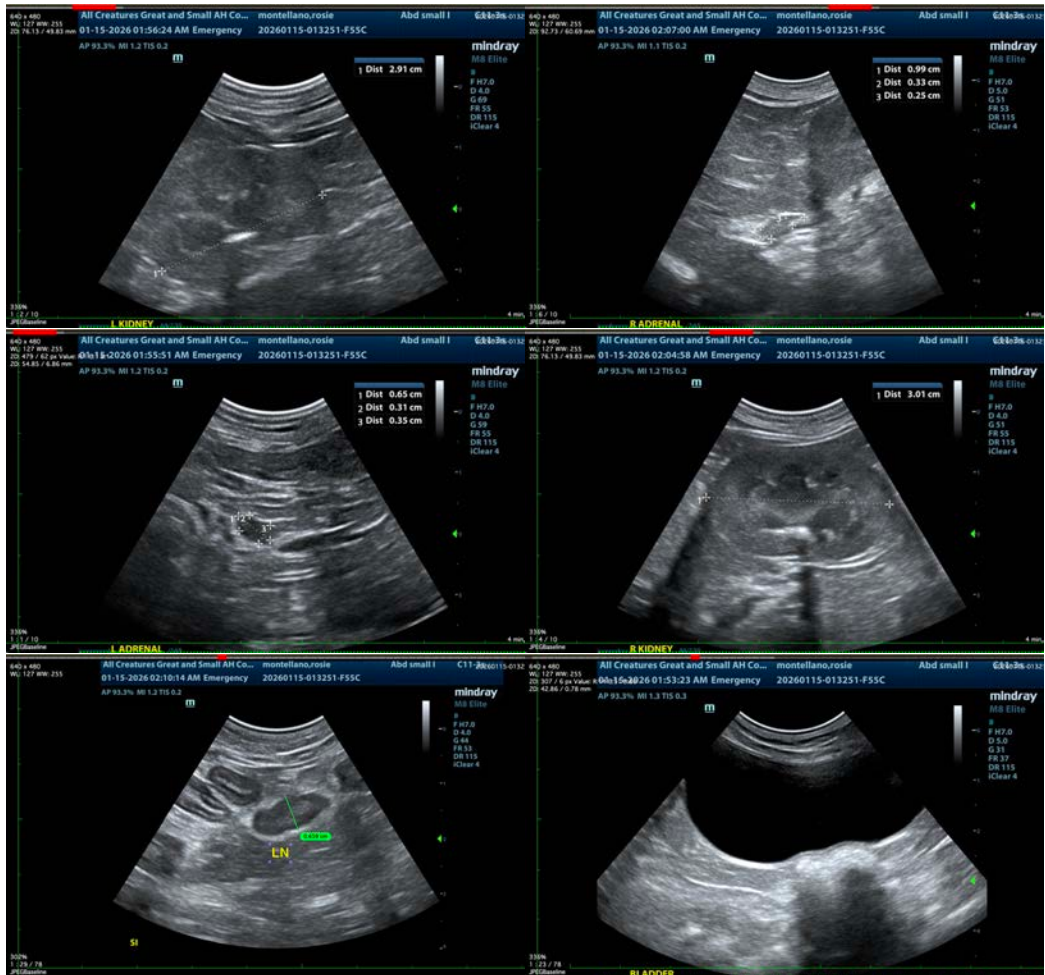## INVOICE

72270

## DATE

1/15/26

- A gastrointestinal malabsorption panel (including cobalamin, folate, TLI and PLI) to Texas A&M GI Laboratory is recommended for further evaluation of GI and pancreatic function.
- Ideally, biopsies of the GI tract, being sure to include ileum if possible, are recommended to definitively diagnose and therefore manage the infiltrative bowel disease.
- If biopsies cannot be obtained, empirical therapies could include a probiotic (if diarrhea is present, such as visbiome or proviable), empirical deworming with a 5-day course of Panacur and, if tolerated, a transition in diet, based on trial-and-error response, beginning with a hydrolyzed protein diet. Some patients respond to one brand/version of a hydrolyzed protein diet better than another brand, so several trials may be required.
- Additional considerations could include cobalamin supplementation (unless cobalamin level is evaluated and supplementation is not warranted) and prednisolone (if not contraindicated based on patient contraindications, co-morbidities, etc.).





**PATIENT**

Rosie Montellano

**SPECIES**

Feline

**BREED**

DLH

**SEX**

Spayed Female

**AGE**

16 Years

**WEIGHT**

7.5 lbs

**INTERPRETED BY**

Beth Johnson, DVM  
DACVIM

**IMAGING PERFORMED BY**

Jessica Bailes

**HOSPITAL NAME**

All Creatures Great &  
Small Veterinary Clinic

**REFERRING VET**

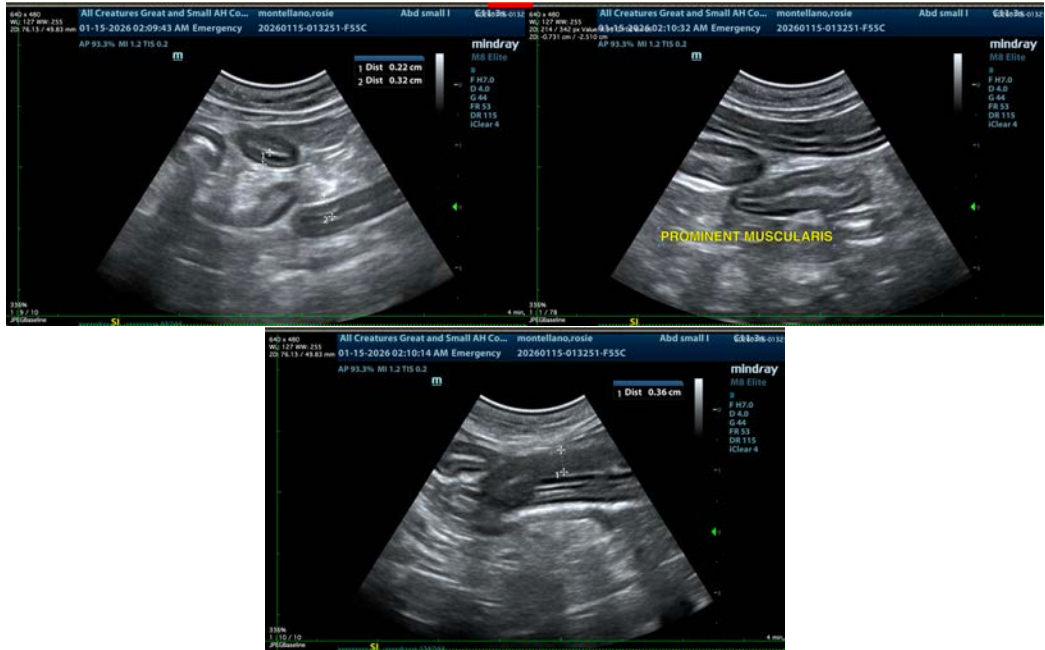
Brownsville Animal  
Hospital

**INVOICE**

72270

**DATE**

1/15/26



The information and recommendations provided are based on the images presented by the referring veterinarian/sonographer. No evaluation can be communicated regarding pathology that was not visible in the image/video clips provided.

Thank you for this referral. If the clinical or image interpretation does not parallel your findings or if I can be of any further assistance please contact me.

**Beth Johnson, DVM, DACVIM**  
info@sonopath.com