



PATIENT

Abbie Kubik

SPECIES

Canine

BREED

German Shepherd

SEX

Spayed Female

AGE

8 Years 9 Months

WEIGHT

75.9 lbs

INTERPRETED BY

Beth Johnson, DVM
DACVIM

IMAGING PERFORMED BY

Rebecca Hamilton

HOSPITAL NAME

St. Georges Veterinary
Hospital

REFERRING VET

Dr. Ng

INVOICE

72259

DATE

1/15/26

PRESENTING CLINICAL SIGNS

Hx of Lez 9/25; ALT 228, AST 69, GLob 4.1, Prior US 2/25; mild heterogeneous liver, splenomegaly, hepatic lymphadenopathy. Meds: Milk Thistle

Abnormal PE/Chem/CBC/UA Results: TP 7.7, ALT 244, AST 83, Glob 4.5. Urine: PH 8.5, 21-50 Struvites, USG 1.041

ULTRASONOGRAPHIC EXAMINATION OF THE ABDOMEN

Urinary System

The urinary bladder is adequately distended with anechoic contents. No masses, inflammatory changes, echogenic sediment or cystoliths are observed. The urinary bladder, trigone and visible pelvic urethra are normal in thickness with a smooth mucosal surface.

The right kidney is normal is size (6.74 cm), shape and echogenicity. It has smooth peripheral margination. There is a normal 1:3 cortex to medulla ratio with appropriate corticomedullary distinction. There is no evidence of pyelectasia, mineral or infarcts observed.

The left kidney is normal is size (6.6 cm), shape and echogenicity. It has smooth peripheral margination. There is a normal 1:3 cortex to medulla ratio with appropriate corticomedullary distinction. There is no evidence of pyelectasia, mineral or infarcts observed.

Adrenal Glands

The right adrenal gland is normal in size (1.0 cm at cranial pole and 0.78 cm at caudal pole), shape and overall architecture, echogenicity and echotexture. Visible surrounding vasculature appears normal.

The left adrenal gland is normal in size (0.49 cm at cranial pole and 0.57 cm at caudal pole), shape and overall architecture, echogenicity and echotexture. Visible surrounding vasculature appears normal.

Spleen

Spleen is subjectively large in size (3.5 cm thick at the hilus) with a mildly swollen but smooth capsule. Parenchyma is normal and homogenous in echogenicity and echotexture. No focal nodules or masses are observed. Splenic vasculature appears normal

Liver

Liver is subjectively enlarged with mildly irregular margins. Parenchyma is markedly heterogenous (almost "moth eaten") characterized by multiple poorly defined hypoechoic nodules within otherwise hyperechoic liver parenchyma. Visible vasculature and biliary tree appear normal without distension or congestion

The gallbladder is non-distended in size. The wall is smooth without visible thickening. Luminal contents are primarily anechoic. There is no evidence of cystic or common bile duct dilation.

Gastrointestinal

The visible stomach wall is normal in thickness and layering. The lumen of the stomach is empty with no evidence of obstruction, foreign material or infiltrative disease. Pyloric outflow tract appears patent.



PATIENT

Abbie Kubik

The visible small intestines are normal in wall thickness and layering. Small intestinal motility appears adequate (1-3 contractions per min). The lumen of the small intestine is empty with no evidence of obstruction, foreign material or infiltrative disease.

SPECIES

Canine

The visible colon is normal in wall thickness (< 0.2 cm) and layering. Contents are consistent with normal formed feces and gas.

BREED

German Shepherd

Pancreas

The pancreas that is observed appears appropriately isoechoic to surrounding omental fat. Visible capsule is smooth and normal in contour. Visible pancreatic parenchyma is homogenous and unremarkable. There is no visible pancreatic duct dilation. There is no evidence of active peripancreatic inflammation.

SEX

Spayed Female

Free Abdomen

There is no visible free peritoneal effusion noted in these images.

AGE

8 Years 9 Months

Caudal to the liver is an approximately 2.0 cm in diameter homogeneous, hypoechoic density that was previously described as a possible portal lymph node and may represent portal lymphadenopathy. However, in these images, an actual parenchymal nodule or mass can't be definitively ruled out.

WEIGHT

75.9 lbs

The visible heart base (RA) and pericardium are unremarkable without obvious pathology noted in these images at this time. If cardiac function evaluation is desired, a full echocardiogram is recommended.

INTERPRETED BY

Beth Johnson, DVM
DACVIM

ULTRASONOGRAPHIC FINDINGS

- The markedly heterogeneous, almost moth-eaten appearing liver could represent a benign process such as nodular hyperplasia, steroid or vacuolar hepatopathy, extramedullary hematopoiesis, or chronic inflammatory disease. However, the change is significantly progressed/worse in appearance compared to the study a year ago, and infiltrative neoplasia such as round cell neoplasia versus other can't be ruled out without tissue sampling.
- The previously suspected portal lymphadenopathy is relatively static to slightly progressive in size, although as described above, that change could represent one of the liver nodules versus a lymph node.
- Splenomegaly- can be associated with congestion caused by sedation (if sedated) but can also be associated with diffuse infiltrative disease. Both benign conditions such as extramedullary hematopoiesis, lymphoid hyperplasia, as well as infiltrative neoplastic diseases such as round cell neoplasia should be considered.

IMAGING PERFORMED BY

Rebecca Hamilton

HOSPITAL NAME

St. Georges Veterinary Hospital

REFERRING VET

Dr. Ng

INTERPRETATION OF THE FINDINGS & FURTHER RECOMMENDATIONS

INVOICE

72259

Three view thoracic radiographs are recommended for further assessment of cardio-pulmonary status as well as to further evaluate for any evidence of metastatic disease, if not recently evaluated.

DATE

1/15/26

Fine needle aspirates of the liver and spleen are recommended if patient's coagulation status is appropriate.

In the meantime, bile acids could be considered if patient's total bilirubin is not increased.



PATIENT

Abbie Kubik

SPECIES

Canine

BREED

German Shepherd

SEX

Spayed Female

AGE

8 Years 9 Months

WEIGHT

75.9 lbs

INTERPRETED BY

Beth Johnson, DVM
 DACVIM

IMAGING PERFORMED BY

Rebecca Hamilton

HOSPITAL NAME

St. Georges Veterinary
 Hospital

REFERRING VET

Dr. Ng

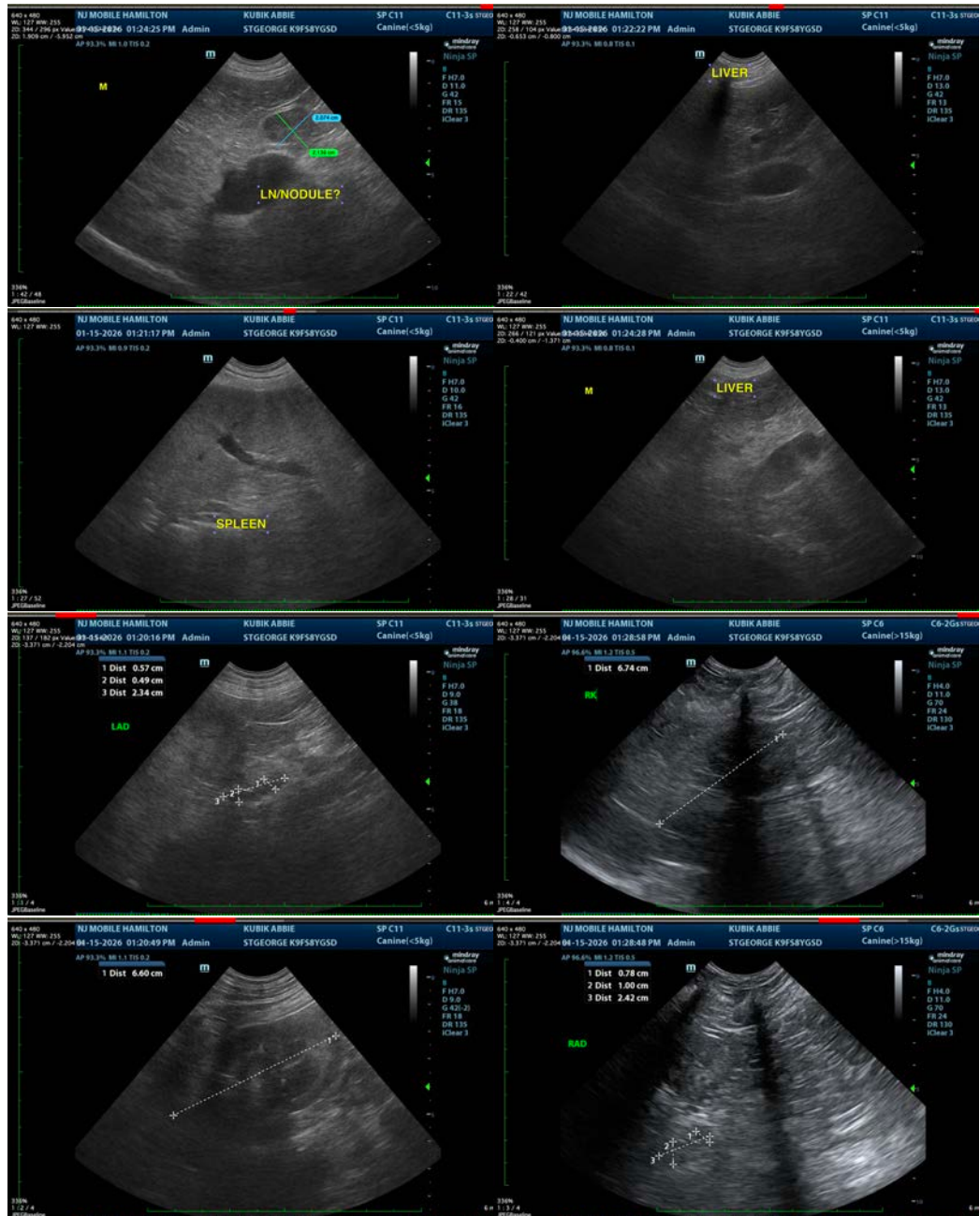
INVOICE

72259

DATE

1/15/26

Other than supportive/symptomatic medical management of clinical signs, further diagnostic and treatment recommendations are largely dependent on results of the above.





PATIENT

Abbie Kubik

SPECIES

Canine

BREED

German Shepherd

SEX

Spayed Female

AGE

8 Years 9 Months

WEIGHT

75.9 lbs

INTERPRETED BY

Beth Johnson, DVM
DACVIM

IMAGING PERFORMED BY

Rebecca Hamilton

HOSPITAL NAME

St. Georges Veterinary
Hospital

REFERRING VET

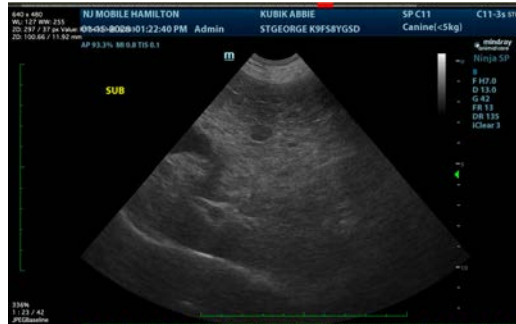Dr. Ng

INVOICE

72259

DATE

1/15/26



The information and recommendations provided are based on the images presented by the referring veterinarian/sonographer. No evaluation can be communicated regarding pathology that was not visible in the image/video clips provided.

Thank you for this referral. If the clinical or image interpretation does not parallel your findings or if I can be of any further assistance please contact me.

Beth Johnson, DVM, DACVIM
info@sonopath.com