

**PATIENT**

Luna Molinari

**PRESENTING CLINICAL SIGNS**

tremor/seizure activity noted by owner= LABS-WNL, possible mass effect in retroperitoneal space

**SPECIES**

Canine

**ULTRASONOGRAPHIC EXAMINATION OF THE ABDOMEN**

**Urinary System**

**BREED**

Heeler X

Urinary bladder is moderately distended with anechoic contents. No masses, inflammatory changes, echogenic sediment or cystoliths are observed. The urinary bladder, trigone and visible pelvic urethra are normal in thickness with a smooth mucosal surface.

**SEX**

Spayed Female

The right kidney is normal in size (5.61 cm) and shape with smooth peripheral margination. A normal 1:3 cortex to medulla ratio is maintained. The medulla and cortices are uniform in texture with some mild increased echogenicity and mild loss of corticomedullary distinction. There is no evidence of pyelectasia, mineral or infarcts observed.

**AGE**

13 Years

The left kidney is normal in size (4.57 cm) and shape with smooth peripheral margination. A normal 1:3 cortex to medulla ratio is maintained. The medulla and cortices are uniform in texture with some mild increased echogenicity and mild loss of corticomedullary distinction. Renal pelvis is dilated (pyelectasia), measuring (0.28 cm in the transverse view). No visible obstruction is observed, but cannot be ruled out. There is no evidence of mineral or infarcts observed.

**WEIGHT**

35 Pounds

**Adrenal Glands**

Right adrenal gland is mildly increased in size (0.83 cm at caudal pole), shape and contour. Corticomedullary structure is unremarkable. Visible surrounding vasculature appears normal.

**INTERPRETED BY**

Beth Johnson, DVM  
DACVIM

Left adrenal gland is mildly increased in size (0.54 cm at cranial pole and 0.91 cm at caudal pole), shape and contour. Corticomedullary structure is unremarkable. Visible surrounding vasculature appears normal.

**Spleen**

**IMAGING PERFORMED BY**

Loetitia Saint-Jacques, RVT

Spleen is subjectively normal in size with a normal smooth capsular contour. Parenchyma is appropriately finely textured and homogenous with normal echogenicity relative to surrounding tissue (hyperechoic to liver). A <1.0 cm hypo- to anechoic cyst/nodular in the head of the spleen is noted, non-capsule disrupting. A 2nd approximately 1.0 cm hypo- to anechoic nodule was noted in the tail of the spleen, non-capsule disrupting. Splenic vasculature appears normal.

**HOSPITAL NAME**

Penn Valley Vet  
Associates

**Liver**

**REFERRING VET**

Dr. Erik Muehlenhin

Liver is subjectively enlarged with rounded margins. Parenchyma is heterogenous characterized by multiple poorly defined hypoechoic nodules within otherwise hyperechoic liver parenchyma. In the left caudal liver, there is a 1.5 cm x 2.5 cm hyperechoic area with discreet thin walled cavitations throughout. Visible vasculature appears normal.

**INVOICE**

34324

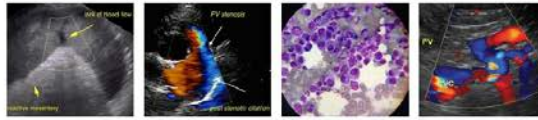
Gallbladder is non-distended in size. The wall is smooth without visible thickening. Luminal contents are primarily anechoic. There is no evidence of cystic or common bile duct dilation.

**Gastrointestinal**

**DATE**

1/15/22

The stomach wall is normal in thickness (canine < 0.5 cm and feline < 0.4 cm) and layering. The lumen of the stomach is mildly distended with echogenic non-shadowing luminal contents and gas consistent



**PATIENT**

**Luna Molinari** with normal ingesta. There is no evidence of obstruction, foreign material or infiltrative disease. Pyloric outflow tract appears patent.

**SPECIES**

Canine

The small intestine have normal intact wall layering. However, the duodenum is just above normal thickness, measuring 0.55 cm. thick. Small intestinal motility appears adequate (1-3 contractions per min). The lumen of the small intestine is empty with no evidence of obstruction, foreign material or infiltrative disease.

**BREED**

Heeler X

The visible colon is normal in wall thickness (< 0.2 cm) and layering. Contents are consistent with normal formed feces and gas.

**Pancreas**

**SEX**

Spayed Female

Pancreatic parenchyma is appropriately isoechoic to surrounding tissue. Visible capsule is smooth and normal in contour. There is no visible pancreatic duct dilation. There is no evidence of active peripancreatic inflammation. (See other)

**AGE**

13 Years

**Free Abdomen**

There is no evidence of peritoneal effusion. Sublumbar lymph nodes are visible but considered normal.

**Other**

**WEIGHT**

35 Pounds

There is a 1.5 cm x 2.0 cm heterogeneous, hypoechoic nodule just medial to the right kidney that could represent a lymph node or mild pancreas remodeling.

A 3.5 cm x 5.0 cm heterogeneous, iso- to hyperechoic mass was noted caudomedial to the spleen.

**INTERPRETED BY**

Beth Johnson, DVM  
DACVIM

**ULTRASONOGRAPHIC FINDINGS**

- Age related kidney change – This finding is expected/consistent with age-related mild degenerative disease and should be interpreted clinically in combination with laboratory changes. Differentials for very mild left renal pyelectasia include pyelonephritis, diuresis, congenital malformation or ureteral or lower urinary tract obstruction.
- Very mildly thick duodenal wall with normal layering - Rule out normal patient versus mild infiltrative inflammatory disease.
- Sublumbar nodes – Rule out normal patient variant versus very mildly reactive.
- Heterogenous liver with a focal cystic area in the left side – Differentials for hepatic changes include both benign steroid (vacuolar) hepatopathy or extramedullary hematopoiesis as well as infiltrative round cell or metastatic neoplasia. Differentials for the focal cystic area include benign hepatic cysts versus hematoma versus a cystic infiltrative neoplastic lesions, which cannot be ruled out but is considered less likely.

**IMAGING PERFORMED BY**

Loetitia Saint-Jacques, RVT

**HOSPITAL NAME**

Penn Valley Vet Associates

**REFERRING VET**

Dr. Erik Muehlenhin

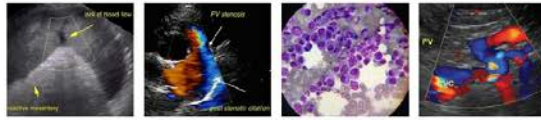
**INVOICE**

34324

**DATE**

1/15/22

- Several hypo- to anechoic splenic nodules – Differentials include both benign conditions such as extramedullary hematopoiesis, lymphoid hyperplasia, cysts, hematomas, etc., as well as infiltrative neoplastic diseases such as round cell neoplasia/sarcomas, etc.
- Heterogeneous hypoechoic nodule medial to the right kidney – Differentials include age related pancreatic remodeling versus mild resolving or chronic pancreatitis versus lymph node in that area.



**PATIENT**

Luna Molinari

- Heterogeneous iso- to hyperechoic mass medial and caudal to the spleen – Top differential includes a fatty mass such as a lipoma or liposarcoma. Other infiltrative neoplasia cannot be ruled out.

**SPECIES**

Canine

- Bilateral adrenomegaly – consistent with adrenal hyperplasia secondary to pituitary depending hyperadrenocorticism vs normal variant.

**BREED**

Heeler X

**INTERPRETATION OF THE FINDINGS & FURTHER RECOMMENDATIONS**

Recommendations include 3-view thoracic radiographs to further assess cardiopulmonary status as well as to look for evidence of infiltrative neoplastic disease if not already performed. Given the mild pyelectasia, recommendations include a urinalysis if not already evaluated with a urine culture if indicated based on urinalysis results. Given the heterogeneous liver and adrenal glands near the upper end of normal range, if there are any clinical signs of hyperadrenocorticism such as polyuria, polydipsia, polyphagia, etc., testing for hyperadrenocorticism with a low-dose Dexamethasone suppression test should be considered.

**SEX**

Spayed Female

**AGE**

13 Years

Other recommendations include a fine needle aspirate of the hyperechoic mass medial to the spleen if patient's coagulation status is appropriate. Aspirates of the splenic and liver nodules/masses are also recommended if coagulation status is appropriate. Given the mildly thick small bowel and the pancreatic remodeling, a gastrointestinal malabsorption panel including TLI, PLI, folate and cobalamin to Texas A&M GI panel is also recommended. If abnormalities are present, then recommendations include further addressing possible gastrointestinal disease with a switch to a novel or hydrolyzed protein diet +/- cobalamin supplementation, etc. based on GI panel results.

**WEIGHT**

35 Pounds

**INTERPRETED BY**

Beth Johnson, DVM  
DACVIM

**IMAGING PERFORMED BY**

Loetitia Saint-Jacques, RVT

**HOSPITAL NAME**

Penn Valley Vet  
Associates

**REFERRING VET**

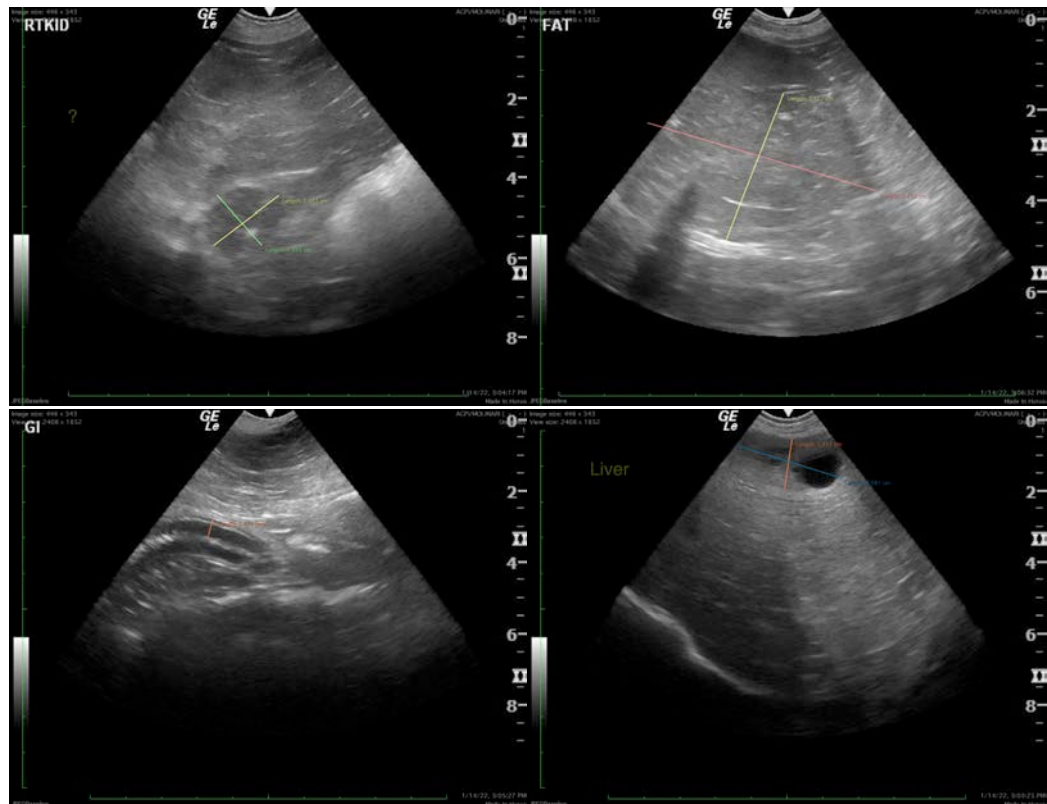
Dr. Erik Muehlenhin

**INVOICE**

34324

**DATE**

1/15/22





**PATIENT**

Luna Molinari

**SPECIES**

Canine

**BREED**

Heeler X

**SEX**

Spayed Female

**AGE**

13 Years

**WEIGHT**

35 Pounds

**INTERPRETED BY**

Beth Johnson, DVM  
DACVIM

**IMAGING PERFORMED BY**

Loetitia Saint-Jacques, RVT

**HOSPITAL NAME**

Penn Valley Vet  
Associates

**REFERRING VET**

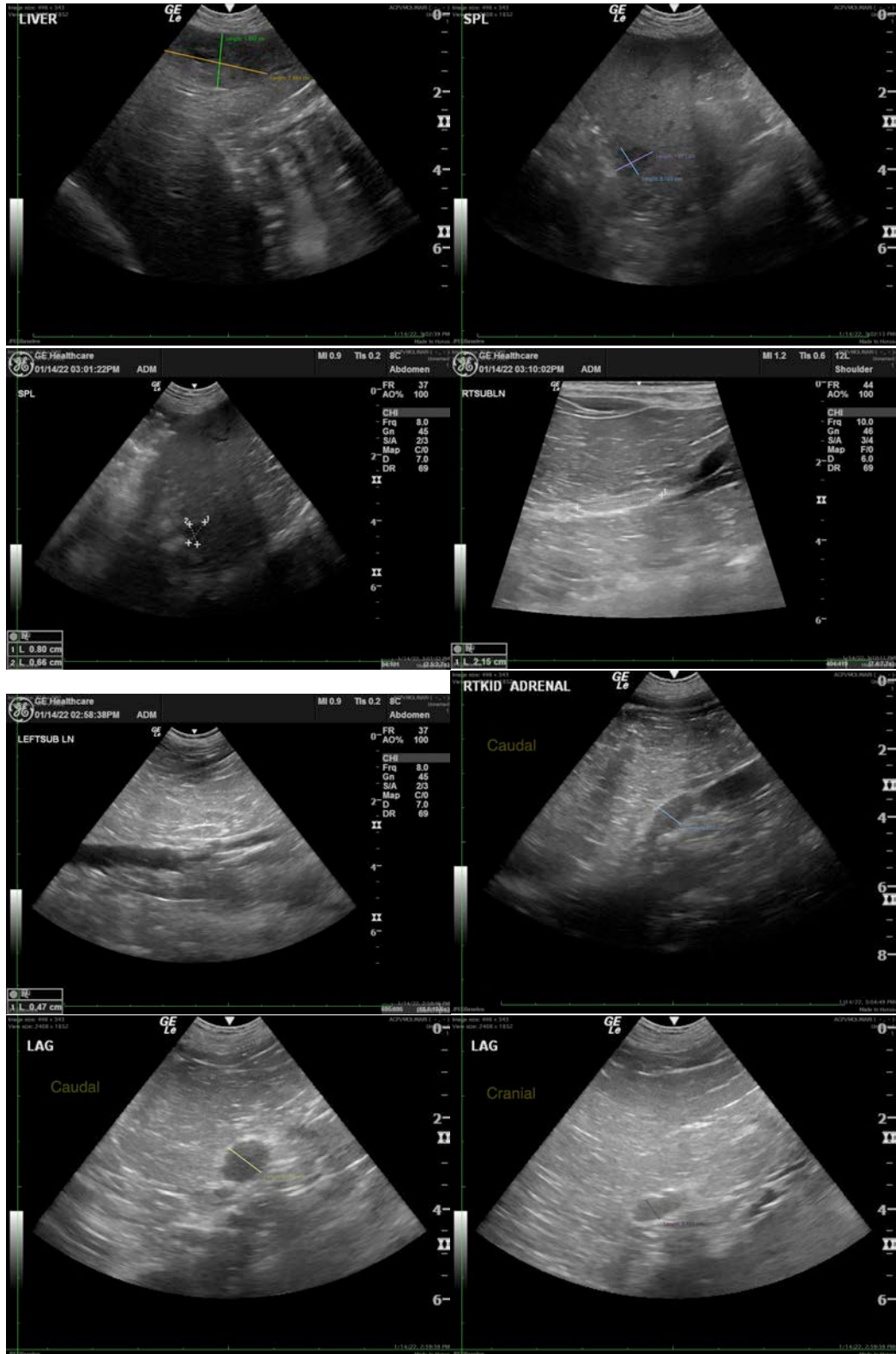Dr. Erik Muehlenhin

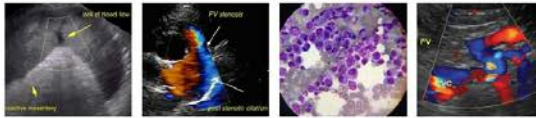
**INVOICE**

34324

**DATE**

1/15/22





**PATIENT**

Luna Molinari

**SPECIES**

Canine

**BREED**

Heeler X

**SEX**

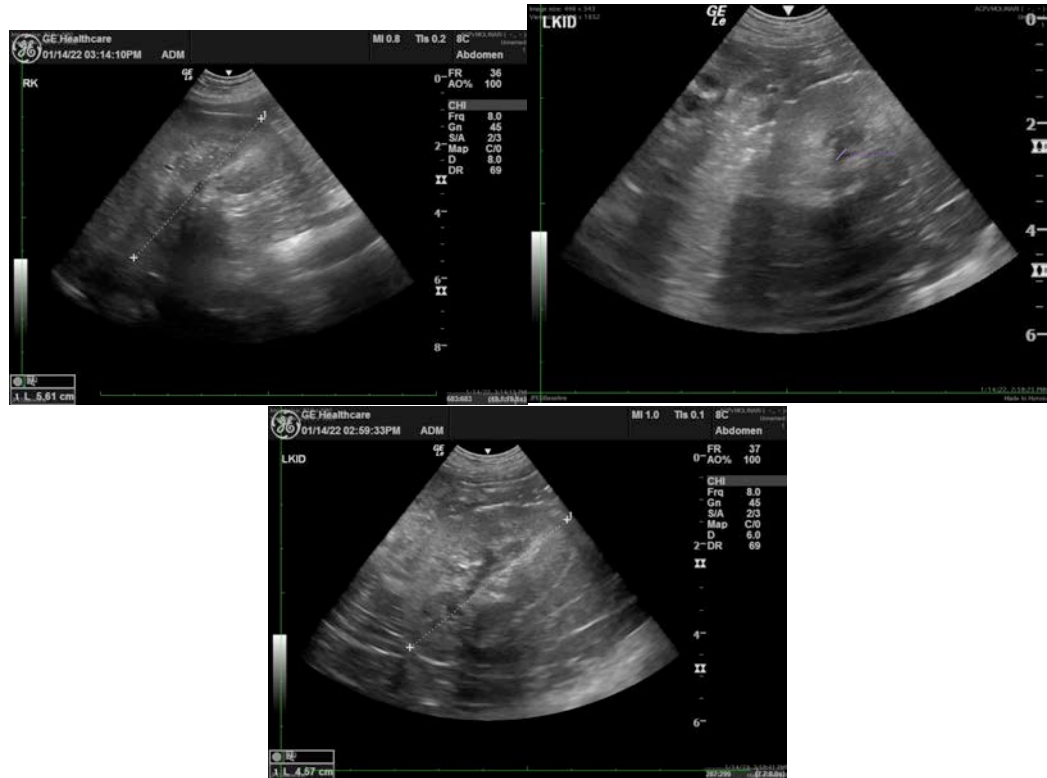
Spayed Female

**AGE**

13 Years

**WEIGHT**

35 Pounds



**INTERPRETED BY**

Beth Johnson, DVM  
DACVIM

The information and recommendations provided are based on the images presented by the referring veterinarian. No evaluation can be communicated regarding pathology that was not visible in the image/video clips provided.

**IMAGING PERFORMED BY**

Loetitia Saint-Jacques, RVT

Beth Johnson, DVM, DACVIM  
Beth.Johnson@sonopath.com

Thank you for this referral. If the clinical or image interpretation does not parallel your findings or if I can be of any further assistance please contact me.

**HOSPITAL NAME**

Penn Valley Vet  
Associates

**REFERRING VET**

Dr. Erik Muehlenhin

**INVOICE**

34324

**DATE**

1/15/22