



PATIENT

Nina Franz

SPECIES

Canine

BREED

Corgi Mix

SEX

Spayed Female

AGE

8

WEIGHT

35

INTERPRETED BY

Beth Johnson, DVM
DACVIM

IMAGING PERFORMED BY

John Sampson

HOSPITAL NAME

Richboro Veterinary
Hospital

REFERRING VET

Dr. Bethany Hughes

INVOICE

13148

DATE

01/14/26

PRESENTING CLINICAL SIGNS

vomited 1/8, no vomiting until this morning, had been eating fairly well until this morning D+ started about 2 days ago, giving metronidazole last Cerenia dose Friday last omeprazole dose yesterday morning last steroid dose yesterday - had been giving 5mg from other dog at home instead of (2) 2.5mg on the steroid seemed a little better but still panting, seems uncomfortable

Abnormal PE/Chem/CBC/UA Results: adult profile: ALP mild elevation 235 rad: possible material in stomach, unsure if foreign or food. will treat supportively and plan for AUS this week. no overt obstructive pattern PE 1/14 - showed right facial paralysis but no other neuro signs. Normal symmetrical pupils and reflexes minus menace

ULTRASONOGRAPHIC EXAMINATION OF THE ABDOMEN

Urinary System

Urinary bladder is adequately distended with anechoic contents. No masses, inflammatory changes, echogenic sediment or cystoliths are observed. The urinary bladder, trigone and visible pelvic urethra are normal in thickness with a smooth mucosal surface.

Left kidney is normal in size (4.78 cm), shape and echogenicity. It has smooth peripheral margination. There is a normal 1:3 cortex to medulla ratio with appropriate corticomedullary distinction. There is no evidence of pyelectasia, mineral or infarcts observed.

Right kidney is normal in size (5.26 cm), shape and echogenicity. It has smooth peripheral margination. There is a normal 1:3 cortex to medulla ratio with appropriate corticomedullary distinction. There is no evidence of pyelectasia, mineral or infarcts observed.

Adrenal Glands

Left adrenal gland is normal in size (0.36 cm at cranial pole and 0.53 cm at caudal pole), shape and overall architecture, echogenicity and echotexture. Visible surrounding vasculature appears normal.

Right adrenal gland is normal in size (0.39 cm at cranial pole and 0.39 cm at caudal pole), shape and overall architecture, echogenicity and echotexture. Visible surrounding vasculature appears normal.

Spleen

Spleen is subjectively normal in size with a normal smooth capsular contour. Parenchyma is appropriately finely textured and homogenous with normal echogenicity relative to surrounding tissue (hyperechoic to liver). No focal nodules or masses are observed. Splenic vasculature appears normal.

Liver

Liver is subjectively enlarged with mildly irregular margins. Parenchyma is mildly heterogenous characterized by multiple poorly defined hypoechoic nodules within otherwise hyperechoic liver parenchyma. Visible vasculature and biliary tree appear normal without distension or congestion.

Gallbladder is moderately distended with anechoic bile as well as suspended and gravity dependent echogenic debris. The wall is smooth without visible thickening. There is no evidence of cystic or CBD dilation. There is no evidence of effusion or inflammation.

Gastrointestinal



PATIENT

Nina Franz

The visible stomach wall is normal in thickness and layering. The lumen of the stomach is empty with no evidence of obstruction, foreign material or infiltrative disease. Pyloric outflow tract appears patent.

SPECIES

Canine

The visible small intestines are normal in wall thickness and layering. Small intestinal motility appears adequate (1-3 contractions per min). The lumen of the small intestine is empty with no evidence of obstruction, foreign material or infiltrative disease.

BREED

Corgi Mix

The visible colon is normal in wall thickness (< 0.2 cm) and layering. Contents are consistent with normal formed feces and gas.

Pancreas

SEX

Spayed Female

Pancreas is prominent (enlarged) in size and mildly irregular in shape with a slightly undulating contour. Parenchyma is coarse in echotexture and heterogenous to hypoechoic in echogenicity.

Free Abdomen

AGE

8

There is no visible free peritoneal effusion noted in these images.

There is no apparent pathologic lymphadenopathy noted in these images.

WEIGHT

35

ULTRASONOGRAPHIC FINDINGS

INTERPRETED BY

Beth Johnson, DVM
DACVIM

- The pancreatic changes are very mild/subtle, but chronic low-grade smoldering pancreatitis can't be ruled out as a contributing factor to patient's reported clinical signs.
- Mildly heterogenous liver- These changes are most consistent with benign processes such as nodular hyperplasia, steroid (vacuolar) hepatopathy, extramedullary hematopoiesis or possibly chronic inflammatory disease and less commonly infiltrative round cell or metastatic neoplasia
- Mild gallbladder debris- Cholecystic debris is of unknown clinical significance. It can be seen with biliary stasis from fasting or illness. Cholecystic debris is not necessarily related to hepatobiliary disease. Echogenic bile is most commonly an incidental finding in dogs and should be interpreted in combination with clinical signs such as nausea, inappetence, cranial abdominal discomfort and/or laboratory changes such as increased ALP and/or increased Tbili.

IMAGING PERFORMED BY

John Sampson

HOSPITAL NAME

Richboro Veterinary
Hospital

REFERRING VET

Dr. Bethany Hughes

INTERPRETATION OF THE FINDINGS & FURTHER RECOMMENDATIONS

- The changes described above are mild/non-specific and of unknown if any, contribution to patient's reported clinical signs. Further gastrointestinal workup recommendations to consider include a routine fecal/Giardia exam if not recently evaluated.
- A baseline cortisol is recommended. If baseline cortisol is less than 2, a full ACTH stimulation test is recommended to rule out hypoadrenocorticism.
- A gastrointestinal malabsorption panel (including cobalamin, folate, TLI and PLI) to Texas A&M GI Laboratory is recommended for further evaluation of GI and pancreatic function.
- A fecal enteropathogen PCR panel to Texas A&M GI Laboratory could be considered for further evaluation of possible infectious disease. Contact lab for recommendations on how long to discontinue antibiotics (if indicated) prior to obtaining a stool sample for submission.

INVOICE

13148

DATE

01/14/26



PATIENT

Nina Franz

SPECIES

Canine

BREED

Corgi Mix

SEX

Spayed Female

AGE

8

WEIGHT

35

INTERPRETED BY

Beth Johnson, DVM
DACVIM

IMAGING PERFORMED BY

John Sampson

HOSPITAL NAME

Richboro Veterinary
Hospital

REFERRING VET

Dr. Bethany Hughes

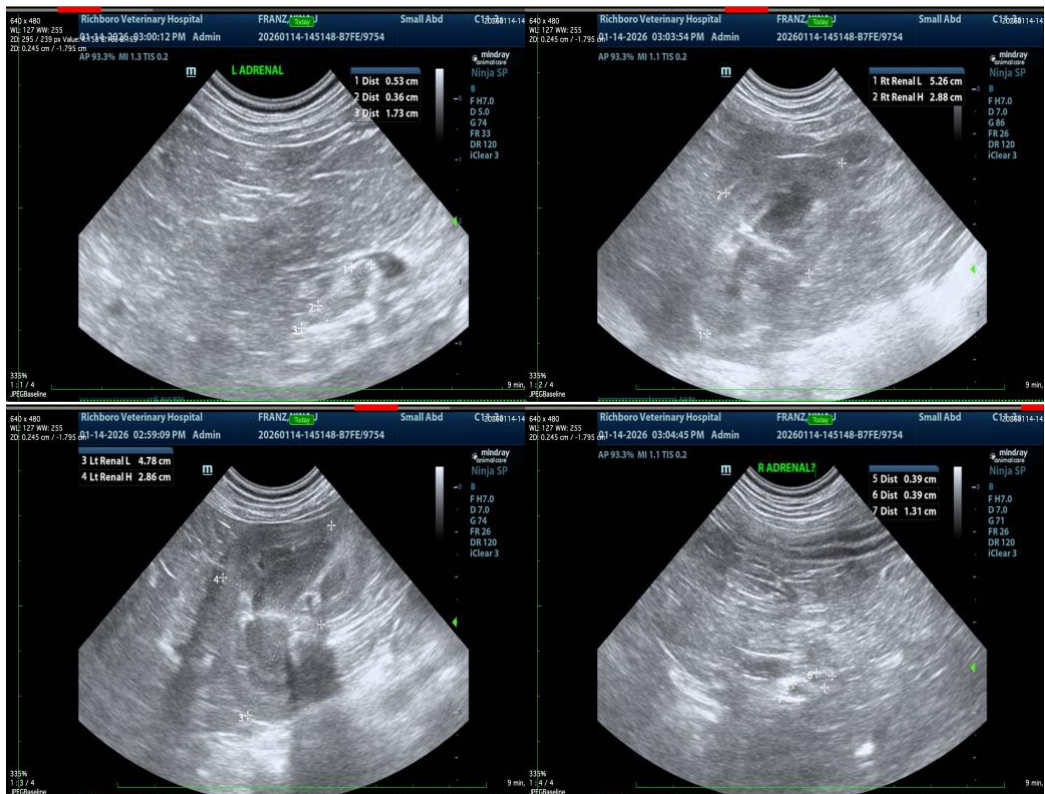
INVOICE

13148

DATE

01/14/26

- Additionally, further neurologic workup may be warranted given patient's clinical history.
- In the meantime, supportive/symptomatic medical management of clinical signs is recommended, including anti-emetics, gastroprotectants (+/- sucralfate, especially with any history of hematemesis), an appetite stimulant and fluid therapy if indicated, etc.
- Additionally, empirical deworming with a 5-day course of Panacur is recommended.
- A full course of empirical Helicobacter triple therapy could be considered.
- A probiotic, such as visbiome or proviable, may be helpful.
- Finally, if tolerated, a transition in diet could be considered, based on trial-and-error response with some options to consider including a gastrointestinal biome diet vs a hydrolyzed protein diet (sometimes several trials with different brands are necessary) vs an easy to digest, bland or low-fat diet vs other.





PATIENT

Nina Franz

SPECIES

Canine

BREED

Corgi Mix

SEX

Spayed Female

AGE

8

WEIGHT

35

INTERPRETED BY

Beth Johnson, DVM
DACVIM

IMAGING PERFORMED BY

John Sampson

HOSPITAL NAME

Richboro Veterinary
Hospital

REFERRING VET

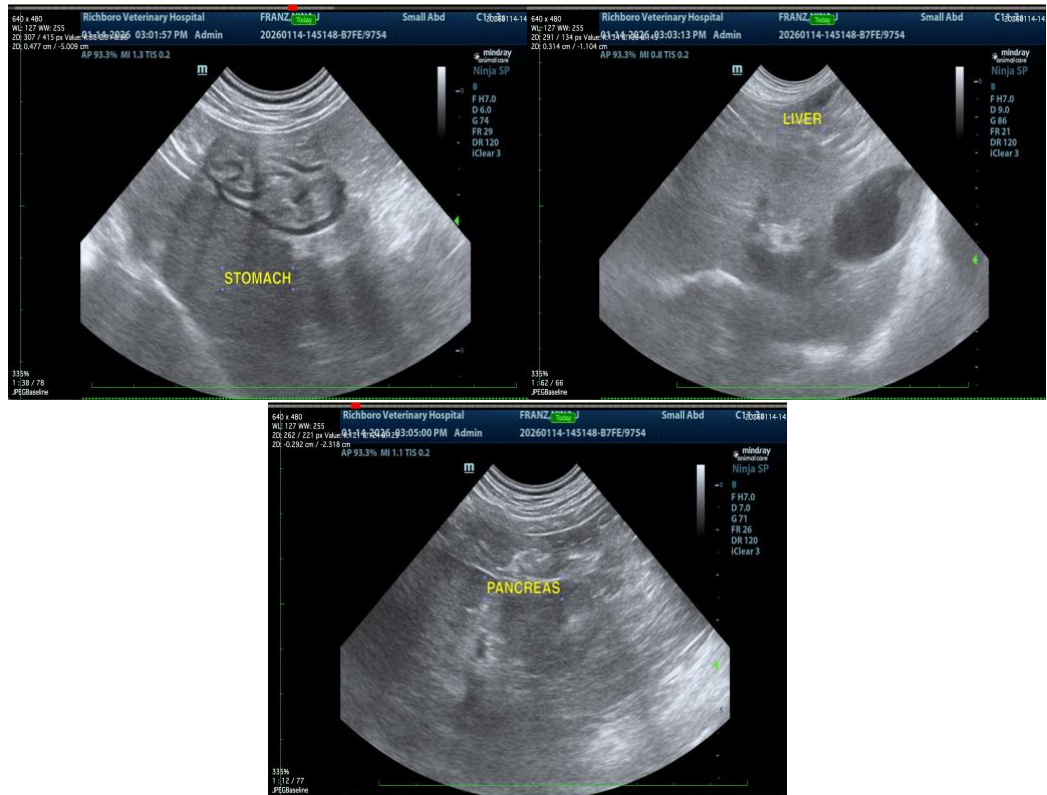
Dr. Bethany Hughes

INVOICE

13148

DATE

01/14/26



The information and recommendations provided are based on the images presented by the referring veterinarian/sonographer. No evaluation can be communicated regarding pathology that was not visible in the image/video clips provided.

Thank you for this referral. If the clinical or image interpretation does not parallel your findings or if I can be of any further assistance, please contact me.

Beth Johnson, DVM DACVIM

info@sonopath.com