



## PATIENT

Bristol Doran

## SPECIES

Canine

## BREED

Lab

## SEX

Spayed Female

## AGE

13 Years

## WEIGHT

80 lbs

## INTERPRETED BY

Beth Johnson, DVM  
DACVIM

## IMAGING PERFORMED BY

Julia Bakker, DVM

## HOSPITAL NAME

Orange Blossom  
Veterinary Imaging

## REFERRING VET

Wade Ewing, DVM

## INVOICE

72218

## DATE

1/14/26

## PRESENTING CLINICAL SIGNS

Large abdominal mass effect and fluid wave in abdomen. AUS to determine if surgery is appropriate. Pet is stable with minimal symptoms.

Abnormal PE/Chem/CBC/UA Results: Labwork from first visit for distended abdomen attached

## ULTRASONOGRAPHIC EXAMINATION OF THE ABDOMEN

### *Urinary System*

The urinary bladder is adequately distended with anechoic contents. No masses, inflammatory changes, echogenic sediment or cystoliths are observed. The urinary bladder, trigone and visible pelvic urethra are normal in thickness with a smooth mucosal surface.

The right kidney is normal in size (7.0 cm), shape and echogenicity. It has smooth peripheral margination. There is a normal 1:3 cortex to medulla ratio with appropriate corticomedullary distinction. There is no evidence of pyelectasia, mineral or infarcts observed.

The left kidney is normal in size (7.0 cm), shape and echogenicity. It has smooth peripheral margination. There is a normal 1:3 cortex to medulla ratio with appropriate corticomedullary distinction. There is no evidence of pyelectasia, mineral or infarcts observed.

### *Adrenal Glands*

The right adrenal gland is normal in size (0.86 cm at cranial pole and 0.49 cm at caudal pole), shape and overall architecture, echogenicity and echotexture. Visible surrounding vasculature appears normal.

The left adrenal gland is normal in size (0.75 cm at cranial pole and 0.77 cm at caudal pole), shape and overall architecture, echogenicity and echotexture. Visible surrounding vasculature appears normal.

### *Spleen*

The spleen that is definitively visible as spleen is subjectively normal in size with a normal smooth capsular contour. Parenchyma is appropriately finely textured and homogenous with normal echogenicity relative to surrounding tissue (hyperechoic to liver). No focal nodules or masses are observed. Splenic vasculature appears normal. \*See other.

### *Liver*

Diffusely, the liver is subjectively enlarged with mildly irregular margins. Parenchyma is moderately heterogenous characterized by multiple poorly defined hypoechoic nodules within otherwise hyperechoic liver parenchyma. Specifically, in the mid cranial liver there is an approximately 4.0 cm x 4.9 cm in size, discrete hypoechoic mass. Visible vasculature and biliary tree appear normal without distension or congestion. \*See other.

Gallbladder is moderately distended with anechoic bile as well as suspended and gravity dependent echogenic debris. The wall is smooth without visible thickening. There is no evidence of cystic or CBD dilation. There is no evidence of effusion or inflammation.



## PATIENT

Bristol Doran

## SPECIES

Canine

## BREED

Lab

## SEX

Spayed Female

## AGE

13 Years

## WEIGHT

80 lbs

## INTERPRETED BY

Beth Johnson, DVM  
DACVIM

## IMAGING PERFORMED BY

Julia Bakker, DVM

## HOSPITAL NAME

Orange Blossom  
Veterinary Imaging

## REFERRING VET

Wade Ewing, DVM

## INVOICE

72218

## DATE

1/14/26

## *Gastrointestinal*

The visible stomach wall is normal in thickness and layering. The lumen of the stomach is empty with no evidence of obstruction, foreign material or infiltrative disease. Pyloric outflow tract appears patent.

The visible small intestines are normal in wall thickness and layering. Small intestinal motility appears adequate (1-3 contractions per min). The lumen is mildly distended with echogenic non-shadowing luminal contents and gas consistent with normal ingesta/chyme. There is no evidence of obstruction, foreign material or infiltrative disease.

The visible colon is normal in wall thickness (< 0.2 cm) and layering. Contents are consistent with normal formed feces and gas.

## *Pancreas*

The pancreas that is observed appears appropriately isoechoic to surrounding omental fat. Visible capsule is smooth and normal in contour. Visible pancreatic parenchyma is homogenous and unremarkable. There is no visible pancreatic duct dilation. There is no evidence of active peripancreatic inflammation.

## *Free Abdomen*

There is no apparent pathologic lymphadenopathy noted in these images.

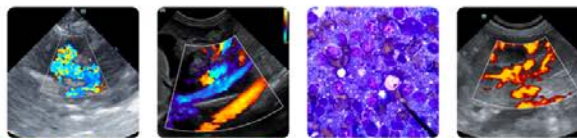
In the mid abdomen there is a huge, expansive, mixed, markedly heterogeneous, partially cystic, irregular mass measuring 15.0+ cm in size that in some views appears to definitively originate from liver, but in other views splenic origination can't be ruled out. Advanced imaging would be necessary for more clarification. Additionally, there is a very large amount of echogenic appearing fluid present in these images.

## PRIMARY FINDINGS

- The mid abdominal mass is concerning for infiltrative neoplasia such as sarcoma versus other, especially given the concurrent free fluid. Unfortunately, it is difficult to definitively determine origin of the mass. A benign process such as a hematoma, abscess, extramedullary hematopoiesis, etc. can't be ruled out but is considered less likely.
- Similar appearing nodules/masses are present definitively within the liver. This could represent a concurrent benign process such as nodular hyperplasia, extramedullary hematopoiesis, hepatoma/adenoma, other, although metastatic nodules can't be ruled out.

## SECONDARY FINDINGS

- Mild to moderate gallbladder debris - Cholecystic debris is of unknown clinical significance. It can be seen with biliary stasis from fasting or illness. Cholecystic debris is not necessarily related to hepatobiliary disease. Echogenic bile is most commonly an incidental finding in dogs and should be interpreted in combination with clinical signs such as nausea, inappetence, cranial abdominal discomfort and/or laboratory changes such as increased ALP and/or increased Tbili.



**PATIENT**

Bristol Doran

**SPECIES**

Canine

**BREED**

Lab

**SEX**

Spayed Female

**AGE**

13 Years

**WEIGHT**

80 lbs

**INTERPRETED BY**

Beth Johnson, DVM  
DACVIM

**IMAGING PERFORMED BY**

Julia Bakker, DVM

**HOSPITAL NAME**

Orange Blossom  
Veterinary Imaging

**REFERRING VET**

Wade Ewing, DVM

**INVOICE**

72218

**DATE**

1/14/26

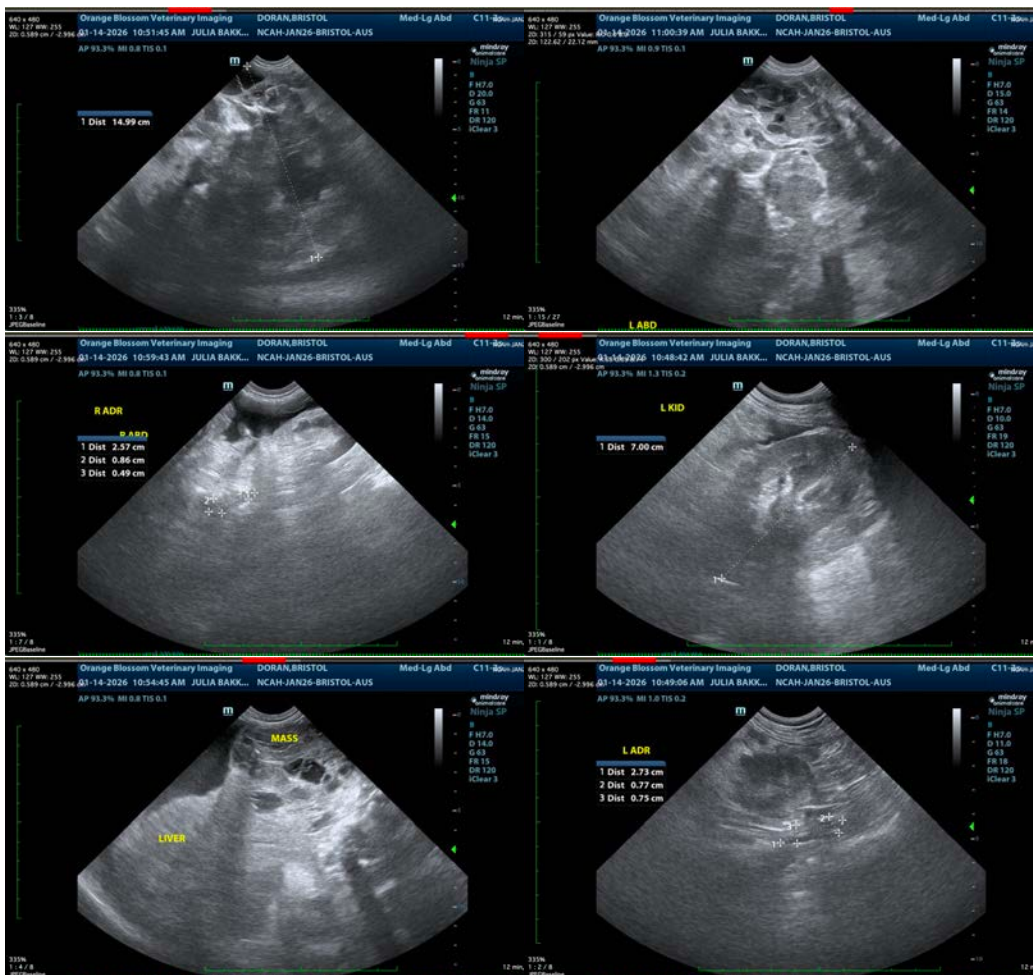
**INTERPRETATION OF THE FINDINGS & FURTHER RECOMMENDATIONS**

Three view thoracic radiographs are recommended for further assessment of cardio-pulmonary status as well as to further evaluate for any evidence of metastatic disease, if not recently evaluated.

Sampling of the free abdominal fluid as well as fine needle aspirates of the large mid abdominal mass could be considered if patient's coagulation status is appropriate. Sampling of the more definitive largest liver nodule described above could also be considered.

Alternatively, or if a cytologic diagnosis is unable to be obtained, or if surgery is warranted to stop a hemoabdomen, an exploratory laparotomy could be considered for excisional biopsy of the mass as well as removal of any other visible pathology.

Having said that, if the diffuse liver changes and the mid abdominal mass all represent the same pathology, full excision likely won't be surgically possible. If surgery is pursued, a pre-surgical planning abdominal CT scan is encouraged to help further stage and predict excision.





## PATIENT

Bristol Doran

## SPECIES

Canine

## BREED

Lab

## SEX

Spayed Female

## AGE

13 Years

## WEIGHT

80 lbs

## INTERPRETED BY

Beth Johnson, DVM  
DACVIM

## IMAGING PERFORMED BY

Julia Bakker, DVM

## HOSPITAL NAME

Orange Blossom  
Veterinary Imaging

## REFERRING VET

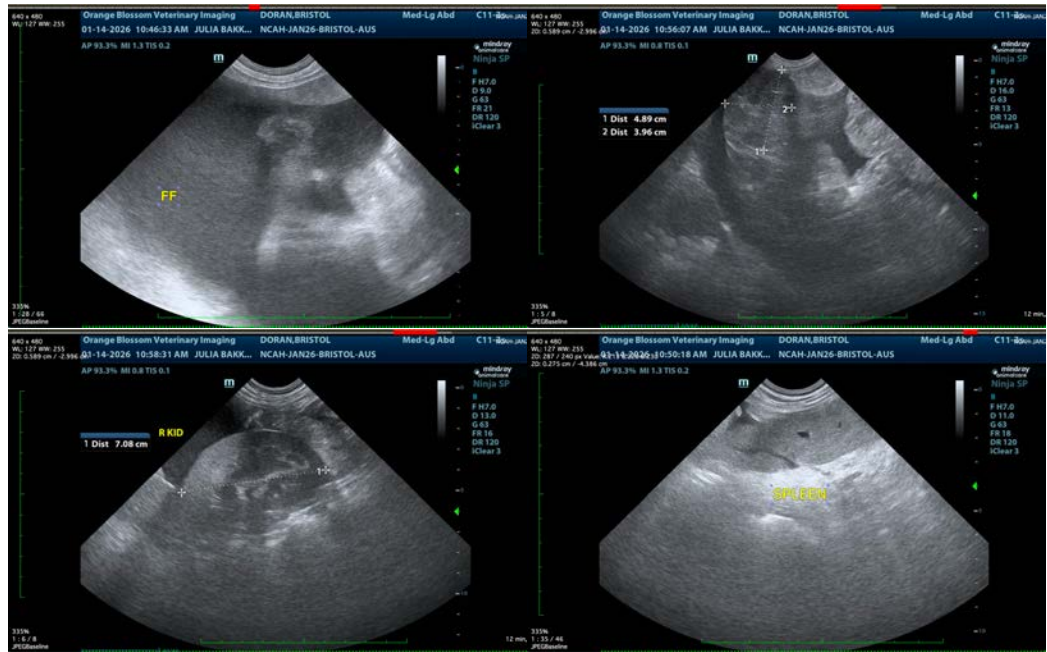
Wade Ewing, DVM

## INVOICE

72218

## DATE

1/14/26



The information and recommendations provided are based on the images presented by the referring veterinarian/sonographer. No evaluation can be communicated regarding pathology that was not visible in the image/video clips provided.

Thank you for this referral. If the clinical or image interpretation does not parallel your findings or if I can be of any further assistance please contact me.

**Beth Johnson, DVM, DACVIM**  
info@sonopath.com