



PATIENT

Rylee Moody

SPECIES

Canine

BREED

Labrador Retriever

SEX

Spayed Female

AGE

7 years

WEIGHT

59.8 lbs

INTERPRETED BY

Beth Johnson, DVM
DACVIM

IMAGING PERFORMED BY

Sara Hansen

HOSPITAL NAME

Eastgate Veterinary
Clinic

REFERRING VET

Dr. Moses

INVOICE

11089

DATE

1/13/2026

PRESENTING CLINICAL SIGNS

Clinical Exam Findings: Lethargy, wax/wane inappetance, for ~3d, mild cough, shivering (painful). No V/D Bilateral mucoid ocular discharge, intermittent febrile, mild hypersalivation ABNORMAL Labwork Values 1/13/26: ALT 518 (12-118), ALKP 279 (5-131), AST 100 (15-66); Plts 97 (170-400) -giant platelets present, few small clumps; rest of CBC/ T4, UA NSF Current Medications Denamarin since 11/25/25 - elevated ALT; Cerenia 60mg; Provable; Gabapentin 100 mg Radiographic Findings 1/12/26:Thoracic and abdominal radiographs showed normal thorax negative for intrathoracic metastasis, mild, diffuse hepatomegaly and severe bilateral elbow osteoarthritis.

ULTRASONOGRAPHIC EXAMINATION OF THE ABDOMEN

Urinary System

The urinary bladder is adequately distended with anechoic contents. No masses, inflammatory changes, echogenic sediment or cystoliths are observed. The urinary bladder, trigone and visible pelvic urethra are normal in thickness with a smooth mucosal surface.

Kidneys are overall normal in size and shape with smooth peripheral margination. A normal 1:3 cortex to medulla ratio is maintained. The medulla and cortices are uniform in texture with some mild increased cortical echogenicity and mild loss of corticomedullary distinction, expected in this age patient. There is no evidence of pyelectasia, mineral or infarcts observed. Left kidney measures 6.23 cm, and the right kidney measures 6.75 cm.

Adrenal Glands

The right adrenal gland is normal in size (1.5 cm at cranial pole and 0.65 cm at caudal pole), shape and overall architecture, echogenicity and echotexture. Visible surrounding vasculature appears normal.

The left adrenal gland is mildly plump at the caudal pole (0.67 cm at the cranial pole and 0.95 cm at the caudal pole.) Normal shape and contour are maintained without evidence of capsular invasion. Corticomedullary structure is unremarkable. Visible surrounding vasculature appears normal.

Spleen

The spleen is subjectively normal in size (1.9 cm thick at the hilus) with a normal smooth capsular contour. Parenchyma is appropriately finely textured and homogenous with normal echogenicity relative to surrounding tissue (hyperechoic to liver). No focal nodules or masses are observed. Splenic vasculature appears normal.

Liver

Liver is subjectively enlarged with mildly irregular margins. Parenchyma is mildly heterogenous characterized by multiple poorly defined hypoechoic nodules within otherwise hyperechoic liver parenchyma. Visible vasculature and biliary tree appear normal without distension or congestion.

The gallbladder is non-distended in size. The wall is smooth without visible thickening. Luminal contents are primarily anechoic. There is no evidence of cystic or common bile duct dilation.

Gastrointestinal



PATIENT

Rylee Moody

The visible stomach wall is normal in thickness and layering. The lumen of the stomach is empty with no evidence of obstruction, foreign material or infiltrative disease. Pyloric outflow tract appears patent.

SPECIES

Canine

The visible small intestines are normal in wall thickness and layering. Small intestinal motility appears adequate (1-3 contractions per min). The lumen of the small intestine is empty with no evidence of obstruction, foreign material or infiltrative disease.

BREED

Labrador Retriever

The visible colon is normal in wall thickness (< 0.2 cm) and layering. Contents are consistent with normal formed feces and gas.

Pancreas

SEX

Spayed Female

The pancreas that is observed appears appropriately isoechoic to surrounding omental fat. Visible capsule is smooth and normal in contour. Visible pancreatic parenchyma is homogenous and unremarkable. There is no visible pancreatic duct dilation. There is no evidence of active peripancreatic inflammation.

AGE

7 years

Free Abdomen

WEIGHT

59.8 lbs

There is no visible free peritoneal effusion noted in these images.

There is no apparent pathologic lymphadenopathy noted in these images.

PRIMARY FINDINGS

- An obvious cause for the subtle liver changes is not identified in these images. Microscopic disease such as Leptospirosis, bacterial cholangiohepatitis, chronic active hepatitis, copper-associated hepatotoxicity, other hepatotoxicity, other reactive hepatopathy, infiltrative neoplasia (considered unlikely), etc. cannot be definitively ruled out.

INTERPRETED BY

Beth Johnson, DVM
DACVIM

SECONDARY FINDINGS

- A very mild left adrenomegaly is likely normal patient variant versus underlying adrenal disease. Having said that, adrenal disease, adenoma, hyperplasia, much less likely infiltrative neoplasia, can't be ruled out but is likely not contributing to patient's reported clinical signs.
- Mild age-related kidney changes.

IMAGING PERFORMED BY

Sara Hansen

INTERPRETATION OF THE FINDINGS & FURTHER RECOMMENDATIONS

Differentials for a primary hepatocellular injury liver enzyme pattern (increased ALT) depend partially on the level of increase. Mild increases (less than 2 times normal) are often a "reactive hepatopathy" or the liver's response to an insult elsewhere in the body including, but not limited to, pancreatitis, gastroenteritis, parasitic disease, dental disease, vacuolar or endocrine hepatopathy from diabetes mellitus or hyperadrenocorticism (steroid-induced), hypoadrenocorticism, certain drugs (e.g. phenobarbital, corticosteroids, azathioprine, etc.), and muscle ALT (more likely if AST and CK concurrently increased).

HOSPITAL NAME

Eastgate Veterinary
Clinic

REFERRING VET

Dr. Moses

INVOICE

11089

DATE

1/13/2026

It is a good indicator of active liver damage (cell membrane disruption, cellular necrosis), however, if the value is increased by at least 3-4 times normal. Differentials include infectious disease, including Leptospirosis, inflammatory disease (ie. active hepatitis, copper, other), toxic insult as well as infiltrative neoplasia.



PATIENT

Rylee Moody

SPECIES

Canine

BREED

Labrador Retriever

SEX

Spayed Female

AGE

7 years

WEIGHT

59.8 lbs

INTERPRETED BY

Beth Johnson, DVM
 DACVIM

IMAGING PERFORMED BY

Sara Hansen

HOSPITAL NAME

Eastgate Veterinary
 Clinic

REFERRING VET

Dr. Moses

INVOICE

11089

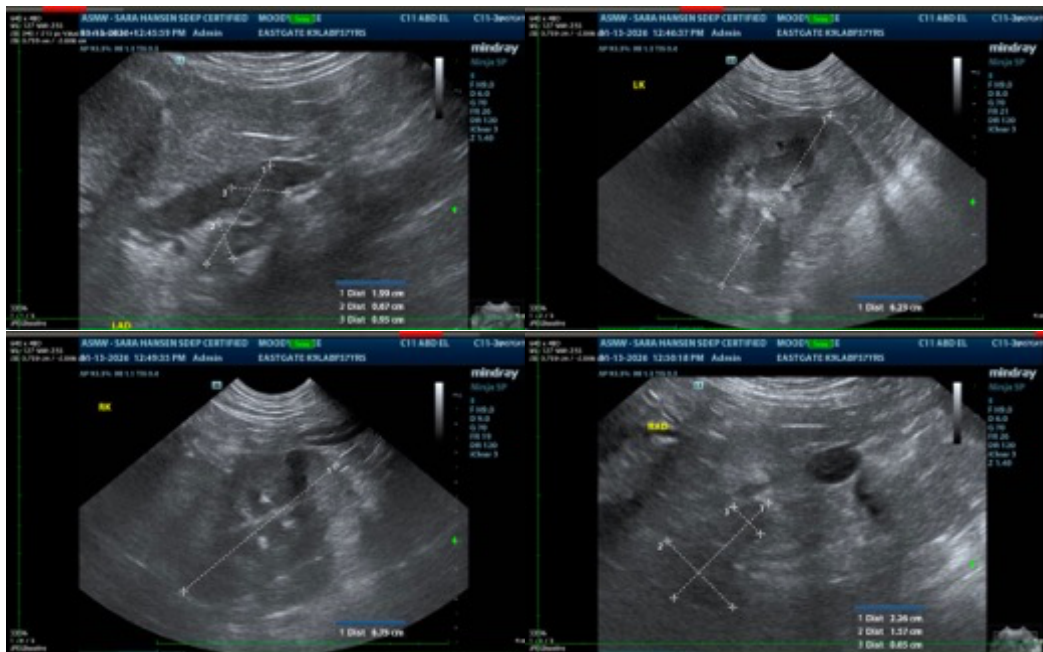
DATE

1/13/2026

ALT levels vary in cases of vascular anomalies such as microvascular dysplasia and portosystemic shunts (PSS), but are often less significantly increased.

- Testing for Leptospirosis could be considered.
- Bile acids could be considered, if tbili is not increased.
- An empirical course of antibiotics and empirical hepatic nutraceuticals may be tried, with monitoring of ALT for improvement. If improvement is noted, antibiotics should be continued until liver enzymes either normalize or plateau (recheck every 2-3 weeks); however, if improvement is not noted and/or enzyme increase progresses, antibiotics should not be continued long term and liver tissue sampling is recommended.
- FNA of the liver can be performed to assess inflammatory cell type, rule in/out round cell neoplasia, etc. (if patient's coagulation status is appropriate).
- If round cell neoplasia is not diagnosed, a liver biopsy (including copper level assessment) may be required to definitively diagnose the underlying hepatopathy.

If a primary hepatopathy is not the cause of patient's reported intermittent clinical signs, extra abdominal disease may warrant further investigation. Having said that, despite a largely unremarkable gastrointestinal tract, neither microscopic gastrointestinal disease or early emerging pancreatitis can be definitively ruled out, and could potentially be a differential based on clinical history. Therefore, a gastrointestinal malabsorption panel (including cobalamin, folate, TLI and PLI) to Texas A&M GI Laboratory is recommended for further evaluation of GI and pancreatic function.





PATIENT

Rylee Moody

SPECIES

Canine

BREED

Labrador Retriever

SEX

Spayed Female

AGE

7 years

WEIGHT

59.8 lbs

INTERPRETED BY

Beth Johnson, DVM
 DACVIM

IMAGING PERFORMED BY

Sara Hansen

HOSPITAL NAME

Eastgate Veterinary
 Clinic

REFERRING VET

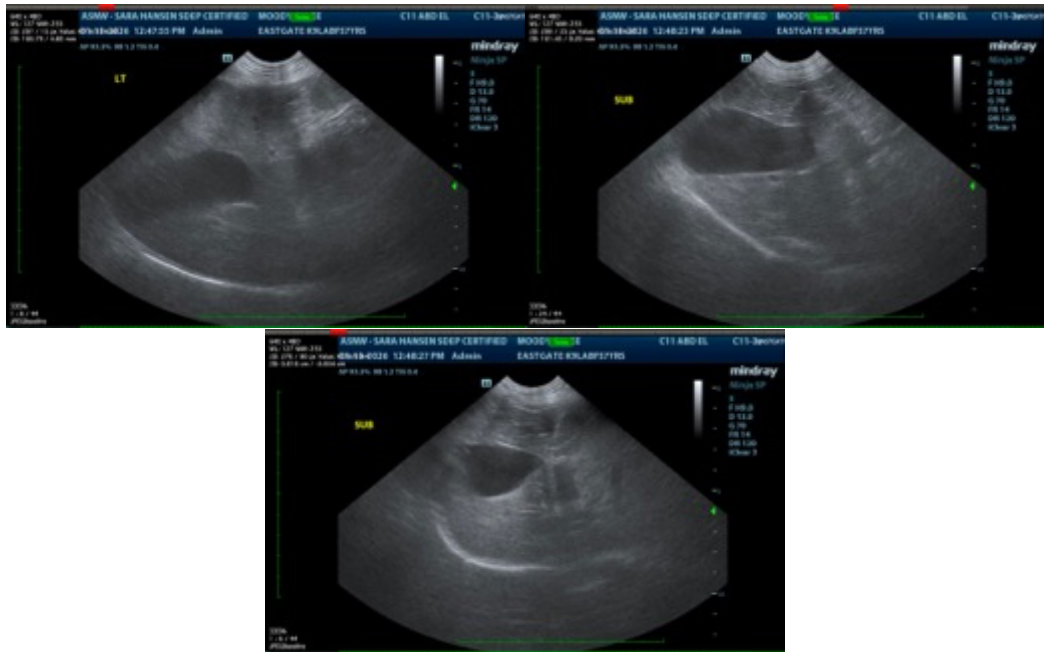
Dr. Moses

INVOICE

11089

DATE

1/13/2026



The information and recommendations provided are based on the images presented by the referring veterinarian/sonographer. No evaluation can be communicated regarding pathology that was not visible in the image/video clips provided.

Thank you for this referral. If the clinical or image interpretation does not parallel your findings or if I can be of any further assistance please contact me.

Beth Johnson, DVM, DACVIM
 info@sonopath.com