



PATIENT

Hermes Girardin

SPECIES

Feline

BREED

Ragdoll

SEX

Neutered Male

AGE

7 Months

WEIGHT

10.8 lbs

INTERPRETED BY

Beth Johnson, DVM
 DACVIM

IMAGING PERFORMED BY

Kelly Reschny

HOSPITAL NAME

Dog & Cat Clinic of
 Niagara

REFERRING VET

Dr. Snieder

INVOICE

72168

DATE

1/13/26

PRESENTING CLINICAL SIGNS

Presented for repeat Urinalysis as per prev vet recommended - recurrent urinary issues Current Medications Onsior 6mg Tablets

Abnormal PE/Chem/CBC/UA Results: Mild elevation of WBCs and cocci shaped bacteria seen. Elevation of RBC

ULTRASONOGRAPHIC EXAMINATION OF THE ABDOMEN

Urinary System

The urinary bladder is adequately distended with anechoic contents. No masses, inflammatory changes, echogenic sediment or cystoliths are observed. The urinary bladder, trigone and visible pelvic urethra are normal in thickness with a smooth mucosal surface.

The right kidney is normal is size (4.03 cm), shape and echogenicity. It has smooth peripheral margination. There is a normal 1:3 cortex to medulla ratio with appropriate corticomedullary distinction. There is no evidence of pyelectasia, mineral or infarcts observed. A hyperechoic band parallel to the corticomedullary border is present.

The left kidney is normal is size (4.03 cm), shape and echogenicity. It has smooth peripheral margination. There is a normal 1:3 cortex to medulla ratio with appropriate corticomedullary distinction. There is no evidence of pyelectasia, mineral or infarcts observed. A hyperechoic band parallel to the corticomedullary border is present.

Adrenal Glands

The right adrenal gland is normal in size (0.35 cm), shape and overall architecture, echogenicity and echotexture. Visible surrounding vasculature appears normal.

The left adrenal gland is normal in size (0.44 cm), shape and overall architecture, echogenicity and echotexture. Visible surrounding vasculature appears normal.

Spleen

The spleen is subjectively normal in size with a normal smooth capsular contour. Parenchyma is appropriately finely textured and homogenous with normal echogenicity relative to surrounding tissue (hyperechoic to liver). No focal nodules or masses are observed. Splenic vasculature appears normal.

Liver

The liver is subjectively normal in size with normal smooth curvilinear peripheral contour. Parenchyma is appropriately hypoechoic to the spleen in echogenicity and appropriately mildly coarse and homogenous in echotexture. No focal lesions are observed. Visible vasculature and biliary tree appear normal without distension or congestion.

The gallbladder is non-distended in size. The wall is smooth without visible thickening. Luminal contents are primarily anechoic. There is no evidence of cystic or common bile duct dilation.

Gastrointestinal

The visible stomach wall is normal in thickness and layering. The lumen of the stomach is empty with no evidence of obstruction, foreign material or infiltrative disease. Pyloric outflow tract appears patent.



PATIENT	The visible small intestines are normal in wall thickness and layering. Small intestinal motility appears adequate (1-3 contractions per min). The lumen of the small intestine is empty with no evidence of obstruction, foreign material or infiltrative disease.
Hermes Girardin	
SPECIES	The visible colon is normal in wall thickness (< 0.2 cm) and layering. Contents are consistent with normal formed feces and gas.
Feline	
BREED	<i>Pancreas</i>
Ragdoll	The pancreas that is observed appears appropriately isoechoic to surrounding omental fat. Visible capsule is smooth and normal in contour. Visible pancreatic parenchyma is homogenous and unremarkable. There is no visible pancreatic duct dilation. There is no evidence of active peripancreatic inflammation.
SEX	<i>Free Abdomen</i>
Neutered Male	There is no visible free peritoneal effusion noted in these images.
AGE	There is no apparent pathologic lymphadenopathy noted in these images.
7 Months	
WEIGHT	ULTRASONOGRAPHIC FINDINGS
10.8 lbs	<ul style="list-style-type: none">• Significant bilateral medullary rim sign - This finding is of unknown clinical significance and can be a normal variant, often idiopathic. Medullary rim sign can be present with renal disease including FIP, lymphoma, hypercalcemic nephropathy, tubular disease, other and should be interpreted in combination with other more specific indications of kidney disease such as isosthenuria, proteinuria, azotemia, etc. This is a common incidental finding in patients with diabetes mellitus.
INTERPRETED BY	<u>INTERPRETATION OF THE FINDINGS & FURTHER RECOMMENDATIONS</u>
Beth Johnson, DVM DACVIM	If not already evaluated, a urine culture could be considered.
IMAGING PERFORMED BY	Additionally, if not recently evaluated, a full general metabolic health screen is recommended to also include CBC/Chem panel and electrolytes.
Kelly Reschny	Pending results of above, in the face of negative urine culture(s) and no cystoliths, masses, etc., these urinary signs could be, at least in part, consistent with sterile cystitis or feline lower urinary tract disease (FLUTD).
HOSPITAL NAME	Recommendations include maximizing water consumption (water fountains, canned food, etc) as well as reducing stress (recommendations can be found at Indoor Cat Initiative out of The Ohio State University CVM). Transition to a urinary health diet such as Royal Canin Urinary SO (or similar) could also be considered.
Dog & Cat Clinic of Niagara	
REFERRING VET	
Dr. Snieder	
INVOICE	
72168	
DATE	
1/13/26	



PATIENT

Hermes Girardin

SPECIES

Feline

BREED

Ragdoll

SEX

Neutered Male

AGE

7 Months

WEIGHT

10.8 lbs

INTERPRETED BY

Beth Johnson, DVM
 DACVIM

IMAGING PERFORMED BY

Kelly Reschny

HOSPITAL NAME

Dog & Cat Clinic of
 Niagara

REFERRING VET

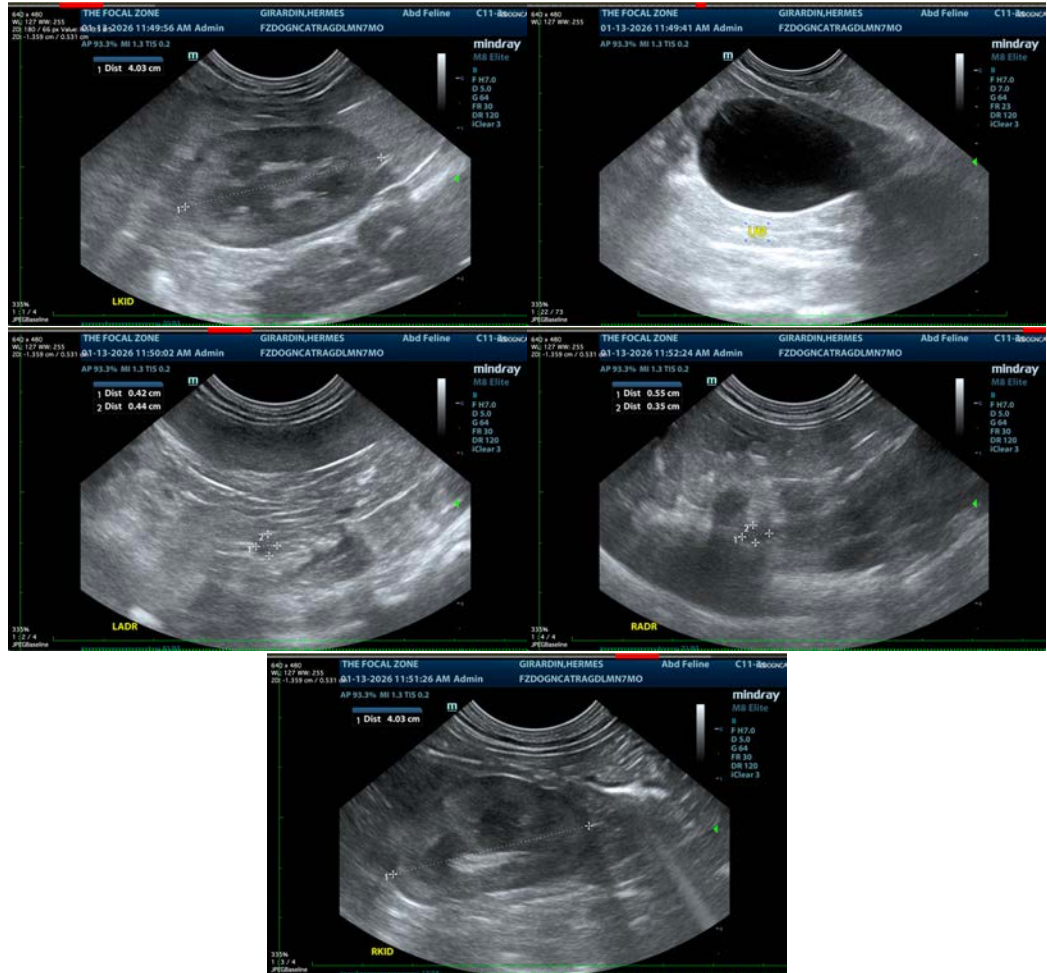
Dr. Snieder

INVOICE

72168

DATE

1/13/26



The information and recommendations provided are based on the images presented by the referring veterinarian/sonographer. No evaluation can be communicated regarding pathology that was not visible in the image/video clips provided.

Thank you for this referral. If the clinical or image interpretation does not parallel your findings or if I can be of any further assistance please contact me.

Beth Johnson, DVM, DACVIM
 info@sonopath.com