



PATIENT	PRESENTING CLINICAL SIGNS
Gidget Ritchie	Losing weight Abnormal PE/Chem/CBC/UA Results: gall bladder stones seen on xrays.
SPECIES	ULTRASONOGRAPHIC EXAMINATION OF THE ABDOMEN
Canine	<i>Urinary System</i>
BREED	The urinary bladder is adequately distended with anechoic contents. No masses, inflammatory changes, echogenic sediment or cystoliths are observed. The urinary bladder, trigone and visible pelvic urethra are normal in thickness with a smooth mucosal surface.
Yorkie	
SEX	The right kidney is normal is size (2.6 cm), shape and echogenicity. It has smooth peripheral margination. There is a normal 1:3 cortex to medulla ratio with appropriate corticomedullary distinction. There is no evidence of pyelectasia, mineral or infarcts observed.
Spayed Female	
AGE	The left kidney is normal is size (2.6 cm), shape and echogenicity. It has smooth peripheral margination. There is a normal 1:3 cortex to medulla ratio with appropriate corticomedullary distinction. There is no evidence of pyelectasia, mineral or infarcts observed.
6 Years	
WEIGHT	<i>Adrenal Glands</i>
4.5 lbs	The right adrenal gland is normal in size (0.79 cm at cranial pole and 0.44 cm at caudal pole), shape and overall architecture, echogenicity and echotexture. Visible surrounding vasculature appears normal.
INTERPRETED BY	The left adrenal gland is normal in size (0.46 cm at cranial pole and 0.36 cm at caudal pole), shape and overall architecture, echogenicity and echotexture. Visible surrounding vasculature appears normal.
Beth Johnson, DVM DACVIM	<i>Spleen</i>
IMAGING PERFORMED BY	The spleen is subjectively normal in size with a normal smooth capsular contour. Parenchyma is appropriately finely textured and homogenous with normal echogenicity relative to surrounding tissue (hyperechoic to liver). No focal nodules or masses are observed. Splenic vasculature appears normal.
Kelly Reschny	<i>Liver</i>
HOSPITAL NAME	The liver is subjectively normal in size with normal smooth curvilinear peripheral contour. Parenchyma is appropriately hypoechoic to the spleen in echogenicity and appropriately mildly coarse and homogenous in echotexture. No focal lesions are observed. Visible vasculature and biliary tree appear normal without distension or congestion.
Dog & Cat Clinic of Niagara	
REFERRING VET	Gallbladder is moderately distended with anechoic bile as well as suspended and gravity dependent echogenic debris. Specifically, there is an approximately 1.5 cm x 0.90 cm echogenic, non-shadowing, non-obstructive density noted within the gallbladder that could represent a pile of mineral/sand debris, but no distinct cystoliths are noted in these images at this time. The wall is smooth without visible thickening. There is no evidence of cystic or CBD dilation. There is no evidence of effusion or inflammation.
Dr. Habib	
INVOICE	<i>Gastrointestinal</i>
72161	The visible stomach wall is normal in thickness and layering. The lumen is mildly distended with primarily fluid as well as some echogenic non-shadowing luminal contents and gas consistent with
DATE	
1/13/26	



PATIENT

Gidget Ritchie

normal chyme. There is no evidence of obstruction, foreign material, or infiltrative disease. Pyloric outflow tract appears patent.

SPECIES

Canine

The visible small intestines are normal in wall thickness and layering. Small intestinal motility appears adequate (1-3 contractions per min). The lumen of the small intestine is empty with no evidence of obstruction, foreign material or infiltrative disease.

BREED

Yorkie

The visible colon is normal in wall thickness (< 0.2 cm) and layering. Contents are consistent with normal formed feces and gas.

SEX

Spayed Female

Pancreas

The pancreas that is observed appears appropriately isoechoic to surrounding omental fat. Visible capsule is smooth and normal in contour. Visible pancreatic parenchyma is homogenous and unremarkable. There is no visible pancreatic duct dilation. There is no evidence of active peripancreatic inflammation.

AGE

6 Years

Free Abdomen

There is no visible free peritoneal effusion noted in these images.

WEIGHT

4.5 lbs

There is no apparent pathologic lymphadenopathy noted in these images.

ULTRASONOGRAPHIC FINDINGS

INTERPRETED BY

Beth Johnson, DVM
 DACVIM

- Moderate gallbladder debris - Cholecystic debris is of unknown clinical significance. It can be seen with biliary stasis from fasting or illness. Cholecystic debris is not necessarily related to hepatobiliary disease. Echogenic bile is most commonly an incidental finding in dogs and should be interpreted in combination with clinical signs such as nausea, inappetence, cranial abdominal discomfort and/or laboratory changes such as increased ALP and/or increased Tbili. **Some mineral/sand debris can't be ruled out, but no definitive cystoliths are noted in these images at this time. The density could represent a non-shadowing cystolith, but there is no evidence of obstruction noted.*

IMAGING PERFORMED BY

Kelly Reschny

INTERPRETATION OF THE FINDINGS & FURTHER RECOMMENDATIONS

HOSPITAL NAME

Dog & Cat Clinic of
 Niagara

Further recommendations regarding patient's weight loss depend in large part on appetite. If appetite is normal or even increased, then in addition to a routine, full general metabolic health screen, further evaluation of absorption and digestion is recommended. Therefore, if not recently evaluated, a general metabolic health screen (CBC, chemistry panel with electrolytes and urinalysis) is recommended.

REFERRING VET

Dr. Habib

A gastrointestinal malabsorption panel (including cobalamin, folate, TLI and PLI) to Texas A&M GI Laboratory is recommended for further evaluation of GI and pancreatic function.

INVOICE

72161

Otherwise, further evaluation for possible pain (dental, orthopedic, other), upper respiratory disease or oropharyngeal disease, cardiac disease and/or neurologic disease vs other as possible causes for decreased appetite and/or unintentional weight loss is also recommended.

DATE

1/13/26



PATIENT

Gidget Ritchie

SPECIES

Canine

BREED

Yorkie

SEX

Spayed Female

AGE

6 Years

WEIGHT

4.5 lbs

INTERPRETED BY

Beth Johnson, DVM
DACVIM

IMAGING PERFORMED BY

Kelly Reschny

HOSPITAL NAME

Dog & Cat Clinic of
Niagara

REFERRING VET

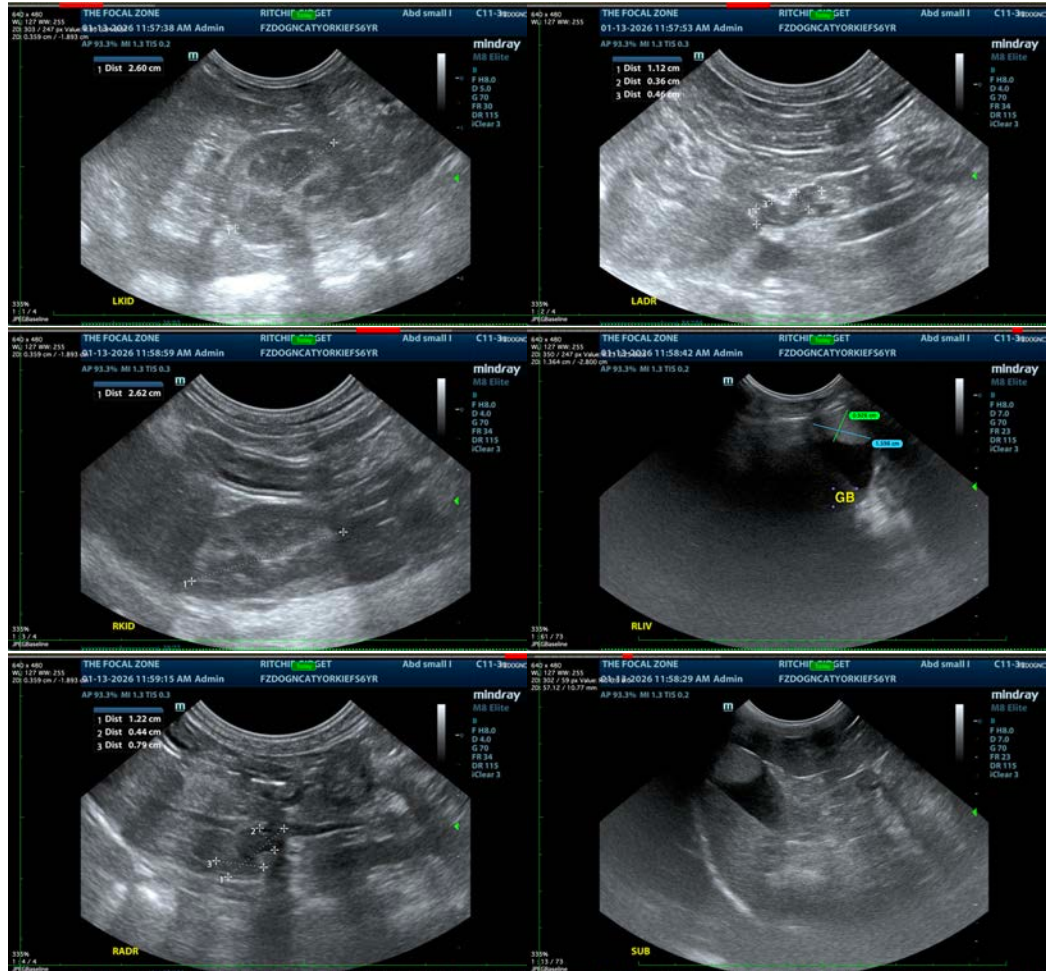
Dr. Habib

INVOICE

72161

DATE

1/13/26



The information and recommendations provided are based on the images presented by the referring veterinarian/sonographer. No evaluation can be communicated regarding pathology that was not visible in the image/video clips provided.

Thank you for this referral. If the clinical or image interpretation does not parallel your findings or if I can be of any further assistance please contact me.

Beth Johnson, DVM, DACVIM
info@sonopath.com