



PATIENT

Ace Enger

SPECIES

Canine

BREED

Beagle x

SEX

Neutered Male

AGE

14 Years 2 Months

WEIGHT

31

INTERPRETED BY

Beth Johnson, DVM
DACVIM

IMAGING PERFORMED BY

Brittney Beigel, DVM

HOSPITAL NAME

Bayside Animal
Medical Center

REFERRING VET

Kathryn Buchanan,
VMD

INVOICE

72178

DATE

1/13/26

PRESENTING CLINICAL SIGNS

Mild anemia, O elect US to screen for abnormal abdominal pathology that may correlate to mild anemia; P was fasted for US scan, sedated w/ butorphanol (10mg/mL) 0.28mL IM

Abnormal PE/Chem/CBC/UA Results: Attached

ULTRASONOGRAPHIC EXAMINATION OF THE ABDOMEN

Urinary System

Urinary bladder is only mildly distended. Visible contents are anechoic. Urinary bladder wall is unable to be fully assessed for pathology without further distension. No visible masses or definitive cystoliths are observed. The trigone and visible pelvic urethra are normal thickness with a smooth mucosal surface. In the face of urinary signs and/or suspected urinary bladder pathology, reassessment after complete filling is recommended.

Prostate is normal in size, echotexture and echogenicity for a neutered male.

Kidneys are overall normal in size and shape with smooth peripheral margination. A normal 1:3 cortex to medulla ratio is maintained. The medulla and cortices are uniform in texture with some mild increased cortical echogenicity and mild loss of corticomedullary distinction, expected in this age patient. There is no evidence of pyelectasia or infarcts observed. Left measures 5.47 cm. Right measures 5.63 cm. Pinpoint non-obstructive mineral densities noted bilaterally.

Adrenal Glands

The caudal pole of the left adrenal gland is normal in size (0.53 cm), shape and overall architecture, echogenicity and echotexture. Visible surrounding vasculature appears normal. The cranial pole is unable to be fully visualized.

The area of the right adrenal gland is examined without evident adrenal gland pathology.

Spleen

The spleen is subjectively normal in size with a normal smooth capsular contour. Parenchyma is appropriately finely textured and homogenous with normal echogenicity relative to surrounding tissue (hyperechoic to liver), except for an approximately 1.7 cm x 0.90 cm in size, mildly heterogeneous, largely hypo- to anechoic non-capsule disrupting nodule near the tail of the spleen. Splenic vasculature appears normal.

Liver

The liver is subjectively normal in size with normal smooth curvilinear peripheral contour. Parenchyma is appropriately hypoechoic to the spleen in echogenicity and appropriately mildly coarse and homogenous in echotexture, except for several discrete, homogeneous, hyperechoic nodules throughout the parenchyma, none measuring over 1.0 cm in size. Visible vasculature and biliary tree appear normal without distension or congestion.

Gallbladder is moderately distended with anechoic bile as well as suspended and gravity dependent echogenic debris. Some of the debris appears to be mineral/sand in appearance without any evidence of obstruction noted. The wall is smooth without visible thickening. There is no evidence of cystic or CBD dilation. There is no evidence of effusion or inflammation.



PATIENT

Ace Enger

SPECIES

Canine

BREED

Beagle x

SEX

Neutered Male

AGE

14 Years 2 Months

WEIGHT

31

INTERPRETED BY

Beth Johnson, DVM
DACVIM

IMAGING PERFORMED BY

Brittney Beigel, DVM

HOSPITAL NAME

Bayside Animal
Medical Center

REFERRING VET

Kathryn Buchanan,
VMD

INVOICE

72178

DATE

1/13/26

Gastrointestinal

The visible stomach wall is normal in thickness and layering. The lumen of the stomach is mildly distended with very echogenic reverberation artifact from intraluminal gas. There is no evidence of obstruction, foreign material, or infiltrative disease; however, visualization is partially inhibited by gas.

The visible small intestines are normal in wall thickness and layering. Hyperechoic mucosal fogging or speckling is noted. Small intestinal motility appears adequate (1-3 contractions per min). The lumen of the small intestine is empty with no evidence of obstruction or foreign material.

The visible colon is normal in wall thickness (< 0.2 cm) and layering. Contents are consistent with normal formed feces and gas.

Pancreas

The pancreas that is observed appears appropriately isoechoic to surrounding omental fat. Visible capsule is smooth and normal in contour. Visible pancreatic parenchyma is homogenous and unremarkable. There is no visible pancreatic duct dilation. There is no evidence of active peripancreatic inflammation.

Free Abdomen

There is no visible free peritoneal effusion noted in these images.

Mesenteric lymph nodes are prominent in size with swollen capsular contour. Normal elongated shape (length to width ratio) is maintained. There is no loss of parenchymal detail.

PRIMARY FINDINGS

- Moderate mucosal speckling – Mucosal speckling is often present with inflammatory bowel disease (IBD). It is not specific for type or severity of disease. Mild speckling change can occur as a normal patient variant in the post-prandial state.
- Hypo to anechoic splenic nodule – likely represents a benign lesion such as a cyst, hematoma, nodular hyperplasia, extramedullary hematopoiesis, etc., however while considered less likely, infiltrative neoplasia can mimic benign lesions, and cannot be ruled out.
- Liver nodules – Differentials for discrete hyperechoic liver nodules include primarily benign changes such as nodular hyperplasia, fibrosis of an old hematoma, granuloma, myelolipomas, etc.; however, while considered less likely, primary hepatic neoplasia, infiltrative round cell neoplasia and metastatic disease can mimic benign lesions and cannot be definitively ruled out.
- Moderate gallbladder debris - Cholecystic debris is of unknown clinical significance. It can be seen with biliary stasis from fasting or illness. Cholecystic debris is not necessarily related to hepatobiliary disease. Echogenic bile is most commonly an incidental finding in dogs and should be interpreted in combination with clinical signs such as nausea, inappetence, cranial abdominal discomfort and/or laboratory changes such as increased ALP and/or increased Tbili.
- Mildly reactive mesenteric lymph nodes – infiltrative neoplastic disease cannot be ruled out but is considered less likely.



PATIENT

Ace Enger

SPECIES

Canine

BREED

Beagle x

SEX

Neutered Male

AGE

14 Years 2 Months

WEIGHT

31

INTERPRETED BY

Beth Johnson, DVM
DACVIM

IMAGING PERFORMED BY

Brittney Beigel, DVM

HOSPITAL NAME

Bayside Animal
Medical Center

REFERRING VET

Kathryn Buchanan,
VMD

INVOICE

72178

DATE

1/13/26

SECONDARY FINDINGS

- Age related kidney changes with pinpoint non-obstructive mineral densities bilaterally.

INTERPRETATION OF THE FINDINGS & FURTHER RECOMMENDATIONS

The changes described above are largely subtle and trend in appearance toward benign. Having said that, infiltrative neoplasia affecting the spleen and/or emerging bowel disease contributing to a chronic, slow gastrointestinal bleed versus other can't be ruled out. Therefore, fine needle aspirates of the spleen could be considered if patient's coagulation status is appropriate.

Three view thoracic radiographs are recommended for further assessment of cardio-pulmonary status as well as to further evaluate for any evidence of metastatic disease, if not recently evaluated.

A routine fecal/giardia exam is recommended if not recently evaluated.

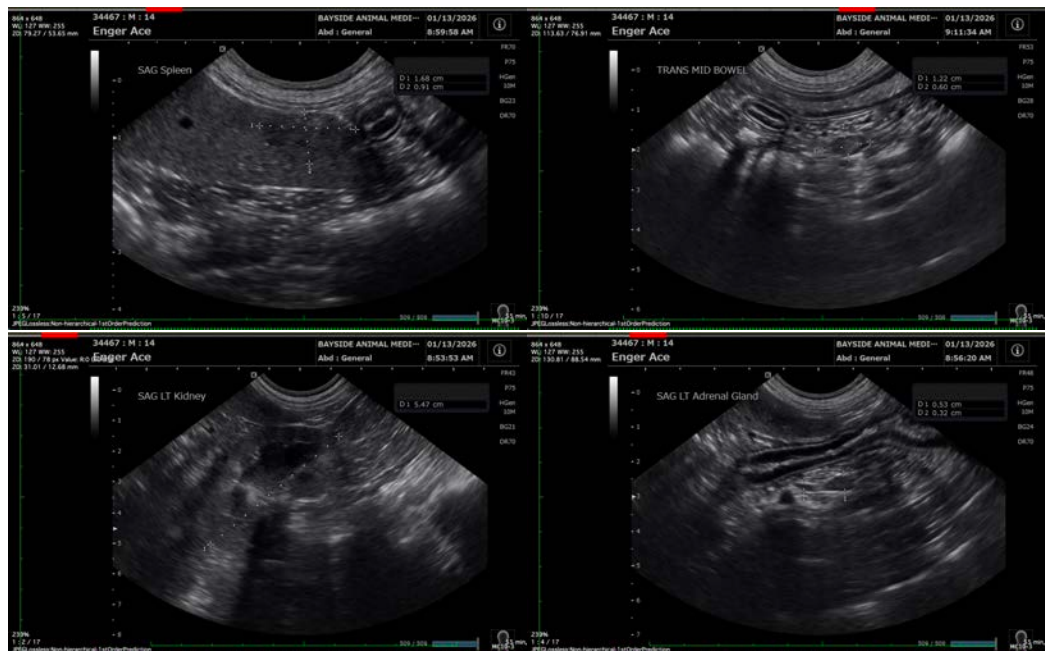
Especially in the face of any gastrointestinal history, a gastrointestinal malabsorption panel (including cobalamin, folate, TLI and PLI) to Texas A&M GI Laboratory is recommended for further evaluation of GI and pancreatic function.

A fecal enteropathogen PCR panel to Texas A&M GI Laboratory could be considered for further evaluation of possible infectious disease. Contact lab for recommendations on how long to discontinue antibiotics (if indicated) prior to obtaining a stool sample for submission.

A baseline cortisol is recommended. If baseline cortisol is less than 2, a full ACTH stimulation test is recommended to rule out hypoadrenocorticism.

Given the concurrent emerging leukopenia, bone marrow sampling could also be considered.

In the meantime, empirical deworming with a 5-day course of Panacur is recommended, as is antacid therapy while monitoring, just in case of a possible gastrointestinal bleed.





PATIENT

Ace Enger

SPECIES

Canine

BREED

Beagle x

SEX

Neutered Male

AGE

14 Years 2 Months

WEIGHT

31

INTERPRETED BY

Beth Johnson, DVM
DACVIM

IMAGING PERFORMED BY

Brittney Beigel, DVM

HOSPITAL NAME

Bayside Animal
Medical Center

REFERRING VET

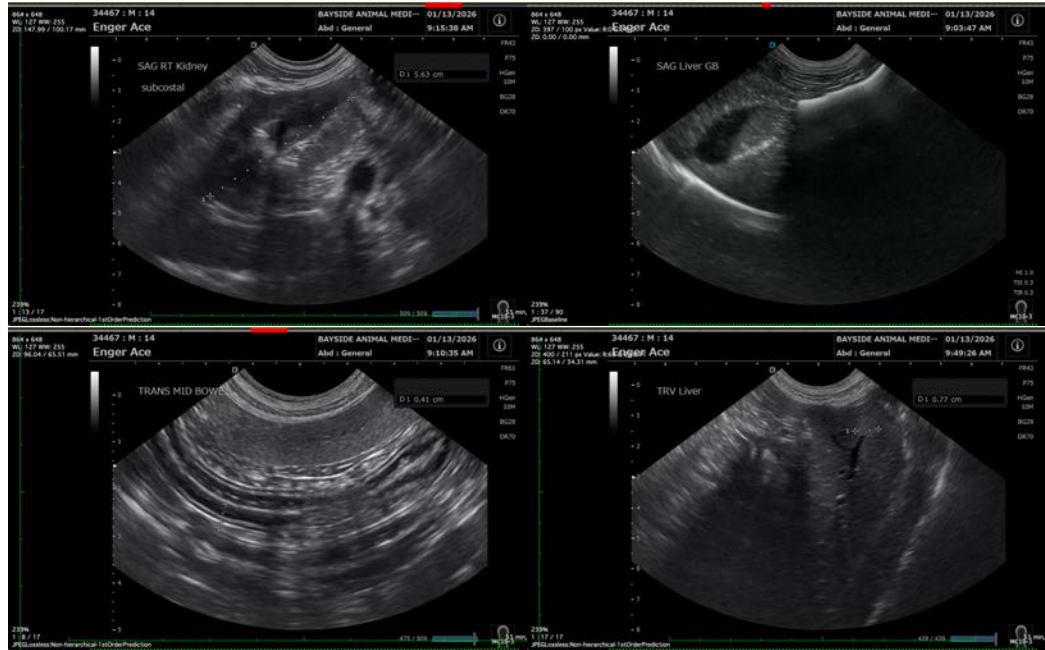
Kathryn Buchanan,
VMD

INVOICE

72178

DATE

1/13/26



The information and recommendations provided are based on the images presented by the referring veterinarian/sonographer. No evaluation can be communicated regarding pathology that was not visible in the image/video clips provided.

Thank you for this referral. If the clinical or image interpretation does not parallel your findings or if I can be of any further assistance please contact me.

Beth Johnson, DVM, DACVIM
info@sonopath.com