

## PATIENT

Elgar Hutcheon

## SPECIES

Canine

## BREED

Goldendoodle

## SEX

Neutered Male

## AGE

3 Years

## WEIGHT

68 Pounds

## INTERPRETED BY

Beth Johnson, DVM  
DACVIM

## IMAGING PERFORMED BY

Julia Bakker, DVM

## HOSPITAL NAME

Orange Blossom VI

## REFERRING VET

Diaphni Taylhardat,  
DVM

## INVOICE

35377

## DATE

1/12/26

## PRESENTING CLINICAL SIGNS

History: Pet has a history of intermittent bilious vomiting, lip smacking, and halitosis. Oral exam within normal limits. Bloodwork pending. Antacid trial and prescription GI food trial have not helped.

## ULTRASONOGRAPHIC EXAMINATION OF THE ABDOMEN

### *Urinary System*

Urinary bladder is only mildly distended. Visible contents are anechoic. Urinary bladder wall is unable to be fully assessed for pathology without further distension. No visible masses or definitive cystoliths are observed. The trigone and visible pelvic urethra are normal thickness with a smooth mucosal surface. In the face of urinary signs and/or suspected urinary bladder pathology, reassessment after complete filling is recommended.

Prostate is normal in size, echotexture and echogenicity for a neutered male.

Left kidney is normal in size (6.48 cm), shape and echogenicity. It has smooth peripheral margination. There is a normal 1:3 cortex to medulla ratio with appropriate corticomedullary distinction. There is no evidence of pyelectasia, mineral or infarcts observed.

Right kidney is normal in size (7.24 cm), shape and echogenicity. It has smooth peripheral margination. There is a normal 1:3 cortex to medulla ratio with appropriate corticomedullary distinction. There is no evidence of pyelectasia, mineral or infarcts observed.

### *Adrenal Glands*

Left adrenal gland is normal in size (0.6 cm at cranial pole and 0.49 cm at caudal pole), shape and overall architecture, echogenicity and echotexture. Visible surrounding vasculature appears normal.

Right adrenal gland is normal in size (1.6 cm at cranial pole and 0.58 cm at caudal pole), shape and overall architecture, echogenicity and echotexture. Visible surrounding vasculature appears normal.

### *Spleen*

Spleen is subjectively large in size (2.4 cm thick at the hilus) with a mildly swollen but smooth capsule. Parenchyma is normal and homogenous in echogenicity and echotexture. No focal nodules or masses are observed. Splenic vasculature appears normal.

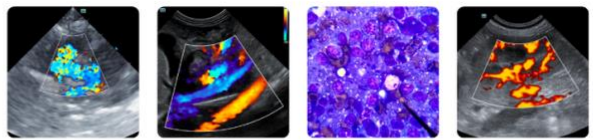
### *Liver*

Liver is subjectively normal in size with normal smooth curvilinear peripheral contour. Parenchyma is appropriately hypoechoic to the spleen in echogenicity and appropriately mildly coarse and homogenous in echotexture. No focal lesions are observed. Visible vasculature and biliary tree appear normal without distension or congestion.

Gallbladder is non-distended in size. The wall is smooth without visible thickening. Luminal contents are primarily anechoic. There is no evidence of cystic or common bile duct dilation.

### *Gastrointestinal*

The visible stomach wall is normal in thickness and layering. The lumen of the stomach is empty with no evidence of obstruction, foreign material or infiltrative disease. Pyloric outflow tract appears patent.



## PATIENT

Elgar Hutcheon

## SPECIES

Canine

## BREED

Goldendoodle

## SEX

Neutered Male

## AGE

3 Years

## WEIGHT

68 Pounds

## INTERPRETED BY

Beth Johnson, DVM  
DACVIM

## IMAGING PERFORMED BY

Julia Bakker, DVM

## HOSPITAL NAME

Orange Blossom VI

## REFERRING VET

Diaphni Taylhardat,  
DVM

## INVOICE

35377

## DATE

1/12/26

The visible small intestines are normal in wall thickness and layering. Small intestinal motility appears adequate (1-3 contractions per min). The lumen of the small intestine is empty with no evidence of obstruction, foreign material or infiltrative disease.

The visible colon is normal in wall thickness (< 0.2 cm) and layering. Contents are consistent with normal formed feces and gas.

### *Pancreas*

The pancreas that is observed appears appropriately isoechoic to surrounding omental fat. Visible capsule is smooth and normal in contour. Visible pancreatic parenchyma is homogenous and unremarkable. There is no visible pancreatic duct dilation. There is no evidence of active peripancreatic inflammation.

### *Free Abdomen*

There is no visible free peritoneal effusion noted in these images.

There is no apparent pathologic lymphadenopathy noted in these images.

## ULTRASONOGRAPHIC FINDINGS

- Splenomegaly- can be associated with congestion caused by sedation (if sedated) but can also be associated with diffuse infiltrative disease. Both benign conditions such as extramedullary hematopoiesis, lymphoid hyperplasia, as well as infiltrative neoplastic diseases such as round cell neoplasia should be considered.

## INTERPRETATION OF THE FINDINGS & FURTHER RECOMMENDATIONS

There is not a definitive intraabdominal ultrasonographically visible explanation for patients reported clinical signs. Sampling of the spleen via fine needle aspirate could be considered if patient's coagulation status is appropriate.

Otherwise, as is reportedly already pending, a full routine general metabolic health screen is recommended, to include CBC, chemistry panel, electrolytes, and urinalysis.

A baseline cortisol is recommended. If baseline cortisol is less than 2, a full ACTH stimulation test is recommended to rule out hypoadrenocorticism.

A gastrointestinal malabsorption panel (including cobalamin, folate, TLI and PLI) to Texas A&M GI Laboratory is recommended for further evaluation of GI and pancreatic function.

In the meantime, supportive/symptomatic medical management of clinical signs is recommended, including anti-emetics, gastroprotectants (+/- sucralfate, especially with any history of hematemesis), an appetite stimulant and fluid therapy if indicated, etc.

Additionally, empirical deworming with a 5-day course of Panacur is recommended as is a full course of empirical Helicobacter triple therapy.

Finally, if tolerated, a transition in diet could be considered, based on trial-and-error response with some options to consider including a gastrointestinal biome diet vs a hydrolyzed protein diet (sometimes several trials with different brands are necessary) vs an easy to digest, bland or low-fat diet vs other.



### PATIENT

Elgar Hutcheon

### SPECIES

Canine

### BREED

Goldendoodle

### SEX

Neutered Male

### AGE

3 Years

### WEIGHT

68 Pounds

### INTERPRETED BY

Beth Johnson, DVM  
DACVIM

### IMAGING PERFORMED BY

Julia Bakker, DVM

### HOSPITAL NAME

Orange Blossom VI

### REFERRING VET

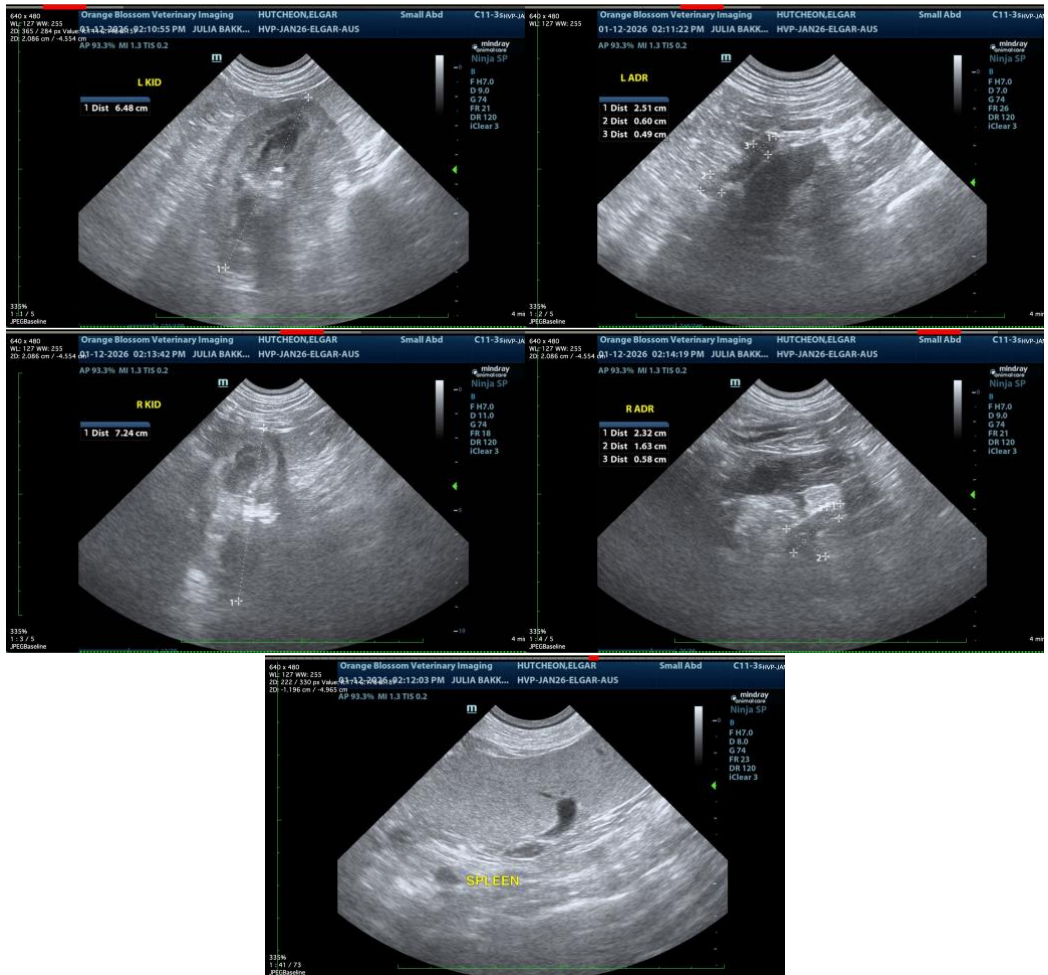
Diaphni Taylhardat,  
DVM

### INVOICE

35377

### DATE

1/12/26



The information and recommendations provided are based on the images presented by the referring veterinarian/sonographer. No evaluation can be communicated regarding pathology that was not visible in the image/video clips provided.

Thank you for this referral. If the clinical or image interpretation does not parallel your findings or if I can be of any further assistance please contact me.

**Beth Johnson, DVM DACVIM**

info@sonopath.com