



PATIENT

Sophie Ludwig

SPECIES

Canine

BREED

Havanese

SEX

Spayed Female

AGE

9 Years 7 Months

WEIGHT

10 Pounds

INTERPRETED BY

Beth Johnson, DVM
DACVIM

IMAGING PERFORMED BY

Dr. Ellen Puthoff

HOSPITAL NAME

Kings Vet Hospital

REFERRING VET

Dr. Ellen Puthoff

INVOICE

44175

DATE

1/12/23

PRESENTING CLINICAL SIGNS

Low nucleated red blood cells on routine bloodwork.

ULTRASONOGRAPHIC EXAMINATION OF THE ABDOMEN

Urinary System

The urinary bladder is moderately distended with anechoic contents. No masses, inflammatory changes, echogenic sediment or cystoliths are observed. The urinary bladder, trigone and visible pelvic urethra are normal in thickness with a smooth mucosal surface.

The right kidney is normal in size (4.2 cm), shape and echogenicity. It has smooth peripheral margination. There is a normal 1:3 cortex to medulla ratio with appropriate corticomedullary distinction. There is no evidence of pyelectasia, mineral or infarcts observed.

The left kidney is normal in size (3.7 cm), shape and echogenicity. It has smooth peripheral margination. There is a normal 1:3 cortex to medulla ratio with appropriate corticomedullary distinction. There is no evidence of pyelectasia, mineral or infarcts observed.

Adrenal Glands

The right adrenal gland is normal in size (0.90 cm at the cranial pole and 0.48 cm at the caudal pole), shape and contour. Corticomedullary structure is unremarkable. Visible surrounding vasculature appears normal.

The left adrenal gland is normal in size (0.45 cm at the cranial pole and 0.44 cm at the caudal pole), shape and contour. Corticomedullary structure is unremarkable. Visible surrounding vasculature appears normal.

Spleen

The spleen is subjectively normal in size with a normal smooth capsular contour. Parenchyma is appropriately finely textured and homogenous with normal echogenicity relative to surrounding tissue (hyperechoic to liver). No focal nodules or masses are observed. Splenic vasculature appears normal.

Liver

Liver is subjectively enlarged with mildly irregular margins. Parenchyma is heterogenous characterized by multiple poorly defined hypoechoic nodules within otherwise hyperechoic liver parenchyma. Visible vasculature and biliary tree appear normal without distension or congestion.

The gallbladder is non-distended in size. The wall is smooth without visible thickening. Luminal contents are primarily anechoic. There is no evidence of cystic or common bile duct dilation.

Gastrointestinal

The stomach wall is normal in thickness (canine < 0.5 cm and feline < 0.4 cm) and layering. The lumen of the stomach is empty with no evidence of obstruction, foreign material or infiltrative disease. Pyloric outflow tract appears patent.

The visible small intestines are normal in wall thickness and layering (canine duodenum < 0.5 cm and feline duodenum < 0.4 cm; other < 0.3 cm). Small intestinal motility appears adequate (1-3 contractions per min). The lumen of the small intestine is empty with no evidence of obstruction, foreign material or infiltrative disease.



PATIENT

Sophie Ludwig

The visible colon is normal in wall thickness (< 0.2 cm) and layering. Contents are consistent with normal formed feces and gas.

SPECIES

Canine

Pancreas

The pancreatic parenchyma is appropriately isoechoic to surrounding tissue. Visible capsule is smooth and normal in contour. There is no visible pancreatic duct dilation. There is no evidence of active peripancreatic inflammation.

BREED

Havanese

Free Abdomen

There is no evidence of free peritoneal effusion noted in these images.

SEX

Spayed Female

In the cranial abdomen, just caudal to the liver, there is a prominent round structure, most likely a lymph node that measures 0.70 cm x 0.80 cm and is surrounded by mildly enhanced hyperechoic fat.

AGE

9 Years 7 Months

ULTRASONOGRAPHIC FINDINGS

- **Heterogenous Liver** – These changes are most consistent with benign processes such as nodular hyperplasia, steroid (vacuolar) hepatopathy, extramedullary hematopoiesis or possibly chronic inflammatory disease and less commonly infiltrative round cell or metastatic neoplasia.
- **Cranial abdominal/hepatic lymphadenopathy** – Differentials include both reactive lymphadenopathy as well as infiltrative neoplasia and cannot be differentiated without tissue sampling.

WEIGHT

10 Pounds

INTERPRETED BY

Beth Johnson, DVM
DACVIM

INTERPRETATION OF THE FINDINGS & FURTHER RECOMMENDATIONS

Fine needle aspirates of the liver and the enlarged cranial abdominal lymph node, if possible to reach and if patient's coagulation status is appropriate, could be considered.

Additionally, monitoring of the CBC for either improvement/resolution or progression of the reported changes is recommended to help guide future intervention.

IMAGING PERFORMED BY

Dr. Ellen Puthoff

HOSPITAL NAME

Kings Vet Hospital

REFERRING VET

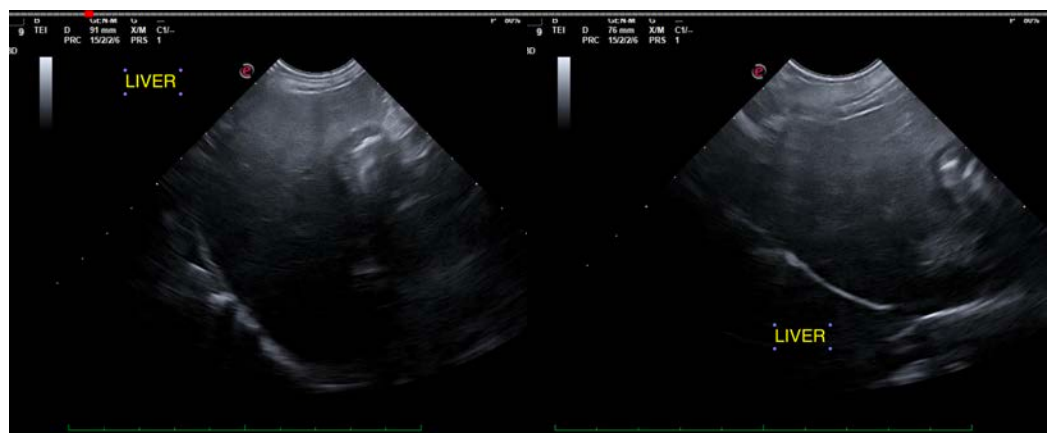Dr. Ellen Puthoff

INVOICE

44175

DATE

1/12/23





PATIENT

Sophie Ludwig

SPECIES

Canine

BREED

Havanese

SEX

Spayed Female

AGE

9 Years 7 Months

WEIGHT

10 Pounds

INTERPRETED BY

Beth Johnson, DVM
DACVIM

IMAGING PERFORMED BY

Dr. Ellen Puthoff

HOSPITAL NAME

Kings Vet Hospital

REFERRING VET

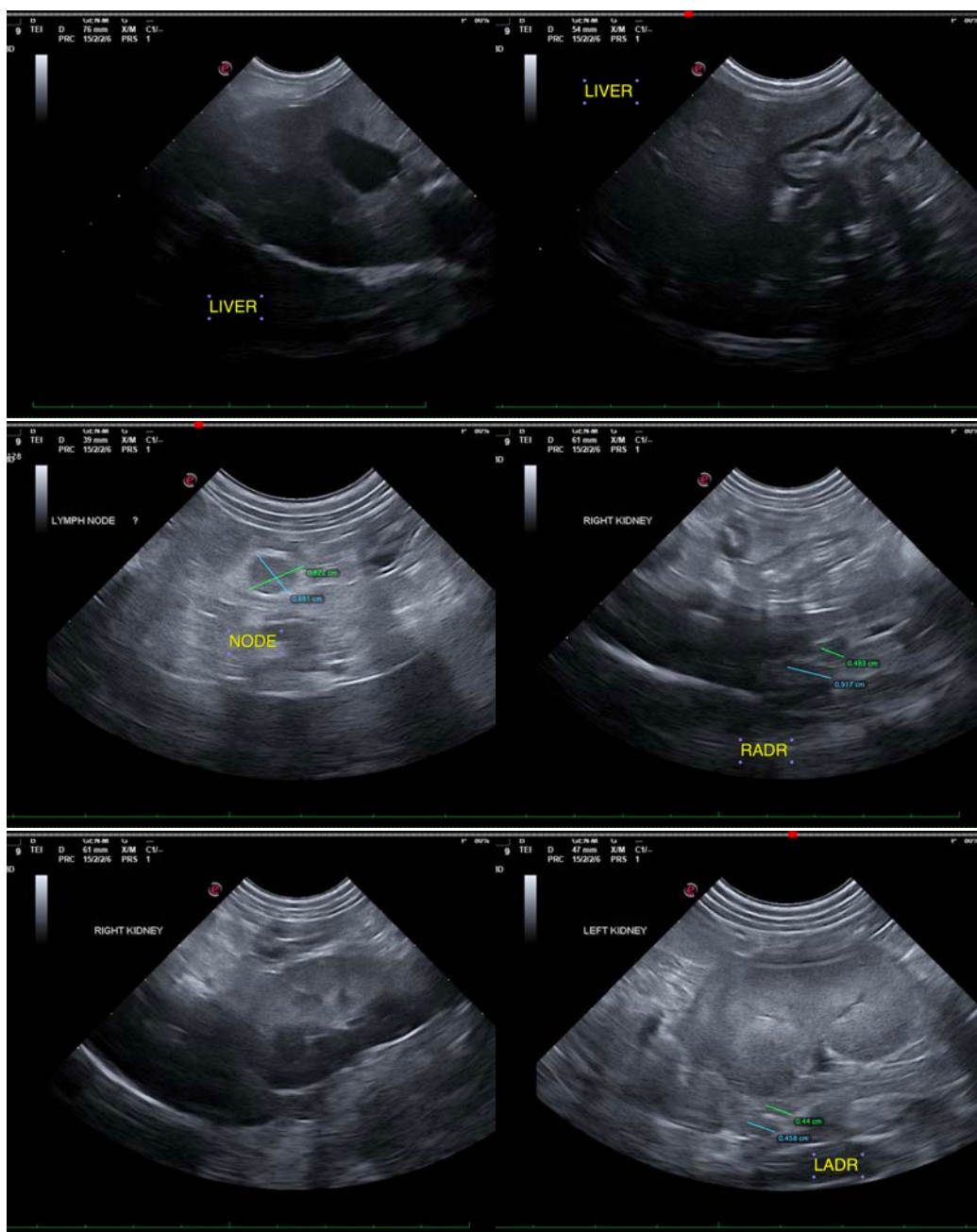
Dr. Ellen Puthoff

INVOICE

44175

DATE

1/12/23





PATIENT

Sophie Ludwig

SPECIES

Canine

BREED

Havanese

SEX

Spayed Female

AGE

9 Years 7 Months

WEIGHT

10 Pounds

INTERPRETED BY

Beth Johnson, DVM
DACVIM

**IMAGING
PERFORMED BY**

Dr. Ellen Puthoff

HOSPITAL NAME

Kings Vet Hospital

REFERRING VET

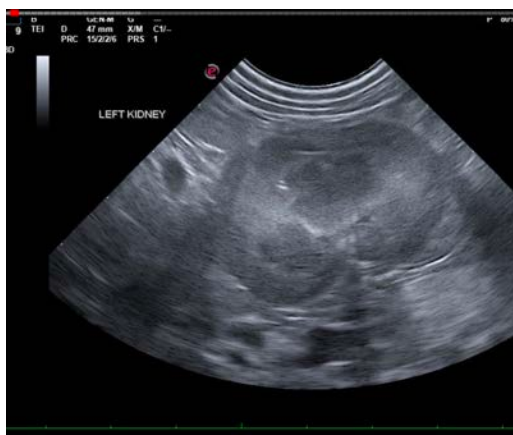Dr. Ellen Puthoff

INVOICE

44175

DATE

1/12/23



The information and recommendations provided are based on the images presented by the referring veterinarian/sonographer. No evaluation can be communicated regarding pathology that was not visible in the image/video clips provided.

Thank you for this referral. If the clinical or image interpretation does not parallel your findings or if I can be of any further assistance please contact me.

Beth Johnson, DVM, DACVIM
Beth.Johnson@sonopath.com