



PATIENT PRESENTING CLINICAL SIGNS

Honey Penny Flego 12 yo FS golden doodle, acute increase in ALP-approximately 900, other wise NSF on blood work. Presented for tenesmus and diarrhea.
Abnormal PE/Chem/CBC/UA Results: ALP 910 WBC: 261, Lymphocytes: 253,665, Monocytosis: 2615.

SPECIES

Canine

ULTRASONOGRAPHIC EXAMINATION OF THE ABDOMEN

Urinary System

BREED

Golden Doodle

Urinary bladder is moderately distended with anechoic contents. No masses, inflammatory changes, echogenic sediment or cystoliths are observed. The urinary bladder, trigone and visible pelvic urethra are normal in thickness with a smooth mucosal surface.

SEX

Spayed Female

Right kidney is normal in size (6.83 cm), shape and echogenicity. It has smooth peripheral margination. There is a normal 1:3 cortex to medulla ratio with appropriate corticomedullary distinction. There is no evidence of pyelectasia, mineral or infarcts observed.

AGE

12 Years

Left kidney is normal in size (6.27 cm), shape and echogenicity. It has smooth peripheral margination. There is a normal 1:3 cortex to medulla ratio with appropriate corticomedullary distinction. There is no evidence of pyelectasia, mineral or infarcts observed.

WEIGHT

71 Pounds

Adrenal Glands

Right adrenal gland is normal in size (0.75 cm at cranial pole and 0.54 cm at caudal pole), shape and contour. Corticomedullary structure is unremarkable. Visible surrounding vasculature appears normal.

Left adrenal gland is normal in size (0.68 cm at cranial pole and 0.55 cm at caudal pole), shape and contour. Corticomedullary structure is unremarkable. Visible surrounding vasculature appears normal.

INTERPRETED BY

Beth Johnson, DVM
DACVIM

Spleen

Spleen is subjectively enlarged in size with rounded margins but intact capsule. Parenchyma is homogenously coarse/mottled in echotexture and normal to hypoechoic in echogenicity. No focal nodules or masses are observed. Splenic vasculature appears normal.

HOSPITAL NAME

Long Branch AH

Liver

Liver is subjectively enlarged. Margins are smooth but round. It has a normal homogenous echotexture. Parenchyma is diffusely hyperechoic characterized by less prominent than normal portal vein walls and increased echogenicity relative to the spleen. No focal lesions are observed. Visible vasculature and biliary tree appear normal without distension or congestion.

REFERRING VET

Dr. Elaina Petrone

Gallbladder is non-distended in size. The wall is smooth without visible thickening. Luminal contents are primarily anechoic. There is no evidence of cystic or common bile duct dilation.

Gastrointestinal

INVOICE NUMBER

34157

The stomach wall is normal in thickness (canine < 0.5 cm and feline < 0.4 cm) and layering. The lumen of the stomach is mildly distended with echogenic non-shadowing luminal contents and gas consistent with normal ingesta. There is no evidence of obstruction, foreign material or infiltrative disease. Pyloric outflow tract appears patent.

DATE

1/12/22



PATIENT

Honey Penny Flego

The visible small intestines are normal in wall thickness and layering (canine duodenum < 0.5 cm and feline duodenum < 0.4 cm; other < 0.3 cm). Small intestinal motility appears adequate (1-3 contractions per min). The lumen of the small intestine is empty with no evidence of obstruction, foreign material or infiltrative disease.

SPECIES

Canine

The visible colon is normal in wall thickness (< 0.2 cm) and layering. Contents are consistent with normal formed feces and gas.

Pancreas

BREED

Golden Doodle

Pancreatic parenchyma is appropriately isoechoic to surrounding tissue. Visible capsule is smooth and normal in contour. There is no visible pancreatic duct dilation. There is no evidence of active peripancreatic inflammation.

Free Abdomen

SEX

Spayed Female

There is no evidence of peritoneal effusion. There is no apparent lymphadenopathy.

AGE

12 Years

ULTRASONOGRAPHIC FINDINGS

- Coarse splenomegaly – can be associated with congestion caused by sedation (if sedated) but can also be associated with diffuse infiltrative disease. Both benign conditions such as extramedullary hematopoiesis, lymphoid hyperplasia, as well as infiltrative neoplastic diseases such as round cell neoplasia should be considered.
- Hyperechoic hepatomegaly canine – most consistent with benign steroid (endocrine) hepatopathy or reactive or idiopathic hepatopathy. Infiltrative neoplasia such as round cell neoplasia is also possible, but considered less likely.

INTERPRETATION OF THE FINDINGS & FURTHER RECOMMENDATIONS

INTERPRETED BY

Beth Johnson, DVM
DACVIM

Given this patient's signalment and marked lymphocytosis, the top differential is lymphocytic leukemia, likely chronic lymphocytic leukemia, potentially based on this ultrasound study affecting the liver and spleen. Diagnostics could include tick borne disease testing to rule out a tick borne infection that can also sometimes result in a lymphocytosis. Fine needle aspirate of the liver and spleen could be considered if patient's coagulation status is appropriate. A pathology review of the CBC is also recommended. Ultimately, the course of this disease can be slow with minimal clinical signs. However, given this patient's marked lymphocytosis combined with organomegaly, referral/consultation with an oncologist as soon as possible is recommended.

HOSPITAL NAME

Long Branch AH

REFERRING VET

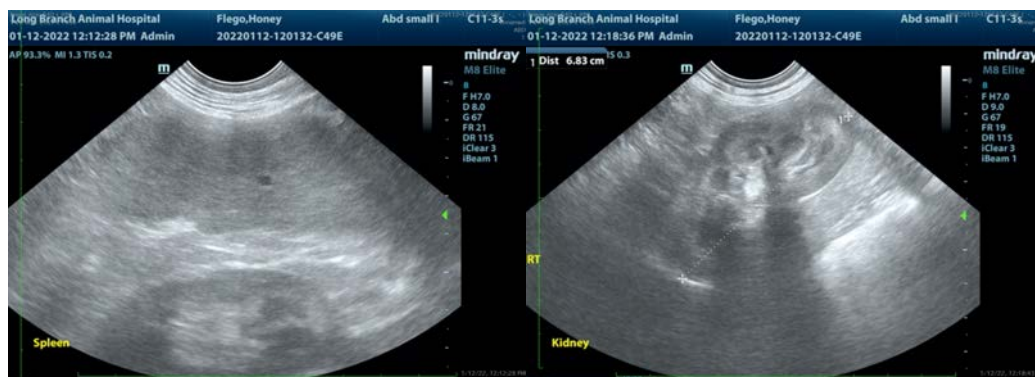
Dr. Elaina Petrone

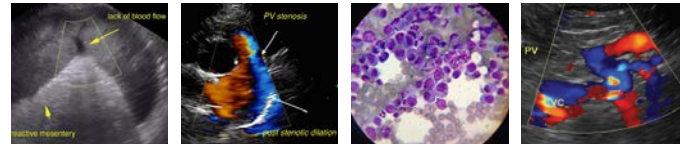
INVOICE NUMBER

34157

DATE

1/12/22





PATIENT

Honey Penny Flego

SPECIES

Canine

BREED

Golden Doodle

SEX

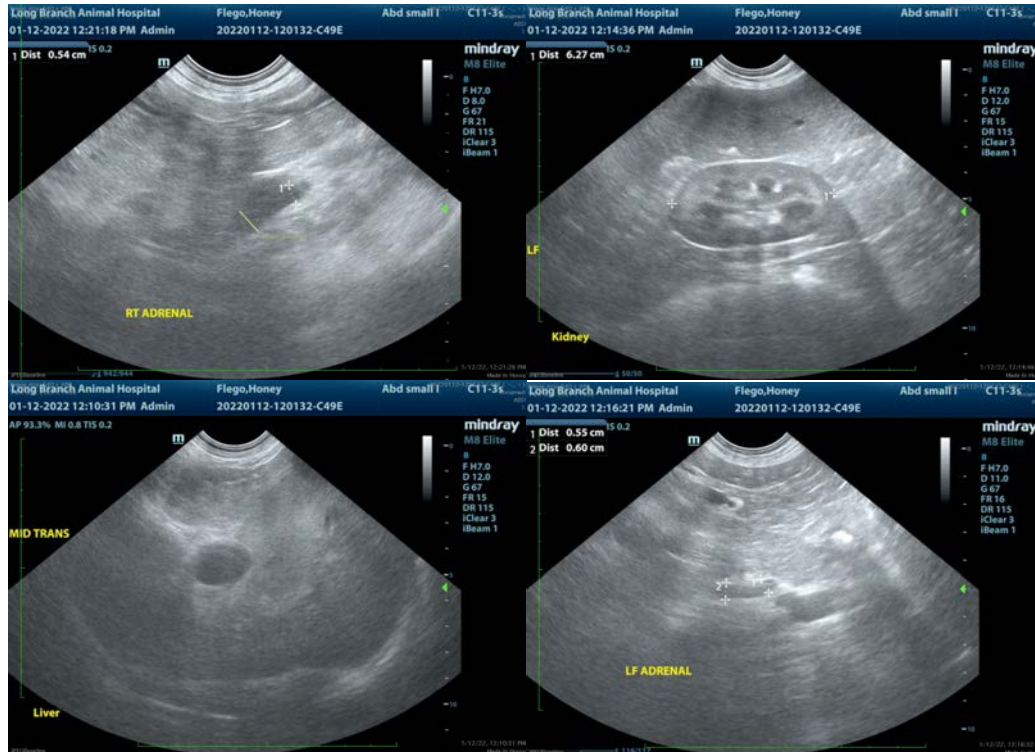
Spayed Female

AGE

12 Years

WEIGHT

71 Pounds



The information and recommendations provided are based on the images presented by the referring veterinarian. No evaluation can be communicated regarding pathology that was not visible in the image/video clips provided.

INTERPRETED BY

Beth Johnson, DVM
DACVIM

Beth Johnson, DVM, DACVIM
Beth.Johnson@sonopath.com

Thank you for this referral. If the clinical or image interpretation does not parallel your findings or if I can be of any further assistance please contact me.

HOSPITAL NAME

Long Branch AH

REFERRING VET

Dr. Elaina Petrone

INVOICE NUMBER

34157

DATE

1/12/22