



**PATIENT**

Sigma Leinheiser

**SPECIES**

Canine

**BREED**

Boxer X

**SEX**

Spayed Female

**AGE**

23 Months

**WEIGHT**

36.7 Pounds

**INTERPRETED BY**

Beth Johnson, DVM  
DACVIM

**IMAGING PERFORMED BY**

Dr. Saum Hadi

**HOSPITAL NAME**

Bethany Family PC

**REFERRING VET**

Dr. Saum Hadi

**INVOICE**

44097

**DATE**

1/11/23

**PRESENTING CLINICAL SIGNS**

P presents for acute lethargy, hyporexia, and vomiting. P has vomited brown liquid vomit multiple times (> 10) in the last 24 hours.

Abnormal PE/Chem/CBC/UA Results: No lab work yet

**ULTRASONOGRAPHIC EXAMINATION OF THE ABDOMEN**

**Urinary System**

Urinary bladder is adequately distended. It has a normal uniform wall thickness. Contents include primarily anechoic fluid with occasional echogenic non-shadowing debris, most consistent with exfoliated cells, mucous and/or small blood clots. Both sterile inflammation as well as urinary tract infection can also present with echogenic debris. No masses or cystoliths are observed. The trigone and visible pelvic urethra are normal in thickness with a smooth mucosal surface.

The right kidney is normal in size (6.0 cm), shape and echogenicity. It has smooth peripheral margination. There is a normal 1:3 cortex to medulla ratio with appropriate corticomedullary distinction. There is no evidence of pyelectasia, mineral or infarcts observed.

The left kidney is normal in size (5.4 cm), shape and echogenicity. It has smooth peripheral margination. There is a normal 1:3 cortex to medulla ratio with appropriate corticomedullary distinction. There is no evidence of pyelectasia, mineral or infarcts observed.

**Adrenal Glands**

The caudal pole of the right adrenal gland is normal in size (0.50 cm at the caudal pole), shape and contour. The cranial pole is not fully visualized in these images.

The left adrenal gland is normal in size (0.29 cm at the cranial pole and 0.32 cm at the caudal pole), shape and contour. Corticomedullary structure is unremarkable. Visible surrounding vasculature appears normal.

**Spleen**

The spleen is subjectively normal in size with a normal smooth capsular contour. Parenchyma is appropriately finely textured and homogenous with normal echogenicity relative to surrounding tissue (hyperechoic to liver). No focal nodules or masses are observed. Splenic vasculature appears normal.

**Liver**

The liver is subjectively normal in size with normal smooth curvilinear peripheral contour. Parenchyma is appropriately hypoechoic to the spleen in echogenicity and appropriately mildly coarse and homogenous in echotexture. No focal lesions are observed. Visible vasculature and biliary tree appear normal without distension or congestion.

The gallbladder is non-distended in size. The wall is smooth without visible thickening. Luminal contents are primarily anechoic. There is no evidence of cystic or common bile duct dilation.

**Gastrointestinal**

Fundic mucosal hypertrophy with hyperechoic mucosa and some mucosal remodeling is noted. There is no loss of mural detail. Layering is normal. There is mild luminal fluid accumulation. No evidence of masses/nodules or foreign material present.



<b>PATIENT</b>	The visible small intestines are normal in wall thickness and layering (canine duodenum < 0.5 cm and feline duodenum < 0.4 cm; other < 0.3 cm). Small intestinal motility appears adequate (1-3 contractions per min). The lumen of the small intestine is empty with no evidence of obstruction, foreign material or infiltrative disease.
Sigma Leinheiser	
<b>SPECIES</b>	The visible colon is normal in wall thickness (< 0.2 cm) and layering. Contents are consistent with normal formed feces and gas.
Canine	
<b>BREED</b>	<b>Pancreas</b>
Boxer X	The pancreatic parenchyma is appropriately isoechoic to surrounding tissue. Visible capsule is smooth and normal in contour. There is no visible pancreatic duct dilation. There is no evidence of active peripancreatic inflammation.
<b>SEX</b>	<b>Free Abdomen</b>
Spayed Female	There is no evidence of free peritoneal effusion noted in these images.
<b>AGE</b>	The mesenteric and medial iliac lymph nodes are prominent in size with swollen capsular contour. Normal elongated shape (length to width ratio) is maintained. There is no loss of parenchymal detail.
23 Months	
<b>WEIGHT</b>	<b>PRIMARY FINDINGS</b>
36.7 Pounds	<ul style="list-style-type: none"> <li>• <b>Gastritis</b> – Consistent with irritation secondary to dietary indiscretion or intolerance, infection (bacterial, viral, other), parasitic or protozoal disease, toxin, other metabolic disease such as pancreatitis, other. Microulceration cannot be ruled out.</li> <li>• <b>Reactive medial iliac and mesenteric lymph nodes</b> – infiltrative neoplastic disease cannot be ruled out but is considered less likely.</li> </ul>
<b>INTERPRETED BY</b>	<b>SECONDARY FINDINGS</b>
Beth Johnson, DVM DACVIM	<ul style="list-style-type: none"> <li>• Urinary bladder debris</li> </ul>
<b>IMAGING PERFORMED BY</b>	<b>INTERPRETATION OF THE FINDINGS &amp; FURTHER RECOMMENDATIONS</b>
Dr. Saum Hadi	Recommendations (if not recently evaluated) include a fecal exam, as well as an overall metabolic health screen including CBC/Chem panel, electrolytes, a urinalysis and, if indicated based on urinalysis results, urine culture. If protein is present in an otherwise quiet sediment, protein quantification with a urine protein to creatinine ration is recommended.
<b>HOSPITAL NAME</b>	In the meantime, medical management of suspected gastritis with supportive/symptomatic therapy is recommended, beginning with antiemetics, gastroprotectants, empirical deworming with a 5-day course of Panacur, and transition to a bland, easy to digest diet.
Bethany Family PC	
<b>REFERRING VET</b>	Additionally, empirical therapy for helicobacter could be considered. If there is any chronicity to this patient's gastrointestinal upset, and/or if episodes have been intermittent, additional diagnostic considerations could include a baseline cortisol. If baseline cortisol is less than 2, a full ACTH stimulation test is recommended to rule out hypoadrenocorticism.
Dr. Saum Hadi	
<b>INVOICE</b>	A gastrointestinal malabsorption panel (including cobalamin, folate, TLI and PLI) to Texas A&M GI Laboratory is recommended for further evaluation of GI and pancreatic function.
44097	Otherwise, if clinical signs persist, recheck imaging including x-rays and ultrasound are recommended.
<b>DATE</b>	
1/11/23	



**PATIENT**

Sigma Leinheiser

**SPECIES**

Canine

**BREED**

Boxer X

**SEX**

Spayed Female

**AGE**

23 Months

**WEIGHT**

36.7 Pounds

**INTERPRETED BY**

Beth Johnson, DVM  
DACVIM

**IMAGING PERFORMED BY**

Dr. Saum Hadi

**HOSPITAL NAME**

Bethany Family PC

**REFERRING VET**

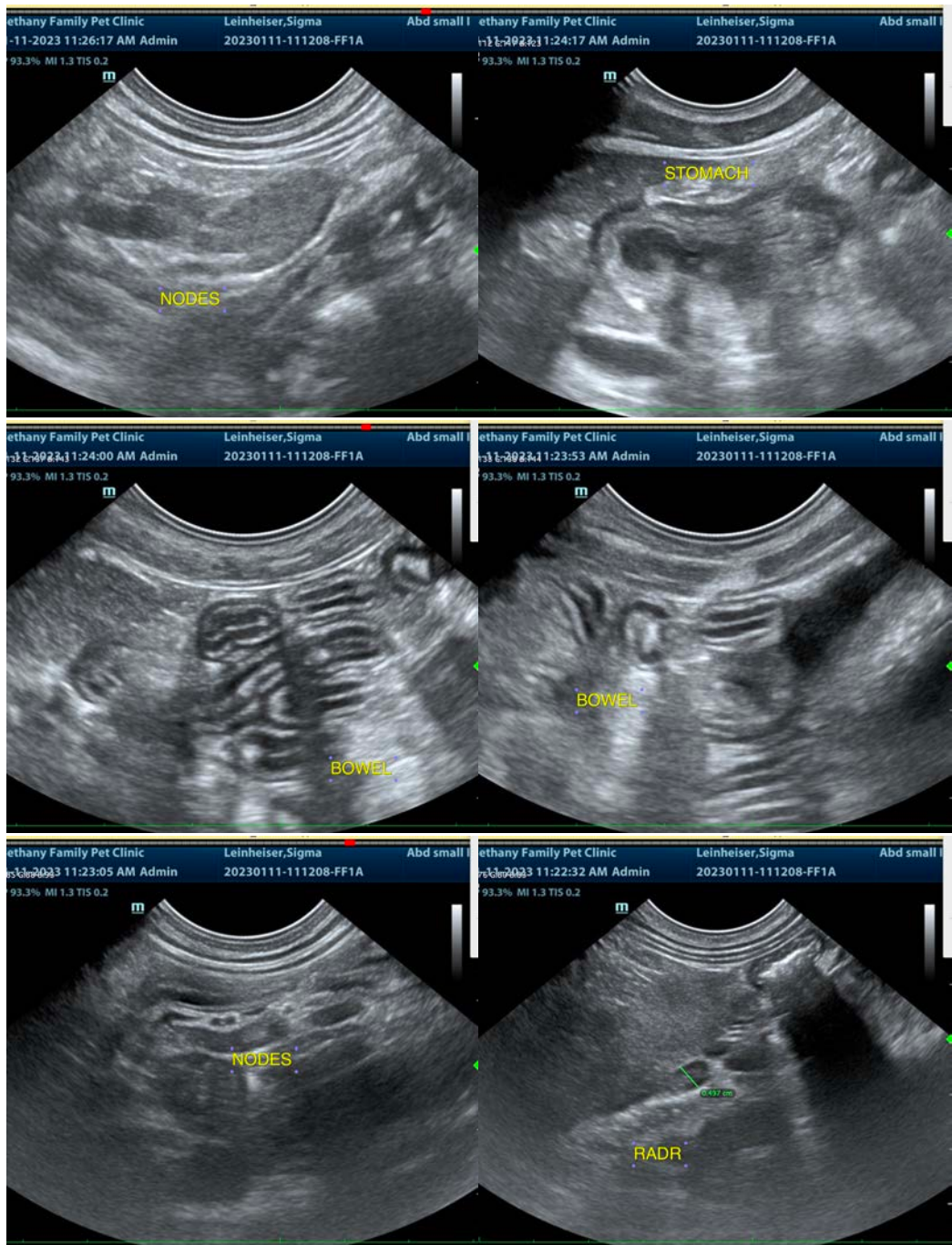
Dr. Saum Hadi

**INVOICE**

44097

**DATE**

1/11/23





**PATIENT**

Sigma Leinheiser

**SPECIES**

Canine

**BREED**

Boxer X

**SEX**

Spayed Female

**AGE**

23 Months

**WEIGHT**

36.7 Pounds

**INTERPRETED BY**

Beth Johnson, DVM  
DACVIM

**IMAGING PERFORMED BY**

Dr. Saum Hadi

**HOSPITAL NAME**

Bethany Family PC

**REFERRING VET**

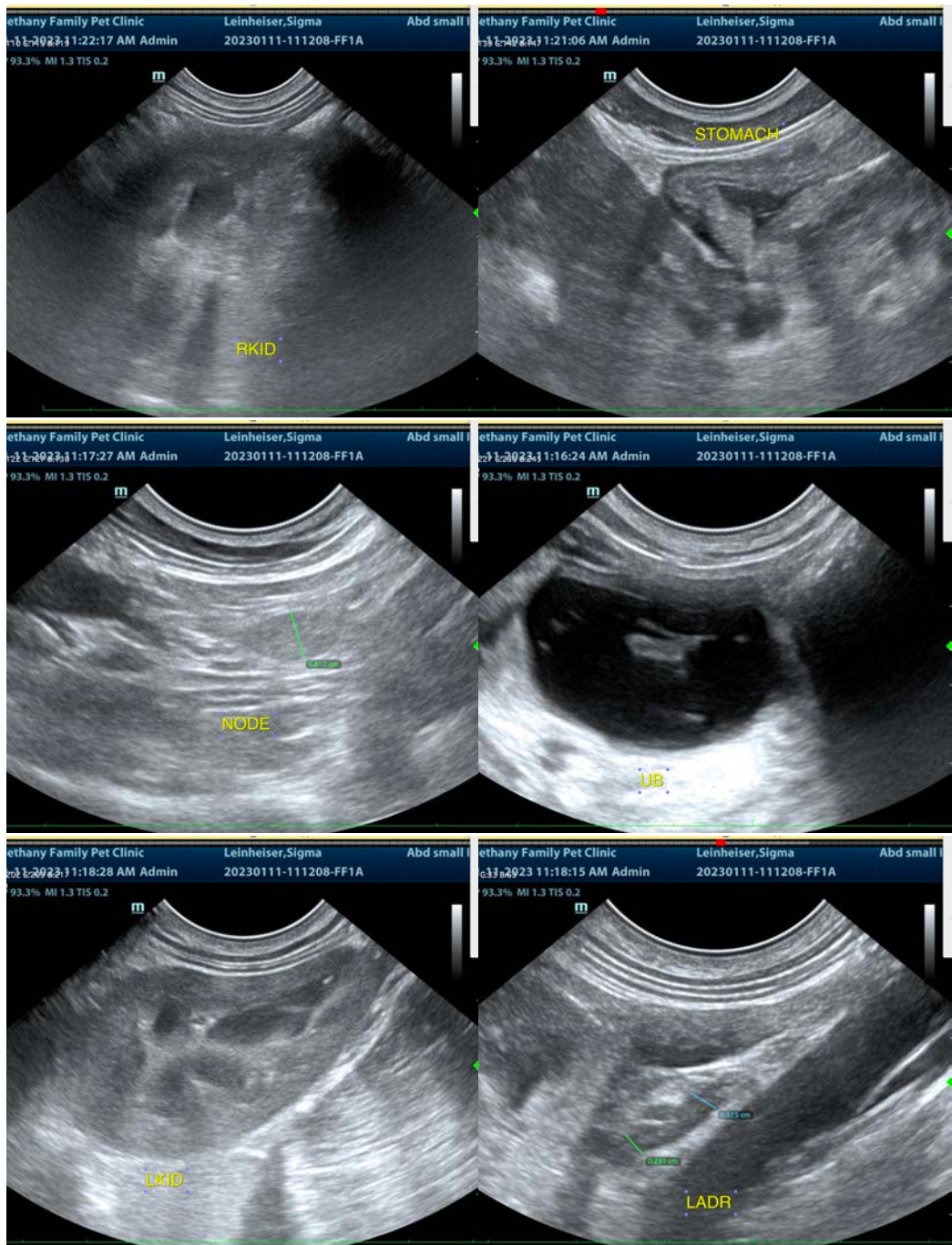
Dr. Saum Hadi

**INVOICE**

44097

**DATE**

1/11/23



The information and recommendations provided are based on the images presented by the referring veterinarian/sonographer. No evaluation can be communicated regarding pathology that was not visible in the image/video clips provided.

Thank you for this referral. If the clinical or image interpretation does not parallel your findings or if I can be of any further assistance please contact me.

**Beth Johnson, DVM, DACVIM**  
Beth.Johnson@sonopath.com