



PATIENT	PRESENTING CLINICAL SIGNS
Brandy Courtnight	DKA , newly diagnosed diabetic, elevated liver enzymes, hepatomegaly on rads. On unasyn, cerenia, IVECCs protocol.
SPECIES	Abnormal PE/Chem/CBC/UA Results: glu > 600, ALT 133, ALKP 7900, Cl decr 90, chol 419, WBC 27.05 with neutrophilia. anaplasma positive.
Canine	
BREED	ULTRASONOGRAPHIC EXAMINATION OF THE ABDOMEN
Miniature Pinscher X	Urinary System
SEX	Urinary bladder is adequately distended. It has a normal uniform wall thickness. Contents include primarily anechoic fluid with occasional echogenic non-shadowing debris, most consistent with exfoliated cells, mucous and/or small blood clots. Both sterile inflammation as well as urinary tract infection can also present with echogenic debris. No masses or cystoliths are observed. The trigone and visible pelvic urethra are normal in thickness with a smooth mucosal surface.
Spayed Female	
AGE	The right kidney is normal in size (6.22 cm), shape and echogenicity. It has smooth peripheral margination. There is a normal 1:3 cortex to medulla ratio with appropriate corticomedullary distinction. There is no evidence of pyelectasia, mineral or infarcts observed. A hyperechoic band parallel to the corticomedullary border is present.
9 Years	
WEIGHT	The left kidney is normal in size (5.9 cm), shape and echogenicity. It has smooth peripheral margination. There is a normal 1:3 cortex to medulla ratio with appropriate corticomedullary distinction. There is no evidence of pyelectasia, mineral or infarcts observed. A hyperechoic band parallel to the corticomedullary border is present.
52 Pounds	
INTERPRETED BY	Adrenal Glands
Beth Johnson, DVM DACVIM	The right adrenal gland is normal in size (2.71 cm long x 1.06 cm at the cranial pole and 0.58 cm at the caudal pole), shape and contour. Corticomedullary structure is unremarkable. Visible surrounding vasculature appears normal.
IMAGING PERFORMED BY	The left adrenal gland is normal in size (1.72 cm long x 0.53 cm at the cranial pole and 0.47 cm at the caudal pole), shape and contour. Corticomedullary structure is unremarkable. Visible surrounding vasculature appears normal.
Diane McFadden	
HOSPITAL NAME	Spleen
Newton Vet Hospital	The spleen is subjectively normal in size with a normal smooth capsular contour. Parenchyma is appropriately finely textured and homogenous with normal echogenicity relative to surrounding tissue (hyperechoic to liver). No focal nodules or masses are observed. Splenic vasculature appears normal.
REFERRING VET	Liver
Dr. Barron	Liver is subjectively enlarged (swollen contour) without disruption of architecture. It has a normal homogenous echotexture. Parenchyma is diffusely hyperechoic characterized by less prominent than normal portal vein walls and increased echogenicity relative to the spleen and falciform fat. No focal lesions are observed. Visible vasculature and biliary tree appear normal without distension or congestion.
INVOICE	The gallbladder is non-distended in size. The wall is smooth without visible thickening. Luminal contents are primarily anechoic. There is no evidence of cystic or common bile duct dilation.
44114	
DATE	
1/11/23	



PATIENT

Brandy Courtright

SPECIES

Canine

BREED

Miniature Pinscher X

SEX

Spayed Female

AGE

9 Years

WEIGHT

52 Pounds

INTERPRETED BY

Beth Johnson, DVM
DACVIM

IMAGING PERFORMED BY

Diane McFadden

HOSPITAL NAME

Newton Vet Hospital

REFERRING VET

Dr. Barron

INVOICE

44114

DATE

1/11/23

Gastrointestinal

The stomach wall is normal in thickness (canine < 0.5 cm and feline < 0.4 cm) and layering. The lumen of the stomach is empty with no evidence of obstruction, foreign material or infiltrative disease. Pyloric outflow tract appears patent.

The visible small intestines are normal in wall thickness and layering. Small intestinal motility appears adequate (1-3 contractions per min). The lumen of the small intestine is mildly distended with echogenic non-shadowing luminal contents and gas consistent with normal ingesta. There is no evidence of obstruction, foreign material or infiltrative disease.

The visible colon is normal in wall thickness (< 0.2 cm) and layering. Contents are consistent with normal formed feces and gas.

Pancreas

The pancreatic parenchyma is appropriately isoechoic to surrounding tissue. Visible capsule is smooth and normal in contour. There is no visible pancreatic duct dilation. There is no evidence of active peripancreatic inflammation.

Free Abdomen

There is no evidence of free peritoneal effusion noted in these images.

There is no apparent lymphadenopathy noted in these images.

PRIMARY FINDINGS

- **Bilateral medullary rim sign** - This finding is of unknown clinical significance and can be a normal variant, often idiopathic. Medullary rim sign can be present with renal disease including FIP, lymphoma, hypercalcemic nephropathy, Leptospirosis, tubular disease, other and should be interpreted in combination with other more specific indications of kidney disease such as isosthenuria, proteinuria, azotemia, etc. This is a common incidental finding in patients with diabetes mellitus.
- **Hyperechoic hepatomegaly** - This appearance is non-specific and most consistent with a benign steroid (endocrine) or vacuolar hepatopathy or reactive or idiopathic hepatopathy. Inflammatory and/or infiltrative disease (such as round cell neoplasia) are also possible, but considered less likely.

SECONDARY FINDINGS

- Urinary bladder debris

INTERPRETATION OF THE FINDINGS & FURTHER RECOMMENDATIONS

This is a relatively unremarkable abdomen short of changes consistent with diabetes mellitus. Therefore, recommendations include (if not recently evaluated) a urinalysis and, if indicated based on urinalysis results, urine culture are recommended. If protein is present in an otherwise quiet sediment, protein quantification with a urine protein to creatinine ration is recommended.

Medical management of the reported DKA, anaplasma +/- urinary tract infection (if present) is also recommended.



PATIENT

Brandy Courtnight

SPECIES

Canine

BREED

Miniature Pinscher X

SEX

Spayed Female

AGE

9 Years

WEIGHT

52 Pounds

INTERPRETED BY

Beth Johnson, DVM
DACVIM

IMAGING PERFORMED BY

Diane McFadden

HOSPITAL NAME

Newton Vet Hospital

REFERRING VET

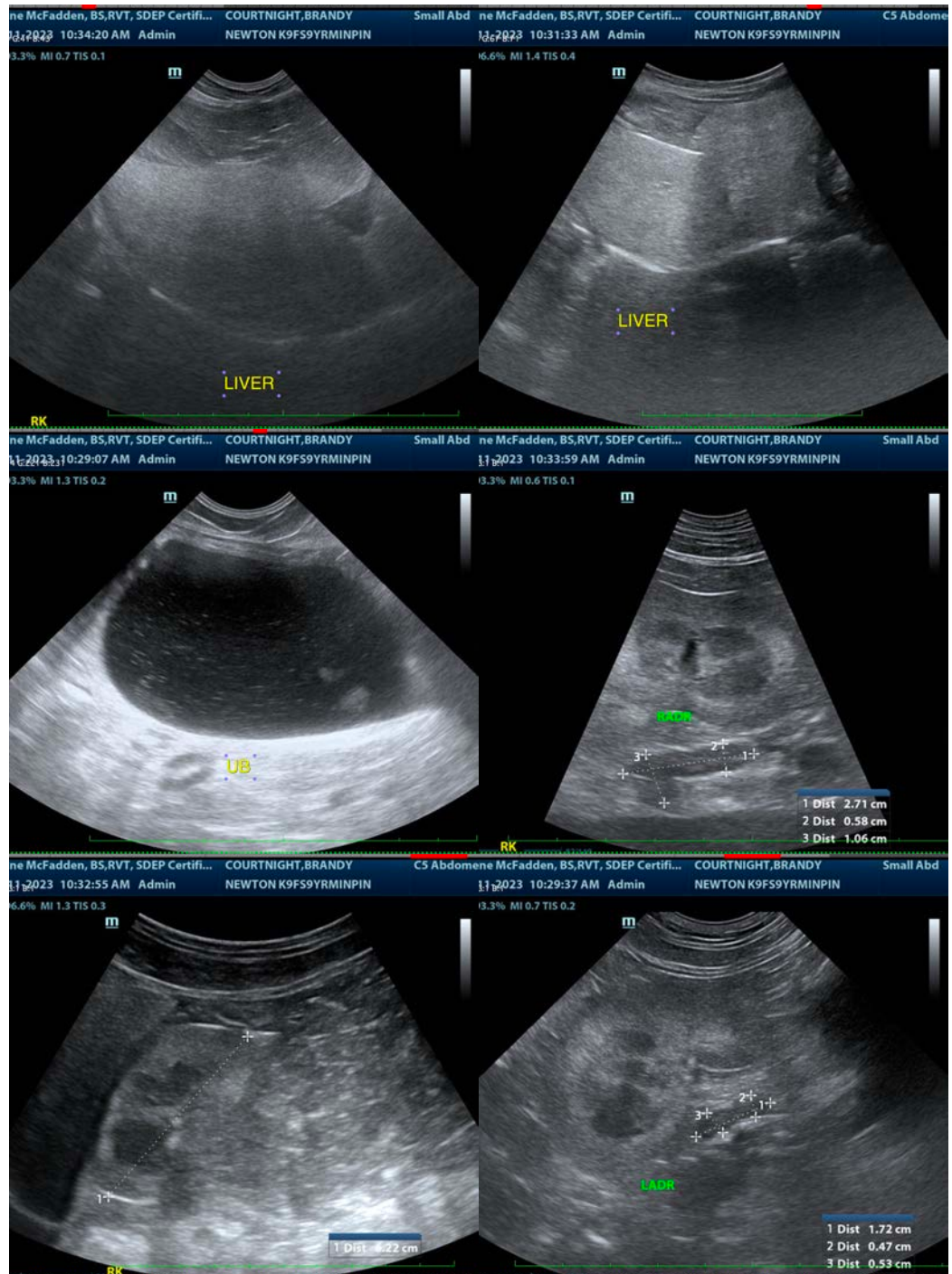
Dr. Barron

INVOICE

44114

DATE

1/11/23





PATIENT

Brandy Courtnight

SPECIES

Canine

BREED

Miniature Pinscher X

SEX

Spayed Female

AGE

9 Years

WEIGHT

52 Pounds

INTERPRETED BY

Beth Johnson, DVM
DACVIM

IMAGING PERFORMED BY

Diane McFadden

HOSPITAL NAME

Newton Vet Hospital

REFERRING VET

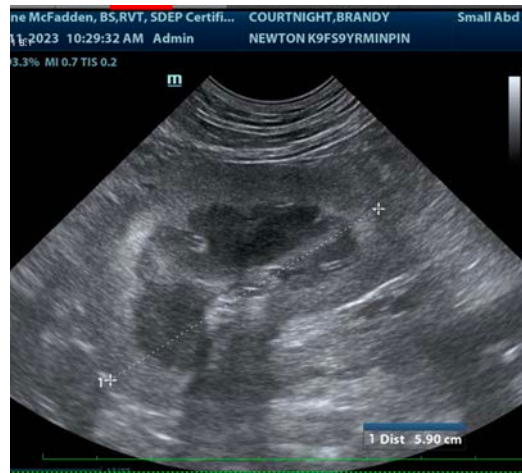Dr. Barron

INVOICE

44114

DATE

1/11/23



The information and recommendations provided are based on the images presented by the referring veterinarian/sonographer. No evaluation can be communicated regarding pathology that was not visible in the image/video clips provided.

Thank you for this referral. If the clinical or image interpretation does not parallel your findings or if I can be of any further assistance please contact me.

Beth Johnson, DVM, DACVIM
Beth.Johnson@sonopath.com