

**DATE PRESENTING CLINICAL SIGNS**

1/10/23 Patient presented for exam November 16, 2022. Right anal gland mass found on exam. Referred to surgeon for evaluation/anal saccullectomy.

PATIENT

Max Grier
Current Medications: Deramaxx 37.5 mg Q 24 hours, Apoquel 24 mg Q12-24 hours
Lab Results: Proteinuria (UPC 1.7)
Date of Previous IntraPet Ultrasound: No previous.

SPECIES

Canine
Sedation: IV Torb.
Stat Report: Not requested.
Imaging Performed By: Rachel Brillhart, RDMS.

BREED

Mix

SEX

Neutered Male

AGE

6/5/11

WEIGHT

107 Pounds

INTERPRETED BY

Beth Johnson, DVM
DACVIM

HOSPITAL NAME

Hickory Vet Hospital

REFERRING VET

Dr. McNesby

INVOICE

44076

ULTRASONOGRAPHIC EXAMINATION OF THE ABDOMEN**Urinary System**

The urinary bladder is moderately distended with anechoic contents. No masses, inflammatory changes, echogenic sediment or cystoliths are observed. The urinary bladder, trigone and visible pelvic urethra are normal in thickness with a smooth mucosal surface.

Prostate is normal in size, echotexture and echogenicity for a neutered male.

The right kidney is normal in size (6.92 cm), shape and echogenicity. It has smooth peripheral margination. There is a normal 1:3 cortex to medulla ratio with appropriate corticomedullary distinction. There is no evidence of pyelectasia, mineral or infarcts observed.

The left kidney is normal in size (7.94 cm), shape and echogenicity. It has smooth peripheral margination. There is a normal 1:3 cortex to medulla ratio with appropriate corticomedullary distinction. There is no evidence of pyelectasia, mineral or infarcts observed.

Adrenal Glands

The left adrenal gland is normal in size (2.89 cm long x 0.68 cm at the cranial pole and 0.65 cm at the caudal pole), shape and contour. Corticomedullary structure is unremarkable. Visible surrounding vasculature appears normal.

The right adrenal gland is normal in size (2.87 cm long x 1.3 cm at the cranial pole and 0.89 cm at the caudal pole), shape and contour. Corticomedullary structure is unremarkable. Visible surrounding vasculature appears normal.

Spleen

The spleen is subjectively normal in size with a normal smooth capsular contour. Parenchyma is appropriately finely textured and homogenous with normal echogenicity relative to surrounding tissue (hyperechoic to liver). No focal nodules or masses are observed. Splenic vasculature appears normal.

Liver

The liver is subjectively normal in size with normal smooth curvilinear peripheral contour. Parenchyma is appropriately hypoechoic to the spleen in echogenicity and appropriately mildly coarse and homogenous in echotexture. An approximately 1.0 cm discrete hyperechoic nodule is noted in the caudal liver. Visible vasculature and biliary tree appear normal without distension or congestion.

The gallbladder is non-distended in size. The wall is smooth without visible thickening. Luminal contents are primarily anechoic. There is no evidence of cystic or common bile duct dilation.

Gastrointestinal

The stomach wall is normal in thickness (canine < 0.5 cm and feline < 0.4 cm) and layering. The lumen of the stomach is empty with no evidence of obstruction, foreign material or infiltrative disease. Pyloric outflow tract appears patent.

The visible small intestines are normal in wall thickness and layering (canine duodenum < 0.5 cm and feline duodenum < 0.4 cm; other < 0.3 cm). Small intestinal motility appears adequate (1-3 contractions per min). The lumen of the small intestine is empty with no evidence of obstruction, foreign material or infiltrative disease.

The visible colon is normal in wall thickness (< 0.2 cm) and layering. Contents are consistent with normal formed feces and gas.

Pancreas

The observed pancreas appears appropriately isoechoic to surrounding omental fat. The capsule is mildly irregular in shape. Parenchyma is mildly heterogenous and coarse. There is no visible pancreatic duct dilation. There is no evidence of active peripancreatic inflammation.

Free Abdomen

There is no evidence of free peritoneal effusion noted in these images.

There is a small sublumbar lymph node visualized that measures 0.50 cm thick.

In the right anal gland, there is a focal heterogeneous, 0.70 cm x 1.2 cm nodule. The left anal gland is visualized with no evident pathology visualized.

PRIMARY FINDINGS

- **Right anal gland nodule** – consistent with this patient’s reported physical exam findings.
- **Very mild sublumbar lymphadenopathy** – most consistent with a reactive lymph node. Metastatic neoplasia can’t be ruled out without tissue sampling but is considered less likely.
- **Liver nodule** – Differentials for a discrete liver nodule include primarily benign changes such as nodular hyperplasia, fibrosis of an old hematoma, granuloma, myelolipoma, etc.; however, while considered less likely, primary hepatic neoplasia, infiltrative round cell neoplasia and metastatic disease can mimic benign lesions and cannot be definitively ruled out.

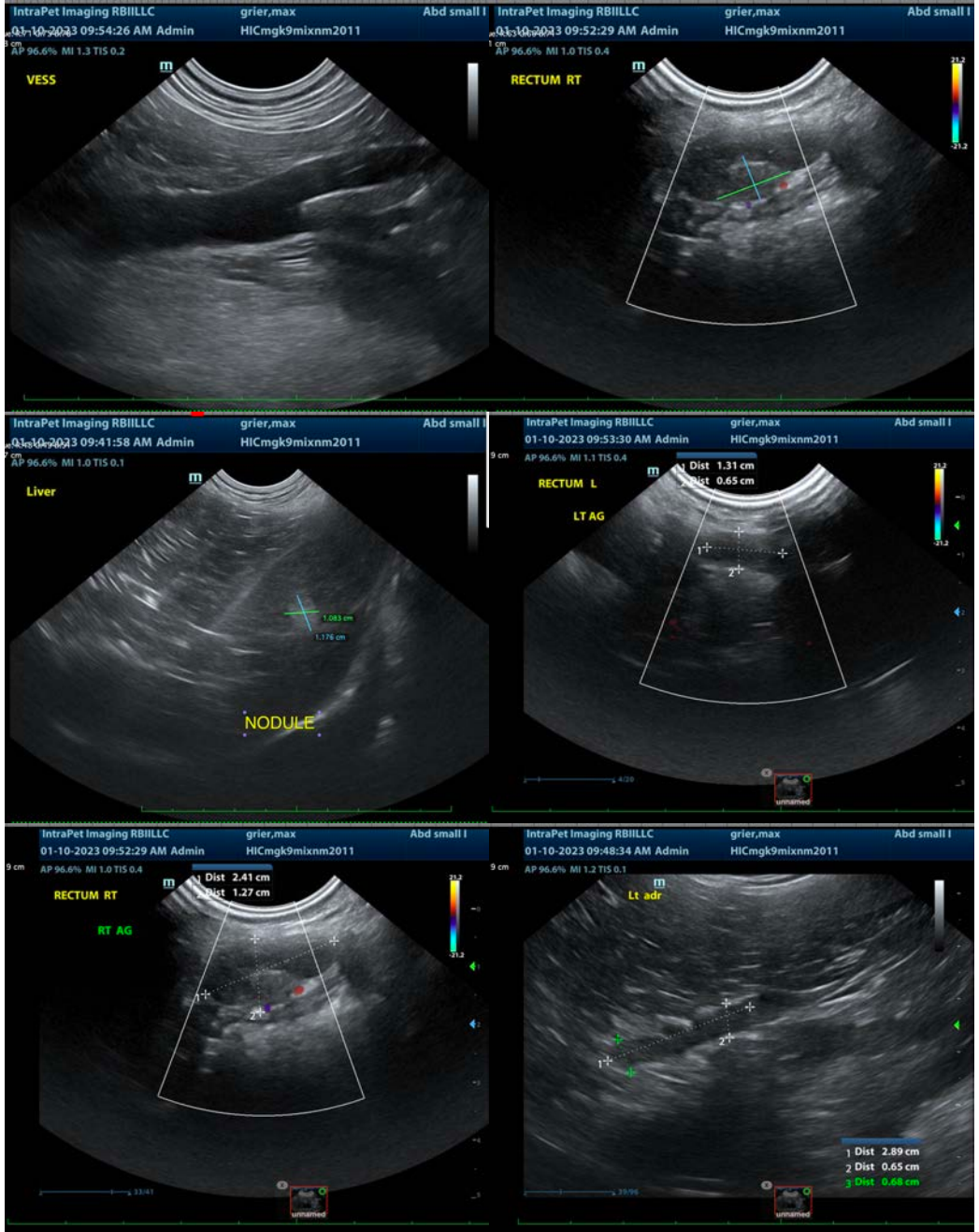
SECONDARY FINDINGS

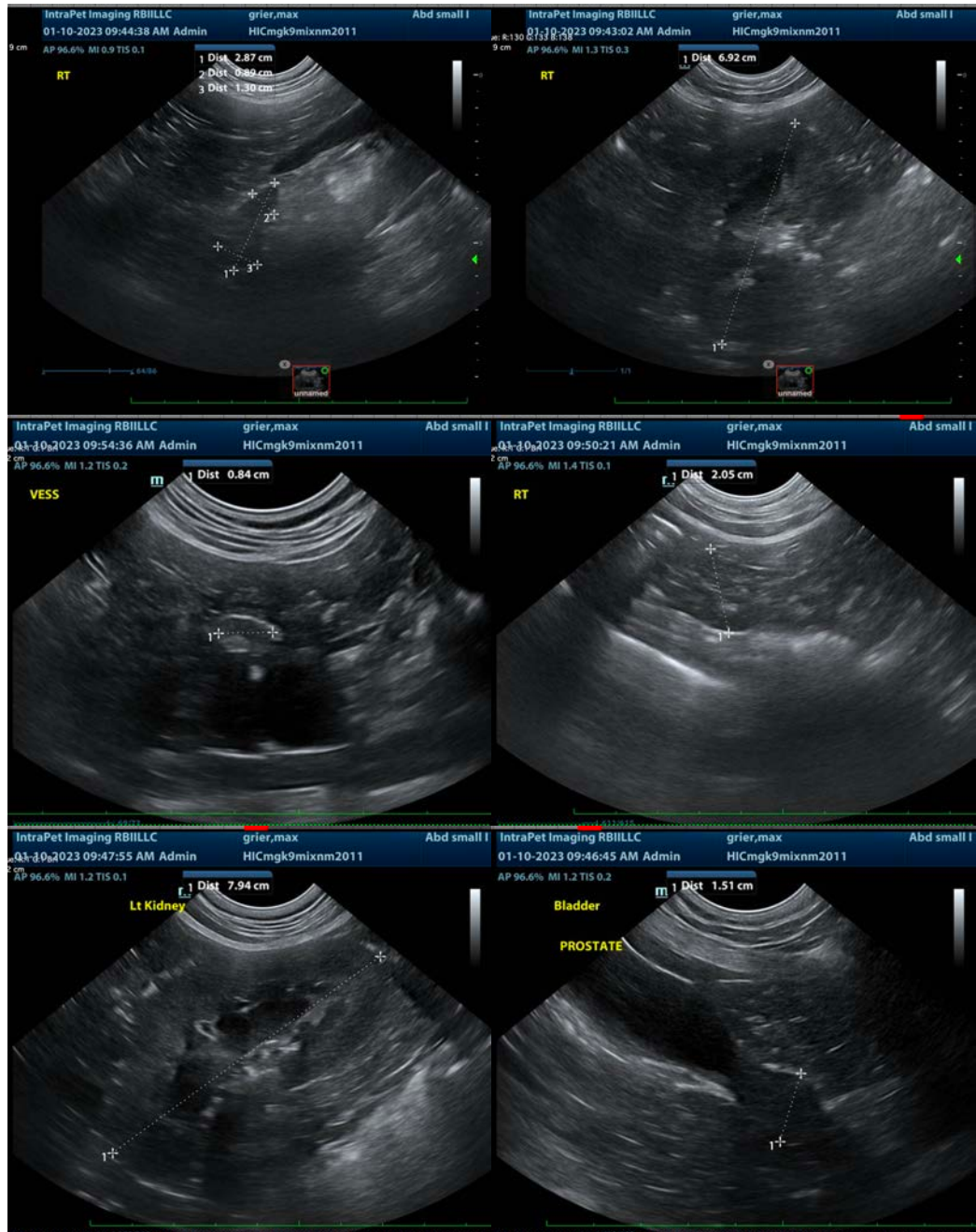
- **Pancreatic age-related remodeling** – Mild irregularities are consistent with benign age-related change. Low-grade smoldering chronic pancreatitis cannot be ruled out and should be suspected in the face of appropriate clinical signs.

INTERPRETATION OF THE FINDINGS & FURTHER RECOMMENDATIONS

Three view thoracic radiographs are recommended for further assessment of cardio-pulmonary status as well as to further evaluate for any evidence of metastatic disease, if not recently evaluated.

Surgery for anal gland removal and submission of nodule for histopath is recommended, as is reportedly already planned, followed by consultation with a veterinary oncologist if the diagnosis warrants it. Follow up imaging of the sublumbar area to monitor the described mild lymphadenopathy could be considered post-op as treatment/chemotherapy continues, if indicated.





The information and recommendations provided are based on the images presented by the referring veterinarian/sonographer. No evaluation can be communicated regarding pathology that was not visible in the image/video clips provided.

Thank you for this referral. If the clinical or image interpretation does not parallel your findings or if I can be of any further assistance please contact me.

Beth Johnson, DVM, DACVIM
Beth.Johnson@sonopath.com