



PATIENT	PRESENTING CLINICAL SIGNS
Izzy Zill	Splenic mass- non surgical 9/22 Vomited/weak last night, has been overall doing great Abnormal PE/Chem/CBC/UA Results: Pale, slightly dehydrated
SPECIES	ULTRASONOGRAPHIC EXAMINATION OF THE ABDOMEN
Canine	Urinary System
BREED	Urinary bladder is adequately distended. It has a normal uniform wall thickness. Contents include primarily anechoic fluid with occasional echogenic non-shadowing debris, most consistent with exfoliated cells, mucous and/or small blood clots. Both sterile inflammation as well as urinary tract infection can also present with echogenic debris. No masses observed. A small, non-shadowing cystoliths can't be ruled out. The trigone and visible pelvic urethra are normal in thickness with a smooth mucosal surface.
Mixed	
SEX	Kidneys are overall normal in size and shape with smooth peripheral margination. A normal 1:3 cortex to medulla ratio is maintained. The medulla and cortices are uniform in texture with some mild increased cortical echogenicity and mild loss of corticomedullary distinction, expected in this age patient. There is no evidence of pyelectasia, mineral or infarcts observed. A cortical cyst was noted in the right kidney. The right kidney measures 6.13 cm. The left kidney measures 5.51 cm.
Spayed Female	
AGE	Adrenal Glands
11 Years	The adrenal glands are not able to be well visualized in these images.
WEIGHT	Spleen
32 Pounds	The reveals a large, approximately 8.0 cm in diameter, markedly heterogeneous, cavitated mass that disrupts the splenic capsule. A scant amount of anechoic free fluid and heterogeneous regional lymphadenopathy are also noted. Splenic vasculature appears normal.
INTERPRETED BY	Liver
Beth Johnson, DVM DACVIM	The liver is subjectively normal in size with normal smooth curvilinear peripheral contour. Parenchyma is appropriately hypoechoic to the spleen in echogenicity and appropriately mildly coarse and homogenous in echotexture. In the caudal left liver, there is an approximately 2.0 cm in diameter, slightly heterogeneous nodule. Visible vasculature and biliary tree appear normal without distension or congestion.
IMAGING PERFORMED BY	Gallbladder
Chelsea Pastor	Gallbladder is moderately distended with anechoic bile as well as mild suspended and gravity dependent echogenic debris. The wall is smooth without visible thickening. There is no evidence of cystic or CBD dilation. There is no evidence of effusion or inflammation.
HOSPITAL NAME	Gastrointestinal
Fredon Animal Hospital	The stomach wall is normal in thickness (canine < 0.5 cm and feline < 0.4 cm) and layering. The lumen of the stomach is empty with no evidence of obstruction, foreign material or infiltrative disease. Pyloric outflow tract appears patent.
REFERRING VET	INVOICE
Dr. Linda Grau	44081
	DATE
	1/10/23



PATIENT

Izzy Zill

The visible colon is normal in wall thickness (< 0.2 cm) and layering. Contents are consistent with normal formed feces and gas.

Pancreas

SPECIES

Canine

The pancreatic parenchyma is appropriately isoechoic to surrounding tissue. Visible capsule is smooth and normal in contour. There is no visible pancreatic duct dilation. There is no evidence of active peripancreatic inflammation.

BREED

Mixed

Free Abdomen

**See spleen.

SEX

Spayed Female

- **Heterogeneous, cavitated splenic mass that has progressed in size since the previous ultrasound** - Given the regional lymphadenopathy and free fluid, this is most concerning for infiltrative neoplasia such as sarcoma versus other.

AGE

11 Years

- **Heterogeneous liver nodule** - This could represent a metastatic lesion. However, benign lesions can mimic metastatic lesions and cannot be differentiated without tissue sampling.

SECONDARY FINDINGS

WEIGHT

32 Pounds

- Urinary bladder debris
- **Mild gallbladder debris** - Cholecystic debris is of unknown clinical significance. It can be seen with biliary stasis from fasting or illness. Cholecystic debris is not necessarily related to hepatobiliary disease. Echogenic bile is most commonly an incidental finding in dogs and should be interpreted in combination with clinical signs such as nausea, inappetence, cranial abdominal discomfort and/or laboratory changes such as increased ALP and/or increased Tbili.
- Age related kidney changes with a cortical cyst in the right kidney

INTERPRETED BY

Beth Johnson, DVM
DACVIM

INTERPRETATION OF THE FINDINGS & FURTHER RECOMMENDATIONS

IMAGING PERFORMED BY

Chelsea Pastor

Three view thoracic radiographs are recommended for further assessment of cardio-pulmonary status as well as to further evaluate for any evidence of metastatic disease, if not recently evaluated.

HOSPITAL NAME

Fredon Animal Hospital

An echocardiogram is also recommended for further evaluation of the heart base for metastatic lesions.

REFERRING VET

Dr. Linda Grau

Given this patient's recent episode of weakness and paleness, hemorrhage into the abdomen (given the free fluid) or even into the center of the mass is considered probable. Therefore, recommendations to prevent further hemorrhage include an exploratory laparotomy with planned splenectomy and liver nodules/lymph node biopsy.

Full excision of all of the visibly evident disease may or may not be feasible, but surgery would remove the immediate suspected source of hemorrhage as a palliative approach.

INVOICE

44081

DATE

1/10/23



PATIENT

Izzy Zill

SPECIES

Canine

BREED

Mixed

SEX

Spayed Female

AGE

11 Years

WEIGHT

32 Pounds

INTERPRETED BY

Beth Johnson, DVM
DACVIM

IMAGING PERFORMED BY

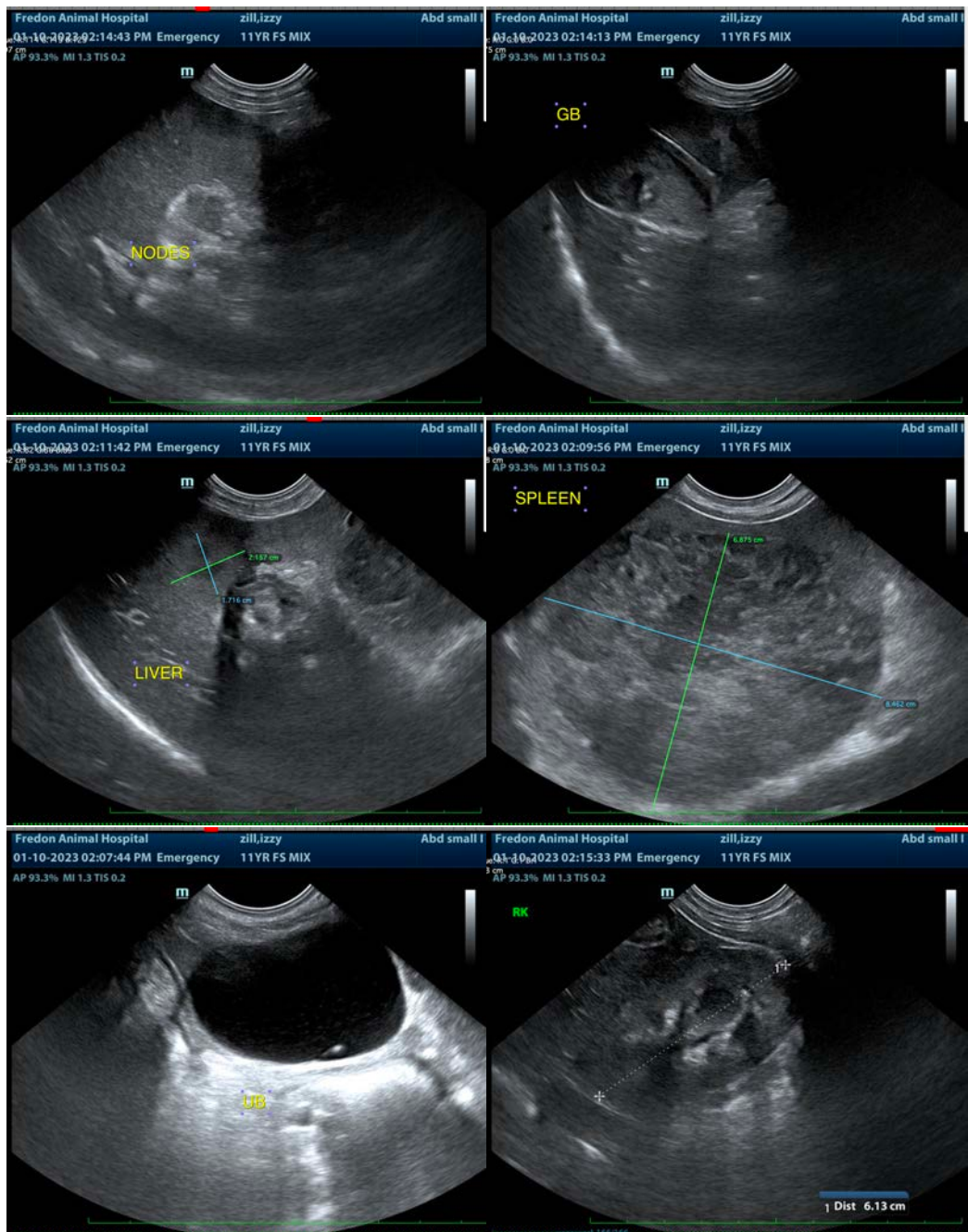
Chelsea Pastor

HOSPITAL NAME

Fredon Animal Hospital

REFERRING VET

Dr. Linda Grau



INVOICE

44081

DATE

1/10/23



PATIENT

Izzy Zill

SPECIES

Canine

BREED

Mixed

SEX

Spayed Female

AGE

11 Years

WEIGHT

32 Pounds

INTERPRETED BY

Beth Johnson, DVM
DACVIM

**IMAGING
PERFORMED BY**

Chelsea Pastor

HOSPITAL NAME

Fredon Animal
Hospital

REFERRING VET

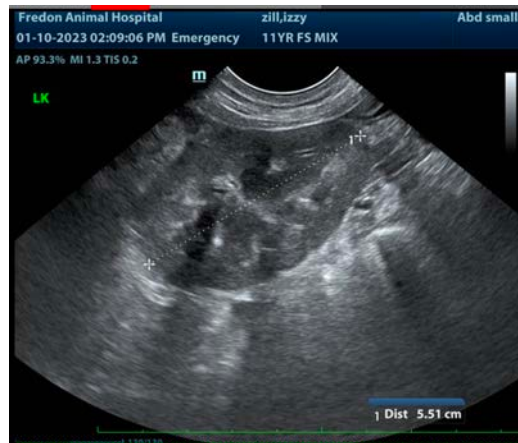Dr. Linda Grau

INVOICE

44081

DATE

1/10/23



The information and recommendations provided are based on the images presented by the referring veterinarian/sonographer. No evaluation can be communicated regarding pathology that was not visible in the image/video clips provided.

Thank you for this referral. If the clinical or image interpretation does not parallel your findings or if I can be of any further assistance please contact me.

Beth Johnson, DVM, DACVIM
Beth.Johnson@sonopath.com