



PATIENT PRESENTING CLINICAL SIGNS

Daphne Russell PU/PD for several months. Elevated Alk Phos profile Oct. 10. urine culture neg. UA not concentrated Cushings test LDDST normal. Ultrasound recommended. Owner wanted to wait until after the holidays. Owner made appointment for profile recheck and possible dental.

SPECIES

Canine Abnormal PE/Chem/CBC/UA Results: Px. grade 4/4 dental disease. chem profile BUN 49, Ct 1.5, P 5.7, Ca 12.4, ALT 583, Alk phos > 993, GGT 18. CBC WNL. Pet is still Pu/PD Dental not performed. ultrasound instead.

BREED

Min Pin X

ULTRASONOGRAPHIC EXAMINATION OF THE ABDOMEN

Urinary System

SEX

Spayed Female Urinary bladder is adequately distended. It has a normal uniform wall thickness. Contents include primarily anechoic fluid with a large amount of echogenic non-shadowing debris, both suspended and gravity dependent, most consistent with exfoliated cells, mucous and/or small blood clots. Both sterile inflammation as well as urinary tract infection can also present with echogenic debris. No masses or cystoliths are observed. The trigone and visible pelvic urethra are normal in thickness with a smooth mucosal surface.

AGE

10 Years

The right kidney is normal in size (5.6 cm), shape and echogenicity. Mild pyelectasia noted. It has smooth peripheral margination. There is a normal 1:3 cortex to medulla ratio with appropriate corticomedullary distinction. There is no evidence of mineral or infarcts observed.

WEIGHT

27 Pounds

The left kidney is normal in size (5.2 cm), shape and echogenicity. Mild pyelectasia noted. It has smooth peripheral margination. There is a normal 1:3 cortex to medulla ratio with appropriate corticomedullary distinction. There is no evidence of mineral or infarcts observed.

INTERPRETED BY

Adrenal Glands

Beth Johnson, DVM
DACVIM

The area of the right adrenal gland is examined without evident adrenal gland pathology, but the adrenal gland is not definitively visualized.

IMAGING PERFORMED BY

The caudal pole of the left adrenal gland is visualized and normal in appearance, measuring 0.36 cm. The cranial pole of the left adrenal is not well visualized.

Dr. Logas

Spleen

HOSPITAL NAME

Bradentown VH

The spleen is subjectively normal in size with a normal smooth capsular contour. Parenchyma is appropriately finely textured and homogenous with normal echogenicity relative to surrounding tissue (hyperechoic to liver). No focal nodules or masses are observed. Splenic vasculature appears normal.

REFERRING VET

Liver

Dr. Logas

The liver is subjectively enlarged in size with mildly irregular margins. Parenchyma is heterogeneous, characterized by multiple poorly defined, hypoechoic nodules within an otherwise hyperechoic liver parenchyma. Additionally, multifocal discrete hyperechoic nodules of varying sizes are noted. Visible vasculature and biliary tree appear normal without distension or congestion.

INVOICE

44095

Gallbladder is moderately distended with anechoic bile as well as mild suspended and gravity dependent echogenic debris. There are several discrete round, non-shadowing densities that may represent non-shadowing cholecystoliths. The wall is smooth without visible thickening. There is no evidence of cystic or CBD dilation. There is no evidence of effusion or inflammation.

DATE

1/10/23



PATIENT

Daphne Russell

SPECIES

Canine

BREED

Min Pin X

SEX

Spayed Female

AGE

10 Years

WEIGHT

27 Pounds

INTERPRETED BY

Beth Johnson, DVM
DACVIM

IMAGING PERFORMED BY

Dr. Logas

HOSPITAL NAME

Bradentown VH

REFERRING VET

Dr. Logas

INVOICE

44095

DATE

1/10/23

Gastrointestinal

The stomach wall is normal in thickness (canine < 0.5 cm and feline < 0.4 cm) and layering. The lumen of the stomach is empty with no evidence of obstruction, foreign material or infiltrative disease. Pyloric outflow tract appears patent.

The visible small intestines are normal in wall thickness and layering (canine duodenum < 0.5 cm and feline duodenum < 0.4 cm; other < 0.3 cm). Small intestinal motility appears adequate (1-3 contractions per min). The lumen of the small intestine is empty with no evidence of obstruction, foreign material or infiltrative disease.

The visible colon is normal in wall thickness (< 0.2 cm) and layering. Contents are consistent with normal formed feces and gas.

Pancreas

The pancreatic parenchyma is appropriately isoechoic to surrounding tissue. Visible capsule is smooth and normal in contour. There is no visible pancreatic duct dilation. There is no evidence of active peripancreatic inflammation.

Free Abdomen

There is no evidence of free peritoneal effusion noted in these images.

There is no apparent lymphadenopathy noted in these images.

PRIMARY FINDINGS

- **Heterogenous Liver** – These changes are most consistent with benign processes such as nodular hyperplasia, steroid (vacuolar) hepatopathy, extramedullary hematopoiesis or possibly chronic inflammatory disease and less commonly infiltrative round cell or metastatic neoplasia.
- **Liver nodules** – Differentials for a discrete liver nodules include primarily benign changes such as nodular hyperplasia, fibrosis of an old hematoma, granuloma, myelolipoma, etc.; however, while considered less likely, primary hepatic neoplasia, infiltrative round cell neoplasia and metastatic disease can mimic benign lesions and cannot be definitively ruled out.
- **Mild gallbladder debris** - Cholecystic debris is of unknown clinical significance. It can be seen with biliary stasis from fasting or illness. Cholecystic debris is not necessarily related to hepatobiliary disease. Echogenic bile is most commonly an incidental finding in dogs and should be interpreted in combination with clinical signs such as nausea, inappetence, cranial abdominal discomfort and/or laboratory changes such as increased ALP and/or increased Tbili. Non-shadowing cholecystoliths, non-obstructive, cannot be ruled out.
- **Mild bilateral pyelectasia** – Differentials for pyelectasia include pyelonephritis, diuresis, congenital malformation or ureteral or lower urinary tract obstruction.

SECONDARY FINDINGS

- Urinary bladder debris



PATIENT

Daphne Russell

SPECIES

Canine

BREED

Min Pin X

SEX

Spayed Female

AGE

10 Years

WEIGHT

27 Pounds

INTERPRETED BY

Beth Johnson, DVM
DACVIM

IMAGING PERFORMED BY

Dr. Logas

HOSPITAL NAME

Bradentown VH

REFERRING VET

Dr. Logas

INVOICE

44095

DATE

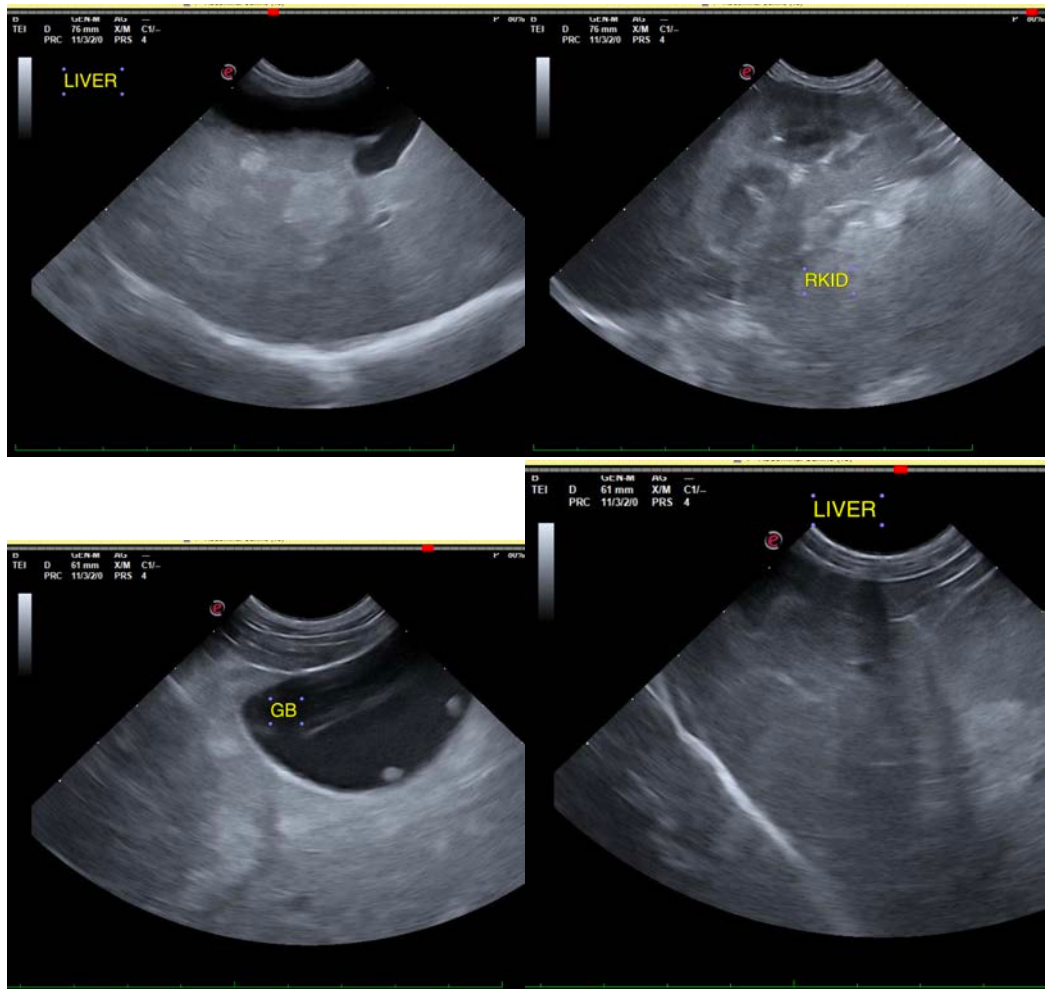
1/10/23

INTERPRETATION OF THE FINDINGS & FURTHER RECOMMENDATIONS

This patient's pyelectasia may be secondary to the reported PU/PD, but given the concurrent urinary bladder debris, a recheck urine culture may be warranted.

Given the recent development of hypercalcemia, further evaluation via a malignancy panel to include PTH, PTHrP, and ionized calcium is recommended.

In the meantime, thorough evaluation of peripheral lymph nodes, a rectal exam to assess anal glands, etc. is recommended to look for a type of neoplasia that commonly results in hypercalcemia. If physical exam is normal, and the malignancy panel suggests hypercalcemia of malignancy, a fine needle aspirate of the liver is recommended if patient's coagulation status is appropriate. The appearance of the liver nodules trend in appearance toward benign, but a fine needle aspirate could be considered regardless.





PATIENT

Daphne Russell

SPECIES

Canine

BREED

Min Pin X

SEX

Spayed Female

AGE

10 Years

WEIGHT

27 Pounds

INTERPRETED BY

Beth Johnson, DVM
DACVIM

IMAGING PERFORMED BY

Dr. Logas

HOSPITAL NAME

Bradentown VH

REFERRING VET

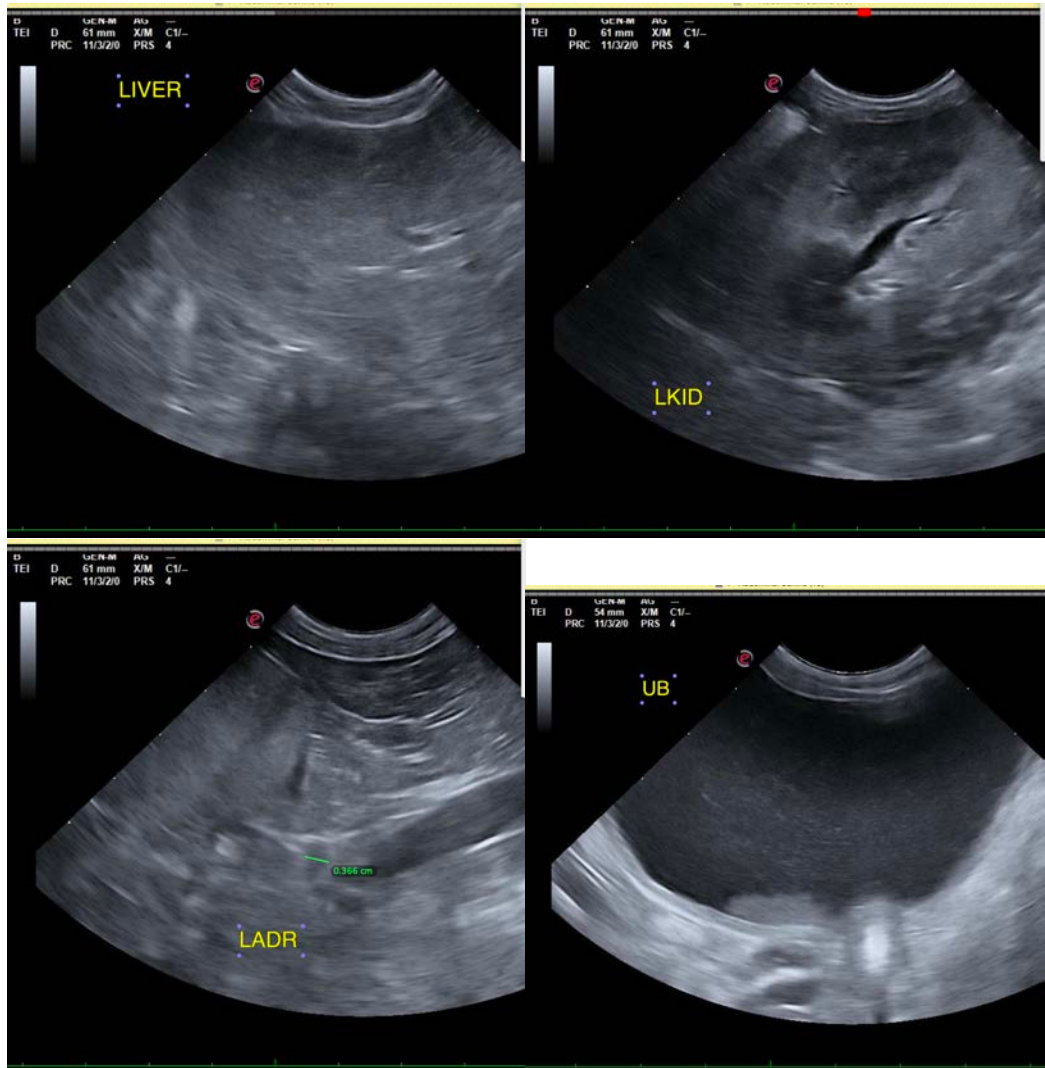
Dr. Logas

INVOICE

44095

DATE

1/10/23



The information and recommendations provided are based on the images presented by the referring veterinarian/sonographer. No evaluation can be communicated regarding pathology that was not visible in the image/video clips provided.

Thank you for this referral. If the clinical or image interpretation does not parallel your findings or if I can be of any further assistance please contact me.

Beth Johnson, DVM, DACVIM
Beth.Johnson@sonopath.com