

**DATE PRESENTING CLINICAL SIGNS**

1/10/23

Last Wednesday (12/28) P vomited, had dental treat that came up, after that slept and wouldn't eat. Did not eat Wednesday or Thursday. Ate chicken and rice Friday, vomited a tiny bit of that Friday night. Has not vomited since Saturday. Did eat a few tablespoons of canned pumpkin. Has not ate her dog food since Wednesday, only chicken, rice, pumpkin. Did have normal bowel movement today. Has been drinking water whole time. No new treats or food, but does give a variety of treats. Last vomited 4 days. normal stools. No medications. no known chronic conditions. P has been vaccinated for leptospirosis. PE findings. P is icteric. Consider prehepatic, hepatic and post hepatic bilirubinemia. Painful abd

PATIENT

Bailey Bova

SPECIES

Canine

BREED

Mixed Breed

SEX

Spayed Female

AGE

7/3/14

WEIGHT

41.1 Pounds

INTERPRETED BYBeth Johnson, DVM
DACVIM**HOSPITAL NAME**

Warm & Fuzzy VC

REFERRING VET

Dr. Hepner

INVOICE

44085

Current Medications: Probiotic and joint chew. Entyce 1.8mL SID PRN started 1/3/23
 Lab Results: cbc within normal limits - normal RBC and hemoglobin to RO prehepatic icterus.. chem: ALT and ALKP too high to read initially. GGT 51, tBili 10.7, Cholesterol H 444. Alb, cholesterol and glucose all within normal limits so liver products appropriate. After 1:10 dilution, ALT 2543, ALK 4019. electrolytes: within normal limits
 Radiographs: hepatomegaly with no obvious masses, no obvious free fluid
 Date of Previous IntraPet Ultrasound: No previous.
 Sedation: Not required to complete full diagnostic ultrasound.
 Stat Report: Not requested.
 Imaging Performed By: Rachel Brillhart, RDMS.

ULTRASONOGRAPHIC EXAMINATION OF THE ABDOMEN**Urinary System**

The urinary bladder is moderately distended with anechoic contents. No masses, inflammatory changes, echogenic sediment or cystoliths are observed. The urinary bladder, trigone and visible pelvic urethra are normal in thickness with a smooth mucosal surface.

The right kidney is normal in size (5.5 cm), shape and echogenicity. It has smooth peripheral margination. There is a normal 1:3 cortex to medulla ratio with appropriate corticomedullary distinction. There is no evidence of pyelectasia, mineral or infarcts observed.

The left kidney is normal in size (5.98 cm), shape and echogenicity. It has smooth peripheral margination. There is a normal 1:3 cortex to medulla ratio with appropriate corticomedullary distinction. There is no evidence of pyelectasia, mineral or infarcts observed.

Adrenal Glands

The right adrenal gland is normal in size (2.97 cm long x 0.92 cm at the cranial pole and 0.70 cm at the caudal pole), shape and contour. Corticomedullary structure is unremarkable. Visible surrounding vasculature appears normal.

The left adrenal gland is normal in size (2.34 cm long x 0.67 cm at the cranial pole and 0.67 cm at the caudal pole), shape and contour. Corticomedullary structure is unremarkable. Visible surrounding vasculature appears normal.

Spleen

The spleen is subjectively normal in size with a normal smooth capsular contour. Parenchyma is appropriately finely textured and homogenous with normal echogenicity relative to surrounding tissue (hyperechoic to liver). No focal nodules or masses are observed. Splenic vasculature appears normal.

Liver

Liver is subjectively enlarged with mildly irregular margins. Parenchyma is heterogenous characterized by multiple poorly defined hypoechoic nodules within otherwise hyperechoic liver parenchyma. Visible vasculature and biliary tree appear normal without distension or congestion.

The gallbladder is non-distended in size. The wall is smooth without visible thickening. Luminal contents are primarily anechoic. The common bile duct is mildly distended, measuring 0.44 cm.

Gastrointestinal

The stomach wall is normal in thickness (canine < 0.5 cm and feline < 0.4 cm) and layering. The lumen of the stomach is empty with no evidence of obstruction, foreign material or infiltrative disease. Pyloric outflow tract appears patent.

The visible small intestines are normal in wall thickness and layering (canine duodenum < 0.5 cm and feline duodenum < 0.4 cm; other < 0.3 cm). Small intestinal motility appears adequate (1-3 contractions per min). The lumen of the small intestine is empty with no evidence of obstruction, foreign material or infiltrative disease.

The visible colon is normal in wall thickness (< 0.2 cm) and layering. Contents are consistent with normal formed feces and gas.

Pancreas

The observed pancreas is prominent (enlarged) in size, hypoechoic to surrounding tissue and irregular in shape with a swollen undulating contour. Enhanced hyperechoic ill-defined surrounding fat is noted.

Free Abdomen

There is no evidence of free peritoneal effusion noted in these images.

There is no apparent lymphadenopathy noted in these images.

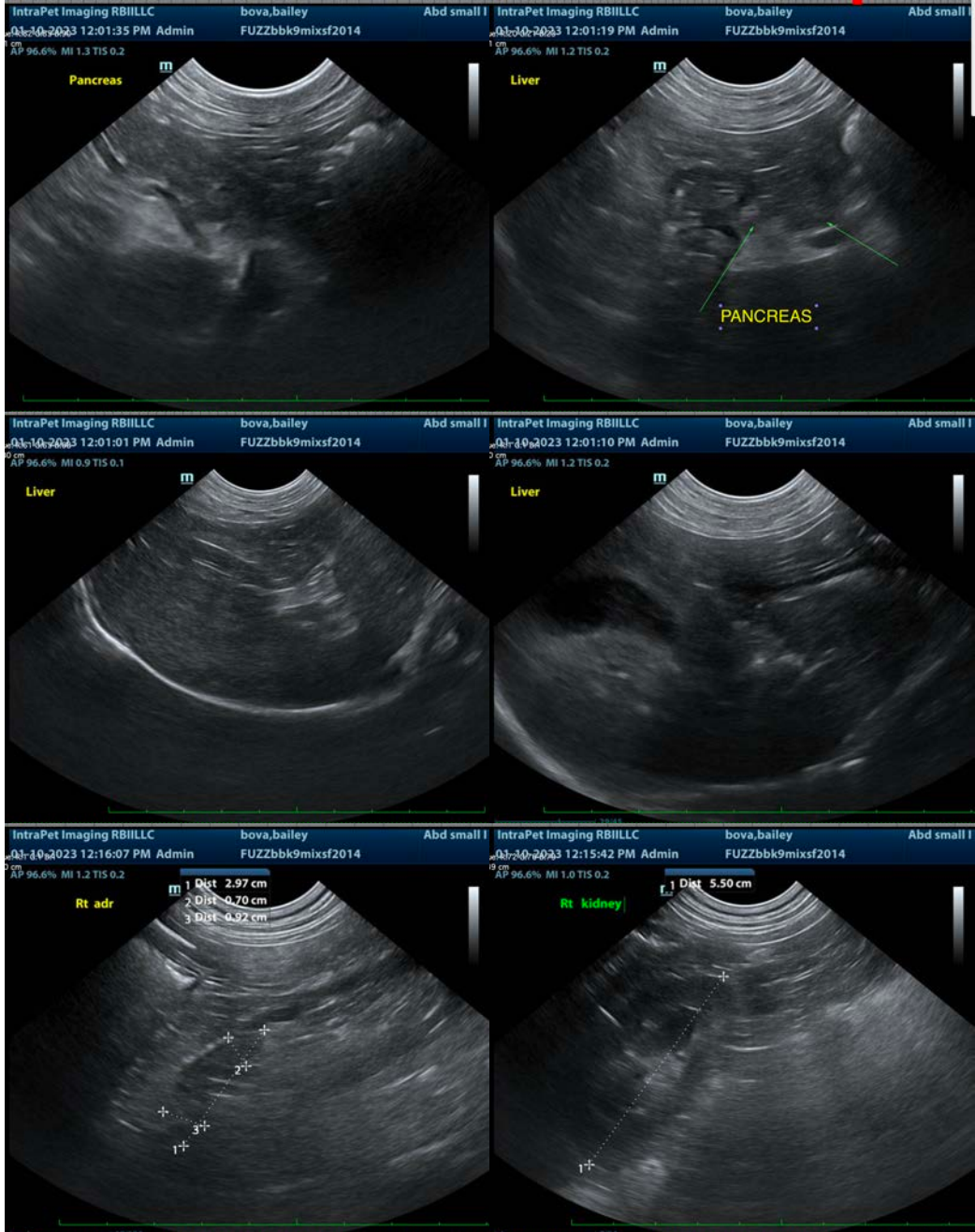
ULTRASONOGRAPHIC FINDINGS

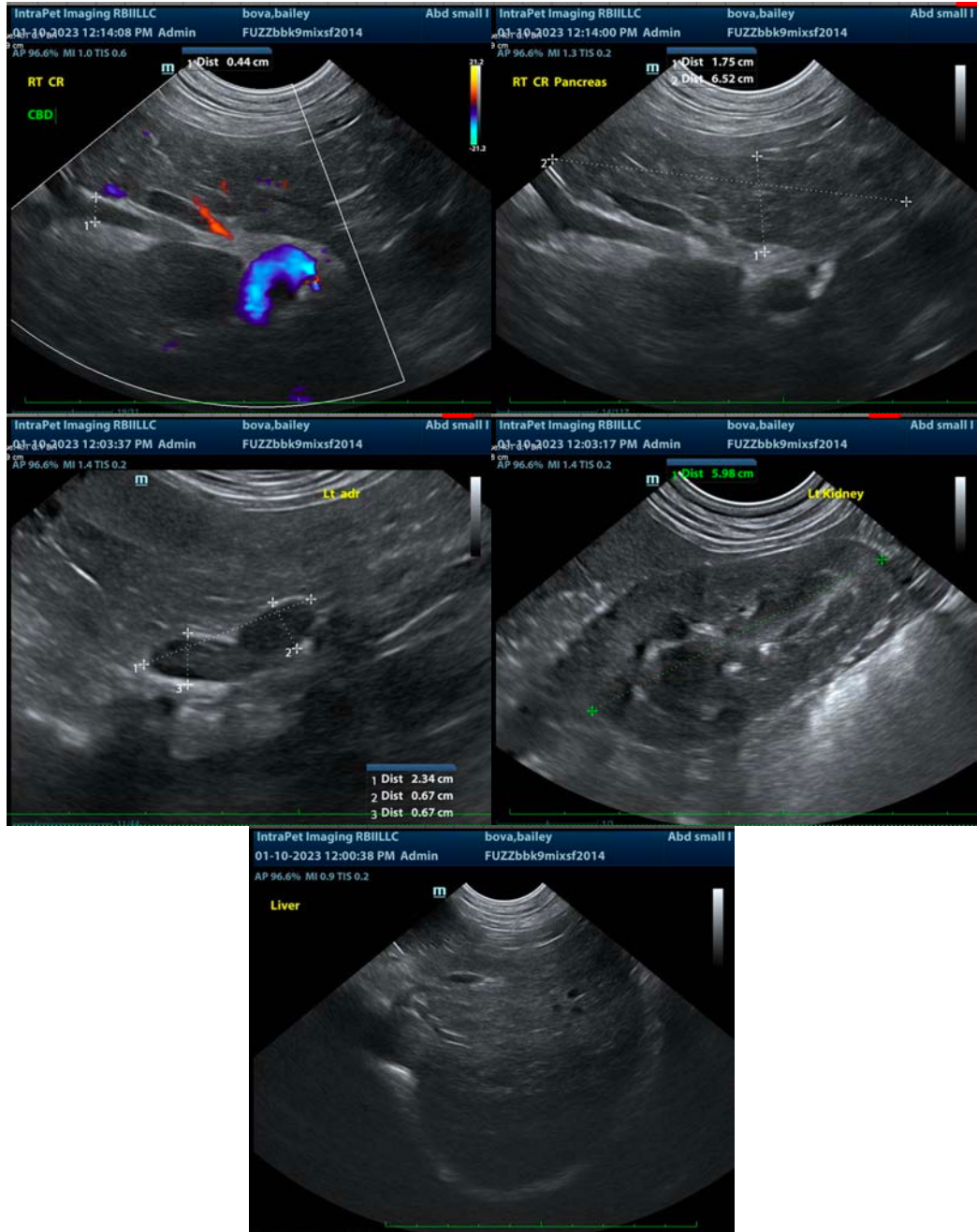
- **Acute pancreatitis with mild common bile duct distention** – consistent with post-hepatic cholestasis, likely secondary to the pancreatitis.
- **Heterogenous Liver** – These changes are most consistent with benign processes such as nodular hyperplasia, steroid (vacuolar) hepatopathy, extramedullary hematopoiesis or possibly chronic inflammatory disease and less commonly infiltrative round cell or metastatic neoplasia.

INTERPRETATION OF THE FINDINGS & FURTHER RECOMMENDATIONS

A quantitative PLI is recommended if not recently evaluated, followed by medical management of pancreatitis with anti-emetics, gastroprotectants, appetite stimulants or nutritional support as needed, pain management, broad spectrum antibiotics, and fluid therapy. If possible, a fresh frozen plasma transfusion and hyperbaric oxygen therapy (HBOT) could be beneficial. Monitoring of the pancreas with power doppler is recommended to identify possible necrosis as well as other potential sequelae such as abscesses, etc.

If the post-hepatic cholestasis/obstruction does not resolve and/or progresses, surgical intervention may be required. If there is disease progression and surgery is not an option for any reason, Sildenafil could be tried empirically.





The information and recommendations provided are based on the images presented by the referring veterinarian/sonographer. No evaluation can be communicated regarding pathology that was not visible in the image/video clips provided.

Thank you for this referral. If the clinical or image interpretation does not parallel your findings or if I can be of any further assistance please contact me.

Beth Johnson, DVM, DACVIM
Beth.Johnson@sonopath.com