



**PATIENT**

Wednesday Stellar

**SPECIES**

Feline

**BREED**

Domestic Shorthair

**SEX**

Spayed female

**AGE**

8 years

**WEIGHT**

8.5 lbs

**INTERPRETED BY**

Bradley Harris, DVM,  
 DACVECC, DACVIM  
 (cardiology)

**IMAGING PERFORMED BY**

Rebecca Hamilton

**HOSPITAL NAME**

Kingston AH

**REFERRING VET**

Dr. Turner

**INVOICE**

78014

**DATE**

5/27/26

**PRESENTING CLINICAL SIGNS**

History: Inc. proBNP on BW. Planning to do dental, want to make sure safe for anesthesia. normal heart sounds, dental disease.

Abnormal PE/Chem/CBC/UA Results: 2/3/26 proBNP high normal (99) 5/13/26 proBNP ^ (126)

**ULTRASONOGRAPHIC EXAMINATION OF THE HEART**

The left atrium is normal in dimension. There are no distinct left atrial thrombi/clots or spontaneous echo contrast appreciated. The left ventricle is normal in dimension as well as wall thickness, and no evidence of restriction. Left ventricular systolic function is normal, with adequate contractility. The right atrium and ventricle are subjectively normal in dimension and systolic function. The anterior and posterior mitral and tricuspid valve leaflets presented normal linear structure, extension in systole, and union in diastole without regurgitation. There is no evidence of systolic anterior mitral valve motion documented. The left ventricular outflow tract demonstrated normal laminar flow and subjective structural valvular integrity. The visible aorta is unremarkable. Pulmonary outflow tract assessment revealed normal valve structure, laminar flow, and appropriate diameter and distensibility. There is no evidence of pulmonary hypertension documented. There is no visible pericardial, pleural, or free peritoneal fluid noted.

FELINE CARDIAC PARAMETERS	BODY WEIGHT (kg)	HR (BPM)	IVSd (cm)	LVIDd (cm)	LVWd (cm)	FS (%)	EF (%)
NORMAL PARAMETER	-----	150-240	0.3-0.6	1.0-2.1	0.25-0.6	35-67	80-100
PATIENT	3.86 kg	200	0.43	1.36	0.41	63	93
FELINE CARDIAC PARAMETERS	LA/AO (M-mode)	LA/AO HEART BASE (Sisson)	LAD LA MAX 4 Chamber		LVOT VEL. (m/s)	RVOT VEL. (m/s)	IVRT (m/)
NORMAL PARAMETER	<1.5	1.6	0.7-1.7		<1.6	<1.3	40-60
PATIENT	NM	1.3	1.31		1.1	0.8	NM
Adapted from June Boon, Veterinary Echocardiography, 1998 Sisson D et al. JVIM 1991; 5: 232, Jacobs et al. Am J Vet Res 1985; 46:1705							

**ULTRASONOGRAPHIC FINDINGS**

These findings are consistent with an essentially normal echocardiogram. Any murmur auscultated will be considered functional in origin.

**INTERPRETATION OF THE FINDINGS & FURTHER RECOMMENDATIONS**

Given these findings, no cardiac therapy is recommended. There are no cardiac contraindications to corticosteroids or fluid therapy as indicated for further treatment. No specific recheck echocardiogram is recommended.



**PATIENT**

Wednesday Stellar

**SPECIES**

Feline

**BREED**

Domestic Shorthair

**SEX**

Spayed female

**AGE**

8 years

**WEIGHT**

8.5 lbs

**INTERPRETED BY**

Bradley Harris, DVM,  
 DACVECC, DACVIM  
 (cardiology)

**IMAGING PERFORMED BY**

Rebecca Hamilton

**HOSPITAL NAME**

Kingston AH

**REFERRING VET**

Dr. Turner

**INVOICE**

78014

**DATE**

5/27/26

Anesthesia considerations:

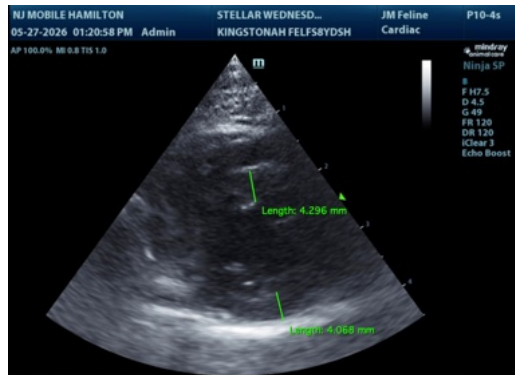
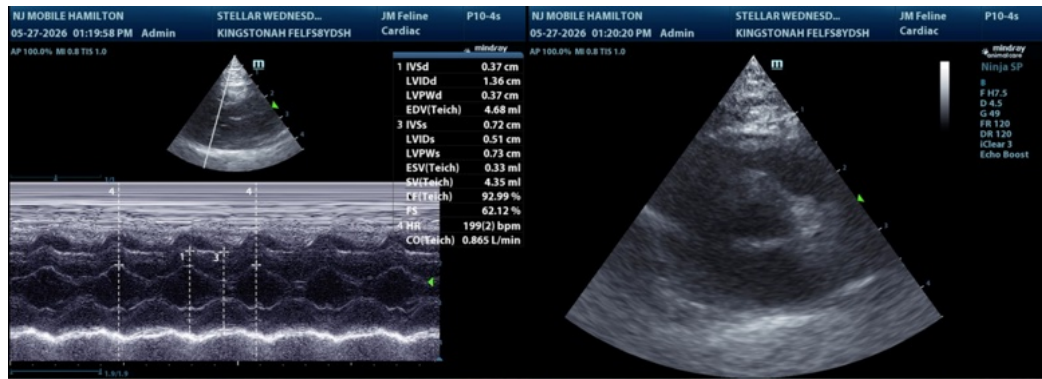
No special cardiac considerations are necessary

Diet:

No special considerations are necessary. Any high-quality food from Hills, Royal Canin, Science Diet, Eukanuba, Iams, or Purina is reasonable.

Activity:

No special considerations are necessary.



The information and recommendations provided are based on the images presented by the referring veterinarian/sonographer. No evaluation can be communicated regarding pathology that was not visible in the image/video clips provided.

Thank you for this referral. If the clinical or image interpretation does not parallel your findings or if I can be of any further assistance please contact me.

Bradley Harris, DVM, DACVECC, DACVIM (cardiology)

[info@SonoPath.com](mailto:info@SonoPath.com)