



PATIENT

Nicky Linares

SPECIES

Feline

BREED

Domestic Shorthair

SEX

Spayed female

AGE

14 years

WEIGHT

6.38 kg

INTERPRETED BY

Bradley Harris, DVM,
 DACVECC, DACVIM
 (cardiology)

IMAGING PERFORMED BY

Vincent Ravancho,
 CVT

HOSPITAL NAME

Bond Vet Montclair

REFERRING VET

Dr. Mancuso

PRESENTING CLINICAL SIGNS

History: U/S for echo. Clinical findings - Dyspnea, on Sunday, increased BV sounds bilaterally, B-Lines, Abnormal BNP. Current medications - Furosemide 12.5 mg 1/2 tab q8hr.
 Abnormal PE/Chem/CBC/UA Results: Abnormal proBNP, Hyperglycemia, Elevated BUN, Hypokalemia

ULTRASONOGRAPHIC EXAMINATION OF THE HEART

The left atrium is moderately to severely enlarged. There are no distinct left atrial thrombi/clots or spontaneous echo contrast appreciated. The left ventricle is upper limits of normal to mildly enlarged, with equivocal wall thickness and no evidence of restriction. Left ventricular systolic function is normal, with adequate contractility. The right atrium and ventricle are subjectively normal in dimension and systolic function. The anterior and posterior mitral and tricuspid valve leaflets presented normal linear structure, extension in systole, and union in diastole without regurgitation. There is no evidence of systolic anterior mitral motion documented. The left ventricular outflow tract demonstrated normal laminar flow and subjective structural valvular integrity. The visible aorta is unremarkable. Pulmonary outflow tract assessment revealed normal valve structure, laminar flow, and appropriate diameter and distensibility. There is no evidence of semilunar valve insufficiency or pulmonary hypertension documented. There is scant pericardial, but no pleural, or free peritoneal fluid noted. Several B-lines are noted within the pulmonary parenchyma.

FELINE CARDIAC PARAMETERS	BODY WEIGHT (kg)	HR (BPM)	IVSd (cm)	LVIDd (cm)	LVWd (cm)	FS (%)	EF (%)
NORMAL PARAMETER	-----	150-240	0.3-0.6	1.0-2.1	0.25-0.6	35-67	80-100
PATIENT	6.38 kg	180	0.58	2.19	0.52	28	71
FELINE CARDIAC PARAMETERS	LA/AO (M-mode)	LA/AO HEART BASE (Sisson)	LAD LA MAX 4 Chamber		LVOT VEL. (m/s)	RVOT VEL. (m/s)	IVRT (m/)
NORMAL PARAMETER	<1.5	1.6	0.7-1.7		<1.6	<1.3	40-60
PATIENT	2.02	1.75	1.84		0.8	1.0	NM
Adapted from June Boon, Veterinary Echocardiography, 1998 Sisson D et al. JVIM 1991; 5: 232, Jacobs et al. Am J Vet Res 1985; 46:1705							

INVOICE

78015

DATE

5/27/26

ULTRASONOGRAPHIC FINDINGS

These findings identify left atrial dilation in the absence of overt left ventricular hypertrophy or outflow tract obstruction. In the absence of any intrinsic disease (hyperthyroidism or severe anemia) or iatrogenic factors (steroid or fluid administration), these findings would be most consistent with the myocardial form of restrictive cardiomyopathy (RCM). Given the PCE and pulmonary B-lines, congestive heart failure is a possible etiology of the clinical signs.



PATIENT

Nicky Linares

SPECIES

Feline

BREED

Domestic Shorthair

SEX

Spayed female

AGE

14 years

WEIGHT

6.38 kg

INTERPRETED BY

Bradley Harris, DVM,
DACVECC, DACVIM
(cardiology)

**IMAGING
PERFORMED BY**

Vincent Ravancho,
CVT

HOSPITAL NAME

Bond Vet Montclair

REFERRING VET

Dr. Mancuso

INVOICE

78015

DATE

5/27/26

INTERPRETATION OF THE FINDINGS & FURTHER RECOMMENDATIONS

Treatment for CHF is recommended, to include Lasix (1-2mg/kg q24-BID) and Vetmedin (0.25-0.35mg/kg BID). A repeat chest X-rays, chemistry, and BP is recommended again in 1-2 weeks. If the azotemia is resolved, the addition of enalapril (0.5mg/kg q24) is recommended. Additionally, Plavix/clopidogrel (1/4 of a 75 mg tablet, or 18.75 mg PO q 24 h) +/- rivaroxaban (2.5mg q24) should be initiated as an anti-thrombotic. Due to the bitter taste of this medication, it may be best to place it in an empty gelatin capsule or use products such as a Pill Pocket. Barring any setbacks or complications, a repeat echo/rads will be recommended in 3-6 months.

Anesthesia considerations:

Anesthesia should be avoided until signs of congestion have resolved. If anesthesia is necessary, then alpha-2 agonists, ketamine, high dose acepromazine, and Telazol should be avoided. If an ACE inhibitor (enalapril, benazepril) or spironolactone is being given, it should not be administered on the morning of general anesthesia. Other cardiac medications should be administered per the normal dosing schedule. Anesthetic IV fluid use should be limited to < 3 ml/kg/hr and, if IV fluid therapy is administered during the procedure, a 1 mg/kg dose of IM Lasix should be administered when the patient is awake and standing in recovery. A shorter anesthetic duration will reduce the risk of complications. Pre-oxygenation is advised. Premedication with an opioid (i.e., butorphanol, hydromorphone, oxymorphone) with or without a benzodiazepine is generally the safest protocol. An induction agent such as Propofol, alfaxalone, or diazepam/etomidate can be used to effect. Maintenance of anesthesia with isoflurane or sevoflurane is reasonable.

Diet:

A high-quality food from Hills, Royal Canin, Science Diet, Eukanuba, Iams, or Purina that is highly palatable with adequate protein and calories for maintaining optimal body condition with mild dietary sodium restriction (< 100 mg/100 kcal) is recommended. Consider omega-3 fatty acid supplementation.

Activity:

Avoid strenuous activity.



PATIENT

Nicky Linares

SPECIES

Feline

BREED

Domestic Shorthair

SEX

Spayed female

AGE

14 years

WEIGHT

6.38 kg

INTERPRETED BY

Bradley Harris, DVM,
 DACVECC, DACVIM
 (cardiology)

IMAGING PERFORMED BY

Vincent Ravancho,
 CVT

HOSPITAL NAME

Bond Vet Montclair

REFERRING VET

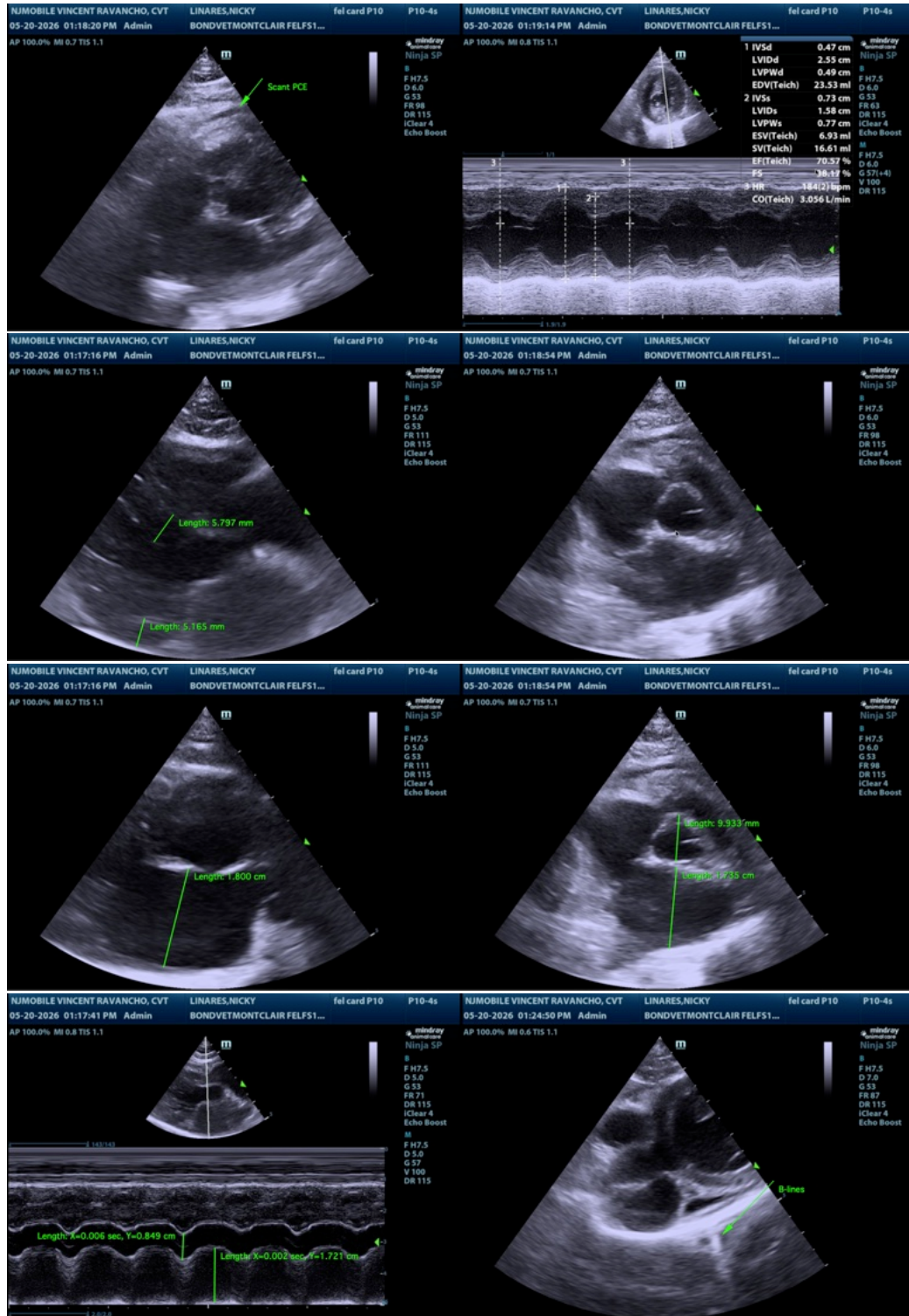
Dr. Mancuso

INVOICE

78015

DATE

5/27/26





PATIENT

Nicky Linares

SPECIES

Feline

BREED

Domestic Shorthair

SEX

Spayed female

AGE

14 years

WEIGHT

6.38 kg

INTERPRETED BY

Bradley Harris, DVM,
DACVECC, DACVIM
(cardiology)

**IMAGING
PERFORMED BY**

Vincent Ravancho,
CVT

HOSPITAL NAME

Bond Vet Montclair

REFERRING VET

Dr. Mancuso

INVOICE

78015

DATE

5/27/26

The information and recommendations provided are based on the images presented by the referring veterinarian/sonographer. No evaluation can be communicated regarding pathology that was not visible in the image/video clips provided.

Thank you for this referral. If the clinical or image interpretation does not parallel your findings or if I can be of any further assistance please contact me.

Bradley Harris, DVM, DACVECC, DACVIM (cardiology)

info@SonoPath.com