



PATIENT

Friday Jerome

SPECIES

Feline

BREED

Domestic Shorthair

SEX

Neutered male

AGE

12 years

WEIGHT

12.7 lbs

INTERPRETED BY

Bradley Harris, DVM,
 DACVECC, DACVIM
 (cardiology)

IMAGING PERFORMED BY

Vincent Ravancho,
 CVT

HOSPITAL NAME

Plainfield AH

REFERRING VET

Dr. Ezik

INVOICE

74187

DATE

4/6/26

PRESENTING CLINICAL SIGNS

- Abnormal proBNP Snap test
- Pt was seen 3/31 for vomiting + not eating, improved with treatment (convenia/cerenia).
- Hx hyperthyroidism
- Current medications - Transdermal methimazole, Mirtazipine as needed, sedated with Gabapentin this morning
- Neutrophils - 14020, BUN 46, Amylase 1630, K+ 3.3 U/A - trace protein, UPC 0.8, USG 1.017

ULTRASONOGRAPHIC EXAMINATION OF THE HEART

The left atrium is mildly enlarged. There are no distinct left atrial thrombi/clots or spontaneous echo contrast appreciated. The left ventricle is normal in dimension, with moderate concentric hypertrophy, and no evidence of restriction. Left ventricular systolic function is normal, with adequate contractility. The right atrium and ventricle are subjectively normal in dimension and systolic function. The anterior and posterior mitral and tricuspid valve leaflets presented normal linear structure, extension in systole, and union in diastole with mild regurgitation. There is no evidence of systolic anterior mitral motion documented. The left ventricular outflow tract demonstrated normal laminar flow and subjective structural valvular integrity. The visible aorta is unremarkable. Pulmonary outflow tract assessment revealed normal valve structure, laminar flow, and appropriate diameter and distensibility. There is no evidence of semilunar valve insufficiency or pulmonary hypertension documented. There is no visible pericardial, pleural, or free peritoneal fluid noted.

FELINE CARDIAC PARAMETERS	BODY WEIGHT (kg)	HR (BPM)	IVSd (cm)	LVIDd (cm)	LVWd (cm)	FS (%)	EF (%)
NORMAL PARAMETER	-----	150-240	0.3-0.6	1.0-2.1	0.25-0.6	35-67	80-100
PATIENT	5.77 kg	240	0.71	2.11	0.73	45	60
FELINE CARDIAC PARAMETERS	LA/AO (M-mode)	LA/AO HEART BASE (Sisson)	LAD LA MAX 4 Chamber		LVOT VEL. (m/s)	RVOT VEL. (m/s)	IVRT (m/)
NORMAL PARAMETER	<1.5	1.6	0.7-1.7		<1.6	<1.3	40-60
PATIENT	1.84	1.48	1.87		0.9	0.9	NM
Adapted from June Boon, Veterinary Echocardiography, 1998 Sisson D et al. JVIM 1991; 5: 232, Jacobs et al. Am J Vet Res 1985; 46:1705							

ULTRASONOGRAPHIC FINDINGS

These findings identify left ventricular hypertrophy in the absence of an outflow tract obstruction, consistent with hypertrophic cardiomyopathy (HCM). As a consequence of the heart disease, the left atrium is also enlarged.



PATIENT

Friday Jerome

SPECIES

Feline

BREED

Domestic Shorthair

SEX

Neutered male

AGE

12 years

WEIGHT

12.7 lbs

INTERPRETED BY

Bradley Harris, DVM,
 DACVECC, DACVIM
 (cardiology)

IMAGING PERFORMED BY

Vincent Ravancho,
 CVT

HOSPITAL NAME

Plainfield AH

REFERRING VET

Dr. Ezik

INVOICE

74187

DATE

4/6/26

INTERPRETATION OF THE FINDINGS & FURTHER RECOMMENDATIONS

Given the history of hyperthyroidism, it is possible that the hypertrophy is secondary to thyrotoxic cardiomyopathy, especially if the thyroid values have not been controlled for a prolonged period. If they have, then the left ventricular hypertrophy is likely due to primary hypertrophic cardiomyopathy. The clinical course for cats with HCM is incredibly variable. Results of future rechecks, especially the echocardiogram, will help us better determine the long-term prognosis. Cats with mild cardiac changes can live for years with static disease. Complications are more likely to occur in cats with advanced heart disease, and include congestive heart failure, sudden death due to arrhythmias, and thromboembolism.

There is uncertainty when considering therapy in an asymptomatic cat with heart disease prior to the onset of heart failure. The presence of hypertrophy makes the use of a beta blocker worth considering. However, beta blockers do have the potential to worsen hemodynamic function, which is more of a concern in the setting of left atrial dilation. In these cases, the concurrent use of an ACEi (enalapril/benazepril) can be considered as well at 0.25-0.5 mg/kg orally once a day with a recheck of blood pressure and renal values in one week and three months. Additionally, Plavix/clopidogrel could also be initiated as an anti-thrombotic (1/4 of a 75 mg tablet, or 18.75 mg PO q 24 h). Due to the bitter taste of this medication, it may be best to place it in an empty gelatin capsule or use products such as a Pill Pocket.

The challenge of treating these cats is the lack of significant data to support a meaningful benefit (most of the rationale for their use is theoretical), coupled with the potential for adverse effects (low BP, renal impairment, potential exacerbation of CHF). If atenolol is used, the atenolol dose would be 1-2mg/kg once daily (with the potential of increasing to BID if tolerated after 1 week). A recheck of heart rate, BP, and chemistry would be indicated 1 week after starting therapy; at that time the need for higher doses of atenolol can be assessed. Ultimately, a conversation with the owner is necessary to determine what course of therapy is most suitable for them.

A recheck echocardiogram is recommended in 6 months to monitor for progression, or sooner, if clinical signs are noted.

Owners should begin monitoring the resting respiratory rate. A normal respiratory rate is less than 30 breaths per minute; however, the trend in breathing rate is most important. If a progressive increase in respiratory rate is seen, then evaluation by a veterinarian is necessary.

Anesthesia considerations:

While there is no CHF present, there is likely an increased anesthetic risk which must be considered prior to any anesthetic procedure. If anesthesia is necessary, then alpha-2 agonists, ketamine, high dose acepromazine, and Telazol should be avoided. If an ACE inhibitor (enalapril, benazepril) or spironolactone is being given, it should not be administered on the morning of general anesthesia. Other cardiac medications should be administered per the normal dosing schedule. Fluid therapy during anesthesia should be considered at a reduced rate (e.g., 2-3 ml/kg/hour) if possible (i.e., if not hypotensive). A shorter anesthetic duration will reduce the risk of complications. Pre-oxygenation is advised. Premedication with an opioid (i.e., butorphanol, hydromorphone, oxymorphone) with or without a benzodiazepine is generally the safest protocol. An induction agent such as Propofol, alfaxalone, or diazepam/etomidate can be used to effect. Maintenance of anesthesia with isoflurane or sevoflurane is reasonable.

Diet:

No special considerations are necessary. Any high-quality food from Hills, Royal Canin, Science Diet, Eukanuba, Iams, or Purina is reasonable.



PATIENT

Friday Jerome

SPECIES

Feline

BREED

Domestic Shorthair

SEX

Neutered male

AGE

12 years

WEIGHT

12.7 lbs

INTERPRETED BY

Bradley Harris, DVM,
 DACVECC, DACVIM
 (cardiology)

IMAGING PERFORMED BY

Vincent Ravancho,
 CVT

HOSPITAL NAME

Plainfield AH

REFERRING VET

Dr. Ezik

INVOICE

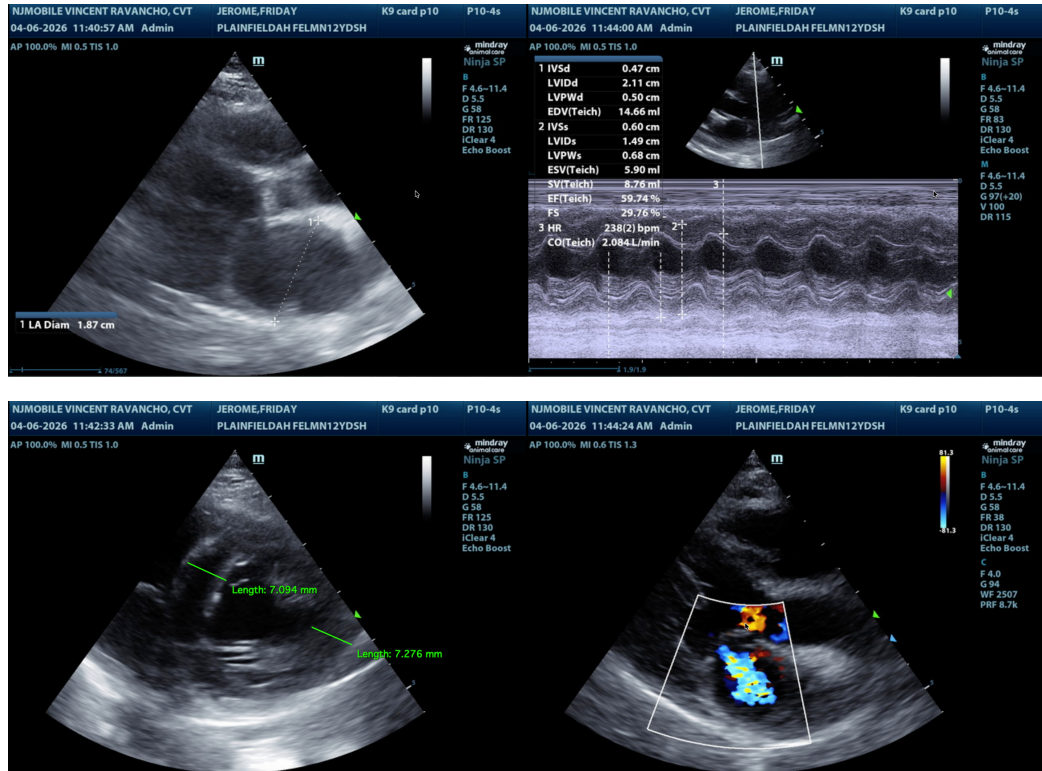
74187

DATE

4/6/26

Activity:

Avoid overly strenuous activity.



The information and recommendations provided are based on the images presented by the referring veterinarian/sonographer. No evaluation can be communicated regarding pathology that was not visible in the image/video clips provided.

Thank you for this referral. If the clinical or image interpretation does not parallel your findings or if I can be of any further assistance please contact me.

Bradley Harris, DVM, DACVECC, DACVIM (cardiology)

info@SonoPath.com