



**PATIENT**

Sophie Vaz

**PRESENTING CLINICAL SIGNS**

- Cardiac murmur (newly dx)

**SPECIES**

Canine

**ULTRASONOGRAPHIC EXAMINATION OF THE HEART**

**BREED**

Pitbull

**SEX**

Spayed female

**AGE**

3 years

The left atrium is normal in dimension. The left ventricle is normal in dimension, with normal systolic function. The right atrium and ventricle are normal in dimension, with normal systolic function. The anterior and posterior mitral valve leaflets are appropriately thin with adequate apposition, intact chordae, and there is no significant prolapse. There is no significant mitral regurgitation identified. The tricuspid valve leaflets are appropriately thin with adequate apposition, intact chordae, with trivial tricuspid regurgitation and no evidence of pulmonary hypertension. The left ventricular outflow tract demonstrated normal laminar flow and the visible aorta is unremarkable. The right ventricular outflow tract assessment revealed normal laminar flow, with appropriate main pulmonary artery diameter and right pulmonary artery distensibility. There is no pulmonic and no aortic valve insufficiency identified. There is no visible pericardial, pleural, or free peritoneal fluid documented. No evidence of hepatic venous congestion is noted. The cardiac chambers, pericardial and visible extra-cardiac regions were free of masses, spontaneous echo contrast, or thrombi.

**WEIGHT**

46 lbs

CANINE CARDIAC PARAMETERS	Body Weight kg	HR BPM	LAD 4 ch Long	RAD 4 ch Long	La/Ao Heart Base	LVIDd	LVIDs
NORMAL PARAMETER		50-100			<1.6		
PATIENT	20.91 kg	NM	3.99	2.49	1.27	4.09	2.42
CANINE CARDIAC PARAMETERS	FS	EPSS	PV V MAX (m/s)	AV V Max (m/sec)	MR Vmax	TR Vmax	RPA distensibility (normal >30%)
NORMAL PARAMETER	28-40	<0.6	0.7-1.6	0.7-1.7	4.5-5.5	< 2.7	
PATIENT	41	0.4	1.3	2.4	NM	NM	NM

**INTERPRETED BY**

Bradley Harris, DVM, DACVECC, DACVIM (cardiology)

**IMAGING PERFORMED BY**

Meghan Morse, LVT, CVT

**HOSPITAL NAME**

Narrowsburg Veterinary

**REFERRING VET**

Dr. Hess

**INVOICE**

74169

**DATE**

4/3/26

**ULTRASONOGRAPHIC FINDINGS**

These findings are consistent with an essentially normal echocardiogram. Any murmur will be considered functional in origin (secondary to a dynamic left and right ventricular outflow tract obstruction). No cardiac cause of the morbidity is identified.

**INTERPRETATION OF THE FINDINGS & FURTHER RECOMMENDATIONS**

Given these findings, no cardiac therapy is recommended. There are no cardiac contraindications to fluid therapy or corticosteroid therapy, as indicated for further assessment and treatment. No specific cardiac recheck is recommended unless a murmur or clinical signs of heart disease develop.



**PATIENT**

Anesthesia considerations:  
 No special considerations are necessary.

Sophie Vaz

**SPECIES**

Diet:  
 No special considerations are necessary. Any high-quality food from Hills, Royal Canin, Science Diet, Eukanuba, Iams, or Purina is reasonable.

Canine

**BREED**

Activity:  
 No special considerations are necessary.

Pitbull

**SEX**

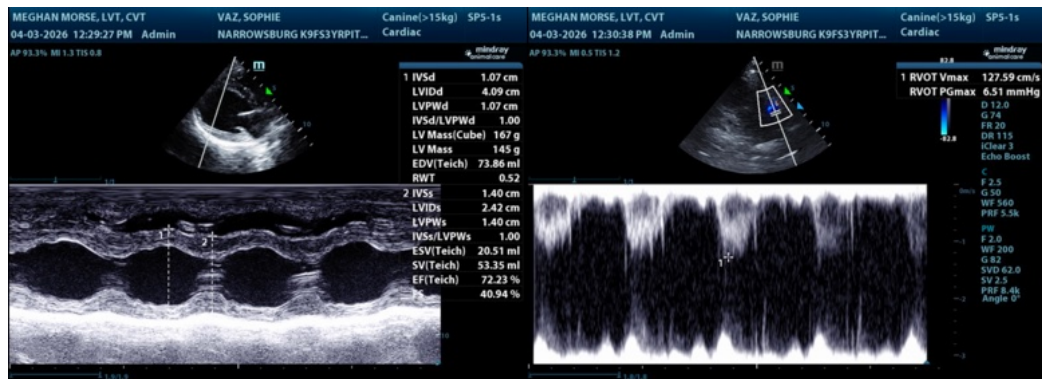
Spayed female

**AGE**

3 years

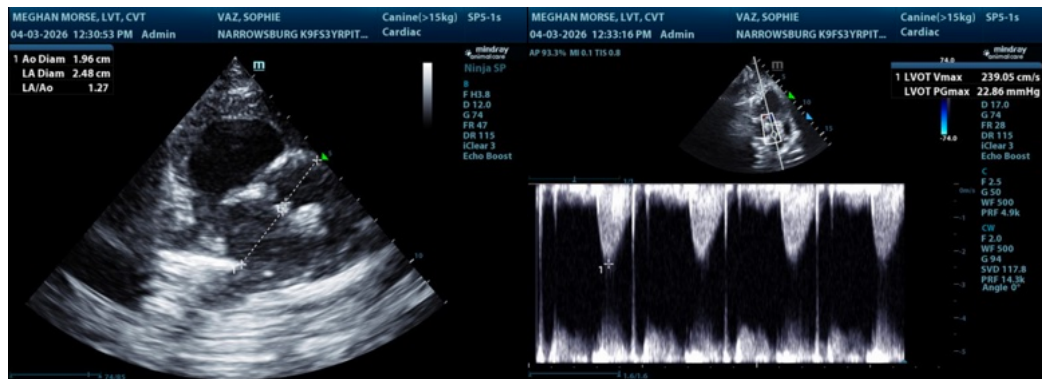
**WEIGHT**

46 lbs



**INTERPRETED BY**

Bradley Harris, DVM,  
 DACVECC, DACVIM  
 (cardiology)



**IMAGING PERFORMED BY**

Meghan Morse, LVT,  
 CVT

**HOSPITAL NAME**

Narrowsburg  
 Veterinary

**REFERRING VET**

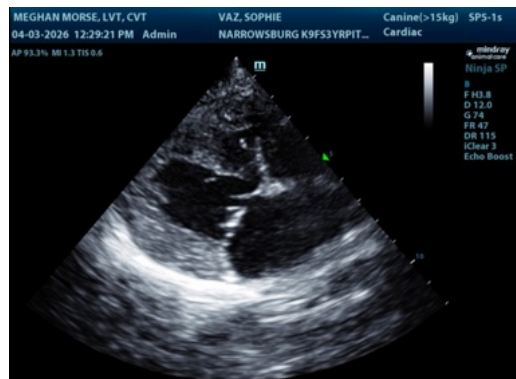
Dr. Hess

**INVOICE**

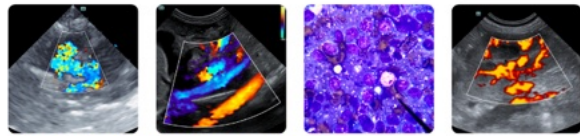
74169

**DATE**

4/3/26



The information and recommendations provided are based on the images presented by the



**PATIENT**

Sophie Vaz

**SPECIES**

Canine

**BREED**

Pitbull

**SEX**

Spayed female

**AGE**

3 years

**WEIGHT**

46 lbs

**INTERPRETED BY**

Bradley Harris, DVM,  
DACVECC, DACVIM  
(cardiology)

**IMAGING  
PERFORMED BY**

Meghan Morse, LVT,  
CVT

**HOSPITAL NAME**

Narrowsburg  
Veterinary

**REFERRING VET**

Dr. Hess

**INVOICE**

74169

**DATE**

4/3/26

**referring veterinarian/sonographer. No evaluation can be communicated regarding pathology that was not visible in the image/video clips provided.**

Thank you for this referral. If the clinical or image interpretation does not parallel your findings or if I can be of any further assistance please contact me.

Bradley Harris, DVM, DACVECC, DACVIM (cardiology)

[info@SonoPath.com](mailto:info@SonoPath.com)