



PATIENT

Tyson Gelada

SPECIES

Canine

BREED

Chihuahua Mix

SEX

Neutered male

AGE

6 years

WEIGHT

19.9 lbs

INTERPRETED BY

Bradley Harris, DVM,
 DACVECC, DACVIM
 (cardiology)

IMAGING PERFORMED BY

Shari, Reffi, CVT

HOSPITAL NAME

Brodheads ville VC

REFERRING VET

Dr. Worton

INVOICE

74778

DATE

4/23/26

PRESENTING CLINICAL SIGNS

History: BCS 5/9. Grade 4-5/6 L systolic heart murmur, strong pulses. No current meds other than Trazodone for scan.

Abnormal PE/Chem/CBC/UA Results: WNL

ULTRASONOGRAPHIC EXAMINATION OF THE HEART

The left atrium is normal in dimension. The left ventricle is normal in dimension with normal systolic function, and the right atrium and right ventricle are normal in dimension with normal systolic function. The anterior and posterior mitral valve leaflets are thickened and redundant, consistent with myxomatous degeneration, with no significant prolapse, and mild mitral regurgitation is identified. The tricuspid valve leaflets are minimally thickened with trivial tricuspid regurgitation and no evidence of pulmonary hypertension. The left ventricular outflow tract demonstrates normal laminar flow, and the visible aorta is unremarkable. The right ventricular outflow tract demonstrates normal laminar flow with appropriate main pulmonary artery diameter and normal right pulmonary artery distensibility. There is no pulmonic or aortic valve insufficiency identified. There is no visible pericardial, pleural, or free peritoneal fluid documented, and no evidence of hepatic venous congestion is noted. The cardiac chambers, pericardium, and visible extracardiac regions are free of masses, spontaneous echo contrast, or thrombi.

CANINE CARDIAC PARAMETERS	Body Weight kg	HR BPM	LAD 4 ch Long	RAD 4 ch Long	La/Ao Heart Base	LVIDd	LVIDs
NORMAL PARAMETER		50-100			<1.6		
PATIENT	9.05 kg	160	2.77	1.83	1.18	2.77	1.92
CANINE CARDIAC PARAMETERS	FS	EPSS	PV V MAX (m/s)	AV V Max (m/sec)	MR Vmax	TR Vmax	RPA distensibility (normal >30%)
NORMAL PARAMETER	28-40	<0.6	0.7-1.6	0.7-1.7	4.5-5.5	< 2.7	
PATIENT	31	0.2	0.8	1.4	5.5	2.4	NM

ULTRASONOGRAPHIC FINDINGS

These findings are consistent with degenerative/myxomatous mitral valve disease with minimal to mild hemodynamic effects consistent with ACVIM Stage B1 disease. It is unlikely that any current morbidity is of cardiac origin.

INTERPRETATION OF THE FINDINGS & FURTHER RECOMMENDATIONS

Given these findings, no cardiac therapy is recommended. There are no cardiac contraindications to anesthesia, fluid therapy, vasopressor therapy, or corticosteroids as indicated for further assessment



PATIENT

Tyson Gelada

SPECIES

Canine

BREED

Chihuahua Mix

SEX

Neutered male

AGE

6 years

WEIGHT

19.9 lbs

INTERPRETED BY

Bradley Harris, DVM,
DACVECC, DACVIM
(cardiology)

IMAGING PERFORMED BY

Shari, Reffi, CVT

HOSPITAL NAME

Brodheads ville VC

REFERRING VET

Dr. Worton

INVOICE

74778

DATE

4/23/26

and treatment. If not already performed, baseline thoracic radiographs and blood pressure are recommended. A recheck echocardiogram is recommended in 6 months.

Anesthesia considerations:

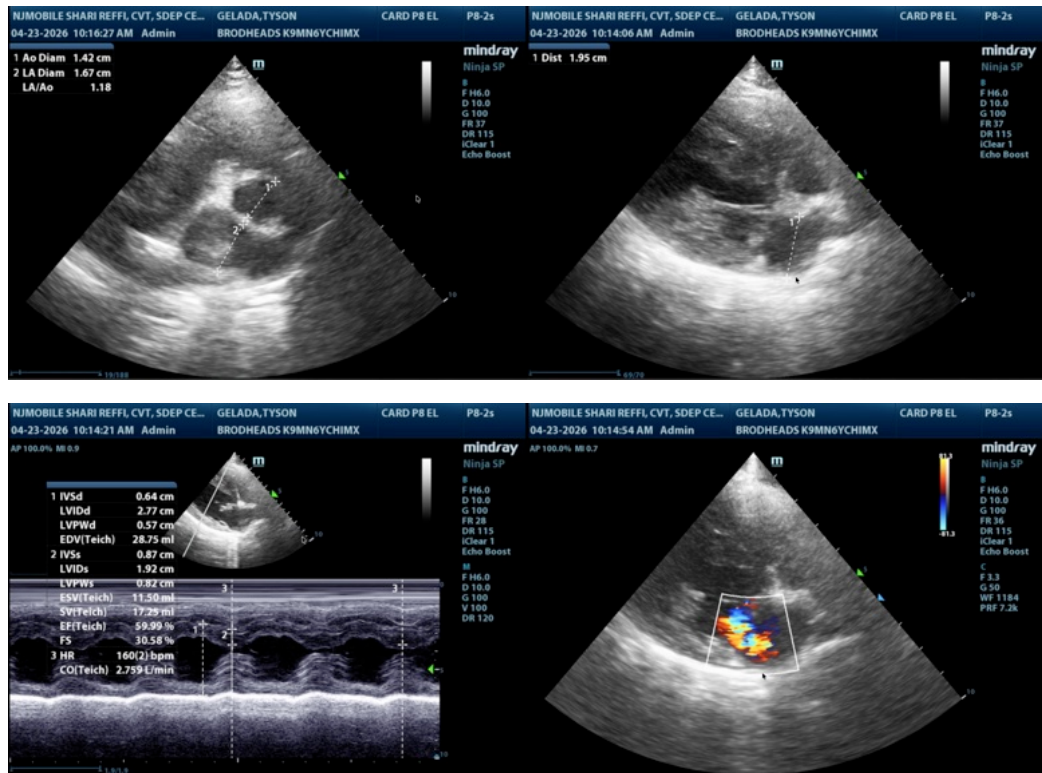
If anesthesia is necessary, alpha-2 agonists, ketamine, high dose acepromazine, and Telazol should be avoided. Fluid therapy during anesthesia should be considered at a conservative rate (e.g., 5 ml/kg/hour) if possible.

Diet:

A high-quality food from Hills, Royal Canin, Science Diet, Eukanuba, Iams, or Purina that is highly palatable with adequate protein and calories for maintaining optimal body condition is reasonable.

Activity:

No special considerations are necessary.



he information and recommendations provided are based on the images presented by the referring veterinarian/sonographer. No evaluation can be communicated regarding pathology that was not visible in the image/video clips provided.

Thank you for this referral. If the clinical or image interpretation does not parallel your findings or if I can be of any further assistance please contact me.

Bradley Harris, DVM, DACVECC, DACVIM (cardiology)

info@SonoPath.com