



**PATIENT**

Murphy Alpaugh

**SPECIES**

Canine

**BREED**

Mix

**SEX**

Neutered male

**AGE**

11 years

**WEIGHT**

55 lbs

**INTERPRETED BY**

Bradley Harris, DVM,  
 DACVECC, DACVIM  
 (cardiology)

**IMAGING PERFORMED BY**

Chloe Lowe, CVT

**HOSPITAL NAME**

Long Valley AH

**REFERRING VET**

Dr. Stanton

**INVOICE**

74776

**DATE**

4/23/26

**PRESENTING CLINICAL SIGNS**

History: Pre-anesthetic. Grade V/VI left pansystolic murmur - stable for years. Thyroxine 0.5mg BID, gabapentin and trazadone for scan, clindamycin (dental dz) Anaplasma positive, normal cbc. Lyme positive, low c6. Otherwise WNL

**ULTRASONOGRAPHIC FINDINGS**

The left atrium is at the upper limits of normal to mildly enlarged. The left ventricle is normal in dimension with normal systolic function, and the right atrium and right ventricle are normal in dimension with normal systolic function. The anterior and posterior mitral valve leaflets are thickened and redundant, consistent with myxomatous degeneration, with minimal leaflet prolapse, and moderate mitral regurgitation is identified. The tricuspid valve leaflets are appropriately thin with adequate apposition and intact chordae, with no significant tricuspid regurgitation and no evidence of pulmonary hypertension. The left ventricular outflow tract demonstrates normal laminar flow, and the visible aorta is unremarkable. The right ventricular outflow tract demonstrates normal laminar flow with appropriate main pulmonary artery diameter and normal right pulmonary artery distensibility. There is no pulmonic or aortic valve insufficiency identified. There is no visible pericardial, pleural, or free peritoneal fluid documented, and no evidence of hepatic venous congestion is noted. The cardiac chambers, pericardium, and visible extracardiac regions are free of masses, spontaneous echo contrast, or thrombi.

CANINE CARDIAC PARAMETERS	Body Weight kg	HR BPM	LAD 4 ch Long	RAD 4 ch Long	La/Ao Heart Base	LVIDd	LVIDs
NORMAL PARAMETER		50-100			<1.6		
PATIENT	25 kg	110	4.5	NM	1.24	4.04	2.69
CANINE CARDIAC PARAMETERS	FS	EPSS	PV V MAX (m/s)	AV V Max (m/sec)	MR Vmax	TR Vmax	RPA distensibility (normal >30%)
NORMAL PARAMETER	28-40	<0.6	0.7-1.6	0.7-1.7	4.5-5.5	< 2.7	
PATIENT	33	0.6	NM	1.0	5.0	NM	NM

**ULTRASONOGRAPHIC FINDINGS**

These findings are consistent with degenerative/myxomatous mitral valve disease with minimal to mild hemodynamic effects consistent with ACVIM Stage B1 disease. It is unlikely that any current morbidity is of cardiac origin.



**PATIENT**

Murphy Alpaugh

**SPECIES**

Canine

**BREED**

Mix

**SEX**

Neutered male

**AGE**

11 years

**WEIGHT**

55 lbs

**INTERPRETED BY**

Bradley Harris, DVM,  
 DACVECC, DACVIM  
 (cardiology)

**IMAGING PERFORMED BY**

Chloe Lowe, CVT

**HOSPITAL NAME**

Long Valley AH

**REFERRING VET**

Dr. Stanton

**INVOICE**

74776

**DATE**

4/23/26

**INTERPRETATION OF THE FINDINGS & FURTHER RECOMMENDATIONS**

Given these findings, no cardiac therapy is recommended. There are no cardiac contraindications to anesthesia, fluid therapy, vasopressor therapy, or corticosteroids as indicated for further assessment and treatment. If not already performed, baseline thoracic radiographs and blood pressure are recommended. A recheck echocardiogram is recommended in 6 months.

Anesthesia considerations:

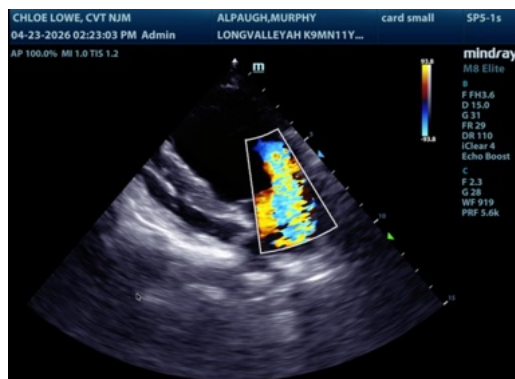
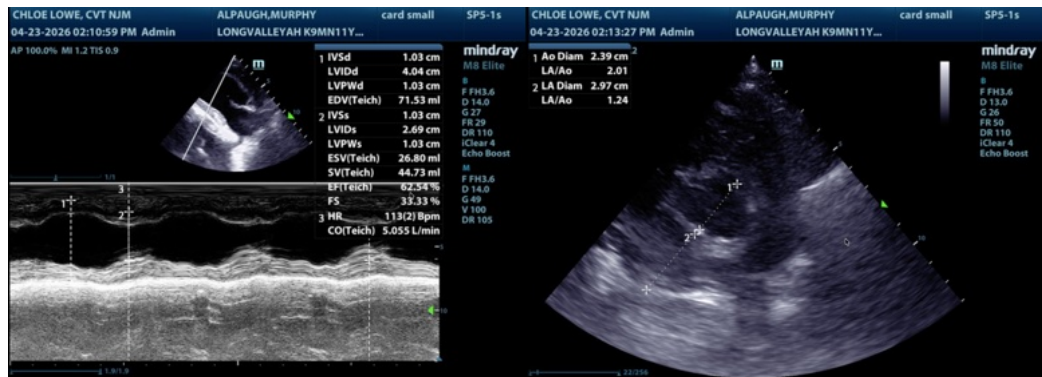
If anesthesia is necessary, alpha-2 agonists, ketamine, high dose acepromazine, and Telazol should be avoided. Fluid therapy during anesthesia should be considered at a conservative rate (e.g., 5 ml/kg/hour) if possible.

Diet:

A high-quality food from Hills, Royal Canin, Science Diet, Eukanuba, Iams, or Purina that is highly palatable with adequate protein and calories for maintaining optimal body condition is reasonable.

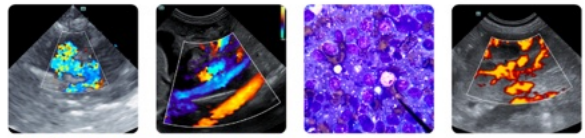
Activity:

No special considerations are necessary.



The information and recommendations provided are based on the images presented by the referring veterinarian/sonographer. No evaluation can be communicated regarding pathology that was not visible in the image/video clips provided.

Thank you for this referral. If the clinical or image interpretation does not parallel your findings or if I can be of any further assistance please contact me.



**PATIENT**

**Bradley Harris, DVM, DACVECC, DACVIM (cardiology)**

Murphy Alpaugh

[info@SonoPath.com](mailto:info@SonoPath.com)

**SPECIES**

Canine

**BREED**

Mix

**SEX**

Neutered male

**AGE**

11 years

**WEIGHT**

55 lbs

**INTERPRETED BY**

Bradley Harris, DVM,  
DACVECC, DACVIM  
(cardiology)

**IMAGING  
PERFORMED BY**

Chloe Lowe, CVT

**HOSPITAL NAME**

Long Valley AH

**REFERRING VET**

Dr. Stanton

**INVOICE**

74776

**DATE**

4/23/26