



PATIENT

Hollie Hansen

SPECIES

Feline

BREED

Domestic Shorthair

SEX

Spayed female

AGE

9 years

WEIGHT

-

INTERPRETED BY

Bradley Harris, DVM,
DACVECC, DACVIM
(cardiology)

IMAGING PERFORMED BY

Vincent Ravancho,
CVT

HOSPITAL NAME

Englewood VC

REFERRING VET

Dr. Sarmiento-Lao

INVOICE

74637

DATE

4/21/26

PRESENTING CLINICAL SIGNS

Grade III/VI HM and arrhythmia
proBNP 1500 USG - 1.024

ULTRASONOGRAPHIC EXAMINATION OF THE HEART

The left atrium is normal in dimension. There are no distinct left atrial thrombi/clots or spontaneous echo contrast appreciated. The left ventricle is normal in dimension as well as wall thickness, and no evidence of restriction. Left ventricular systolic function is normal, with adequate contractility based on fractional shortening and systolic left ventricular dimensions. The right atrium and ventricle are subjectively normal in dimension and systolic function. The anterior and posterior mitral and tricuspid valve leaflets presented normal linear structure, extension in systole, and union in diastole without regurgitation. There is no evidence of systolic anterior mitral valve motion documented. The left ventricular outflow tract demonstrated normal laminar flow with suspected but not confirmed aortic insufficiency. The visible aorta is unremarkable. Pulmonary outflow tract assessment revealed normal valve structure, laminar flow, and appropriate diameter and distensibility. There is no evidence of pulmonary hypertension documented. There is no visible pericardial, pleural, or free peritoneal fluid noted.

FELINE CARDIAC PARAMETERS	BODY WEIGHT (kg)	HR (BPM)	IVSd (cm)	LVIDd (cm)	LVWd (cm)	FS (%)	EF (%)
NORMAL PARAMETER	-----	150-240	0.3-0.6	1.0-2.1	0.25-0.6	35-67	80-100
PATIENT	Not provided	170	0.54	1.6	0.54	31	92
FELINE CARDIAC PARAMETERS	LA/AO (M-mode)	LA/AO HEART BASE (Sisson)	LAD LA MAX 4 Chamber		LVOT VEL. (m/s)	RVOT VEL. (m/s)	IVRT (m/)
NORMAL PARAMETER	<1.5	1.6	0.7-1.7		<1.6	<1.3	40-60
PATIENT	1.4	1.21	1.3		0.9	1.5	NM
Adapted from June Boon, Veterinary Echocardiography, 1998 Sisson D et al. JVIM 1991; 5: 232, Jacobs et al. Am J Vet Res 1985; 46:1705							

ULTRASONOGRAPHIC FINDINGS

These findings are consistent with an essentially normal echocardiogram. The presence of an elevated BNP is often associated with underlying heart disease, but can be seen in animals without heart disease. In addition, changes on chest X-rays can occur without significant underlying disease. The absence of any abnormalities on the echo excludes any meaningful cardiac disease at this time. Any murmur will be considered functional in origin at this time.



PATIENT

Hollie Hansen

SPECIES

Feline

BREED

Domestic Shorthair

SEX

Spayed female

AGE

9 years

WEIGHT

-

INTERPRETED BY

Bradley Harris, DVM,
DACVECC, DACVIM
(cardiology)

IMAGING PERFORMED BY

Vincent Ravancho,
CVT

HOSPITAL NAME

Englewood VC

REFERRING VET

Dr. Sarmiento-Lao

INVOICE

74637

DATE

4/21/26

INTERPRETATION OF THE FINDINGS & FURTHER RECOMMENDATIONS

Given these findings, no cardiac therapy is recommended. There are no cardiac contraindications to corticosteroids or fluid therapy as indicated for further treatment. Given the possibility of aortic insufficiency, a systemic blood pressure should be measured to ensure the absence of hypertension. No specific recheck echocardiogram is recommended.

Anesthesia considerations:

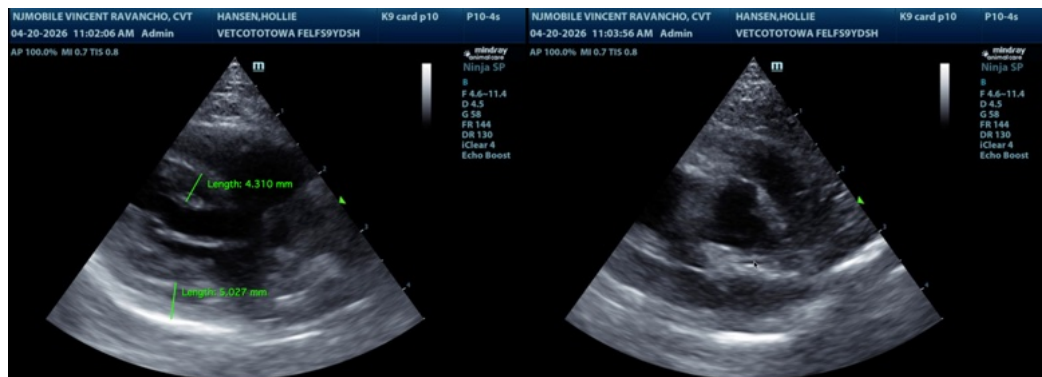
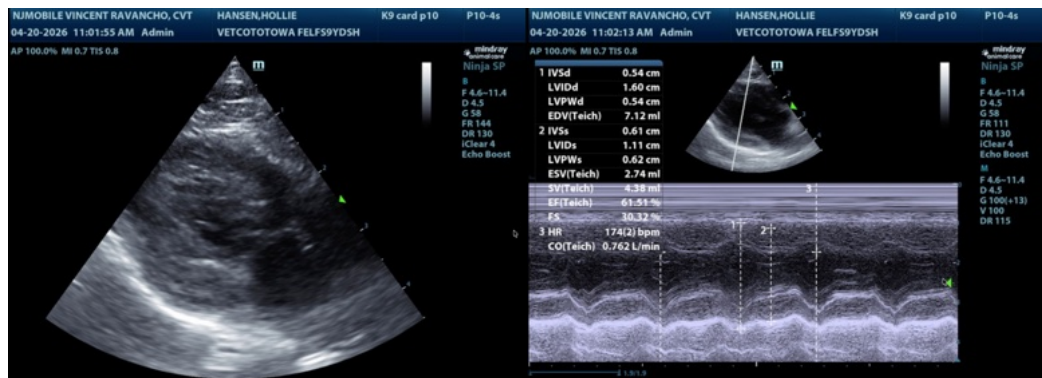
No special cardiac considerations are necessary

Diet:

No special considerations are necessary. Any high-quality food from Hills, Royal Canin, Science Diet, Eukanuba, Iams, or Purina is reasonable.

Activity:

No special considerations are necessary.





PATIENT

Hollie Hansen

SPECIES

Feline

BREED

Domestic Shorthair

SEX

Spayed female

AGE

9 years

WEIGHT

-

INTERPRETED BY

Bradley Harris, DVM,
DACVECC, DACVIM
(cardiology)

IMAGING PERFORMED BY

Vincent Ravancho,
CVT

HOSPITAL NAME

Englewood VC

REFERRING VET

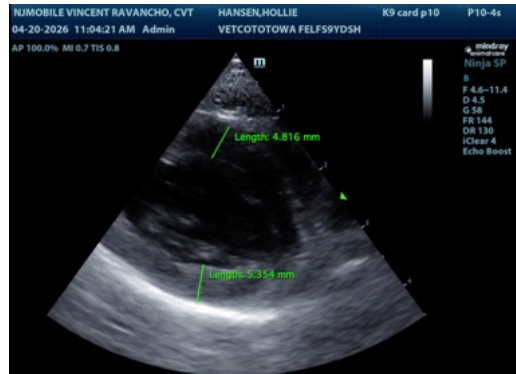
Dr. Sarmiento-Lao

INVOICE

74637

DATE

4/21/26



The information and recommendations provided are based on the images presented by the referring veterinarian/sonographer. No evaluation can be communicated regarding pathology that was not visible in the image/video clips provided.

Thank you for this referral. If the clinical or image interpretation does not parallel your findings or if I can be of any further assistance please contact me.

Bradley Harris, DVM, DACVECC, DACVIM (cardiology)

info@SonoPath.com