



PATIENT

Astro Murray

SPECIES

Canine

BREED

Whippet

SEX

Male

AGE

11 years

WEIGHT

33.5 lbs

INTERPRETED BY

Bradley Harris, DVM,
DACVECC, DACVIM
(cardiology)

IMAGING PERFORMED BY

Vincent Ravancho,
CVT

HOSPITAL NAME

Millburn VH

REFERRING VET

Dr. Rotsides

INVOICE

74477

DATE

4/15/26

PRESENTING CLINICAL SIGNS

History: Recheck Echo. Grade 2/6 HM.
Current medications - Pimobendan 5mg PO BID

ULTRASONOGRAPHIC EXAMINATION OF THE HEART

The left atrium is mild to moderately enlarged. The left ventricle is normal in dimension with normal systolic function. The right atrium and ventricle are normal in dimension with normal systolic function. The anterior and posterior mitral valve leaflets are thickened and redundant consistent with myxomatous changes, and there is moderate prolapse. There is moderate to severe mitral regurgitation identified. The tricuspid valve leaflets are thickened and redundant, with mild tricuspid regurgitation and evidence of moderate pulmonary hypertension. The left ventricular outflow tract demonstrated normal laminar flow and the visible aorta is unremarkable. The right ventricular outflow tract assessment revealed normal laminar flow, with appropriate main pulmonary artery diameter and right pulmonary artery distensibility. There is no pulmonic and mild aortic valve insufficiency identified. There is no visible pericardial, pleural, or free peritoneal fluid documented. No evidence of hepatic venous congestion is noted. The cardiac chambers, pericardial, and visible extra-cardiac regions were free of masses, spontaneous echo contrast, or thrombi.

CANINE CARDIAC PARAMETERS	Body Weight kg	HR BPM	LAD 4 ch Long	RAD 4 ch Long	La/Ao Heart Base	LVIDd	LVIDs
NORMAL PARAMETER		50-100			<1.6		
PATIENT	15.23 kg	130	1.51	1.68	1.38	3.7	2.19
CANINE CARDIAC PARAMETERS	FS	EPSS	PV V MAX (m/s)	AV V Max (m/sec)	MR Vmax	TR Vmax	RPA distensibility (normal >30%)
NORMAL PARAMETER	28-40	<0.6	0.7-1.6	0.7-1.7	4.5-5.5	< 2.7	
PATIENT	41	0.2	2.1	2.5	7.3	3.8	NM

ULTRASONOGRAPHIC FINDINGS

These findings identify borderline to mild left atrial dilation in the presence of mild pulmonary hypertension (PH). Given the progression, the new PH is likely secondary to progressive left sided enlargement. Pulmonary hypertension in dogs is most commonly secondary to primary respiratory disease (chronic bronchitis, pulmonary fibrosis, or other forms of pulmonary interstitial disease). Pulmonary hypertension can also develop in dogs with severe heartworm disease or secondary to pulmonary thromboembolism (PTE). Less commonly, pulmonary hypertension is identified in dogs as an idiopathic condition.



PATIENT

Astro Murray

SPECIES

Canine

BREED

Whippet

SEX

Male

AGE

11 years

WEIGHT

33.5 lbs

INTERPRETED BY

Bradley Harris, DVM,
DACVECC, DACVIM
(cardiology)

IMAGING PERFORMED BY

Vincent Ravancho,
CVT

HOSPITAL NAME

Millburn VH

REFERRING VET

Dr. Rotsides

INVOICE

74477

DATE

4/15/26

INTERPRETATION OF THE FINDINGS & FURTHER RECOMMENDATIONS

Given the progression in chamber dilation, and mild pulmonary hypertension, cardiac therapy will be recommended at this time. Treatment for the PH/potential respiratory disease is warranted if clinical signs are present. The use of Vetmedin (0.25-0.35 mg/kg BID) is appropriate in the absence of more overt clinical signs. The addition of sildenafil (2mg/kg TID) is also reasonable, especially if clinical signs are present. The addition of enalapril (0.5mg/kg BID assuming normotension and lack of azotemia) is also indicated. A repeat echo is indicated in another 6 months, or sooner if progression is suspected, clinical signs develop/worsen, or cardiac therapy is being contemplated.

Anesthesia considerations:

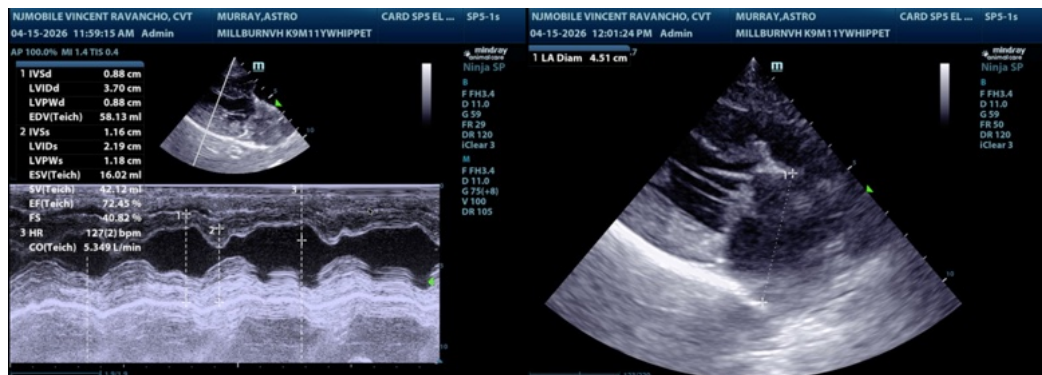
While there is no CHF present, there is likely an increased anesthetic risk which must be considered prior to any anesthetic procedure. If anesthesia is necessary, then alpha-2 agonists, ketamine, and Telazol should be avoided. Fluid therapy during anesthesia does not necessarily need to be adjusted. A shorter anesthetic duration will reduce the risk of complications. Pre-oxygenation is mandatory. Premedication with an opioid (e.g., butorphanol, hydromorphone, oxymorphone) with or without a benzodiazepine is generally the safest protocol. An induction agent such as Propofol, alfaxalone, or diazepam/etomidate can be used to effect. Maintenance of anesthesia with isoflurane or sevoflurane is reasonable.

Diet:

No special considerations are necessary. Any high-quality food from Hills, Royal Canin, Science Diet, Eukanuba, Iams, or Purina is reasonable.

Activity:

Moderate physical activity (meandering walks, exploring the backyard, playing with toys inside, getting excited when family gets home, etc.) is encouraged, but periods of strenuous aerobic activity (jogging, strenuous outdoor ball play, prolonged play at the dog park, etc.) should be avoided, especially during periods of high heat (> 80 F) and humidity. Dogs with heart disease tend to tolerate cool and cold temperatures much better than high temperatures. Avoid sudden increases in activity (e.g. 2 block walks during the week but 2 mile walks followed by 30 minutes at the dog park on the weekends) as this may be difficult for the cardiovascular system to deal with.





PATIENT

Astro Murray

SPECIES

Canine

BREED

Whippet

SEX

Male

AGE

11 years

WEIGHT

33.5 lbs

INTERPRETED BY

Bradley Harris, DVM,
DACVECC, DACVIM
(cardiology)

IMAGING PERFORMED BY

Vincent Ravancho,
CVT

HOSPITAL NAME

Millburn VH

REFERRING VET

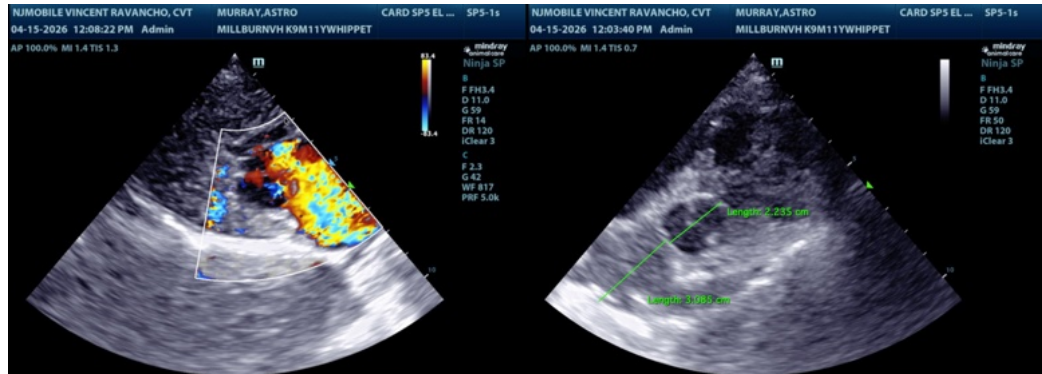
Dr. Rotsides

INVOICE

74477

DATE

4/15/26



The information and recommendations provided are based on the images presented by the referring veterinarian/sonographer. No evaluation can be communicated regarding pathology that was not visible in the image/video clips provided.

Thank you for this referral. If the clinical or image interpretation does not parallel your findings or if I can be of any further assistance please contact me.

Bradley Harris, DVM, DACVECC, DACVIM (cardiology)

info@SonoPath.com