



PATIENT

Mr Macho Carroll

SPECIES

Feline

BREED

Domestic Shorthair

SEX

Neutered male

AGE

4 years

WEIGHT

13.6 lbs

INTERPRETED BY

Bradley Harris, DVM,
 DACVECC, DACVIM
 (cardiology)

IMAGING PERFORMED BY

Vincent Ravancho,
 CVT

HOSPITAL NAME

The Venturing Vet

REFERRING VET

Dr. Herzog

INVOICE

73860

DATE

3/26/26

PRESENTING CLINICAL SIGNS

- Grade III/VI Heart Murmur

ULTRASONOGRAPHIC EXAMINATION OF THE HEART

The left atrium is mildly enlarged. There are no distinct left atrial thrombi/clots or spontaneous echo contrast appreciated. The left ventricle is normal in dimension, with mild concentric hypertrophy, and no evidence of restriction. Left ventricular systolic function is normal, based on fractional shortening and systolic left ventricular dimensions. The right atrium and ventricle are subjectively normal in dimension and systolic function. There is evidence of systolic anterior motion of the mitral valve with mild mitral regurgitation. The tricuspid valve leaflets presented normal linear structure, extension in systole, and union in diastole without regurgitation. The left ventricular outflow tract demonstrated turbulent flow and subjective structural valvular integrity. The visible aorta is unremarkable. Pulmonary outflow tract assessment revealed normal valve structure, laminar flow, and appropriate diameter and distensibility. There is no evidence of semilunar valve insufficiency or pulmonary hypertension documented. There is no visible pericardial, pleural, or free peritoneal fluid noted.

FELINE CARDIAC PARAMETERS	BODY WEIGHT (kg)	HR (BPM)	IVSd (cm)	LVIDd (cm)	LVWd (cm)	FS (%)	EF (%)
NORMAL PARAMETER	-----	150-240	0.3-0.6	1.0-2.1	0.25-0.6	35-67	80-100
PATIENT	6.18	205	0.63	2.01	0.64	42	75
FELINE CARDIAC PARAMETERS	LA/AO (M-mode)	LA/AO HEART BASE (Sisson)	LAD LA MAX 4 Chamber		LVOT VEL. (m/s)	RVOT VEL. (m/s)	IVRT (m/)
NORMAL PARAMETER	<1.5	1.6	0.7-1.7		<1.6	<1.3	40-60
PATIENT	NM	1.72	1.9		1.6	1.0	NM

Adapted from June Boon, Veterinary Echocardiography, 1998
 Sisson D et al. JVIM 1991; 5: 232, Jacobs et al. Am J Vet Res 1985; 46:1705

ULTRASONOGRAPHIC FINDINGS

These findings identify left ventricular hypertrophy in the setting of an outflow tract obstruction, consistent with hypertrophic obstructive cardiomyopathy (HOCM). As a consequence of the heart disease, the left atrium is also enlarged.

INTERPRETATION OF THE FINDINGS & FURTHER RECOMMENDATIONS

There are multiple layers of uncertainty regarding this case. The presence of hypertrophy and an outflow tract obstruction make the use of a beta blocker worth considering. The challenge of treating these cats is the lack of any real data to support a meaningful benefit (most of the rationale for their use is theoretical), coupled with the potential for adverse effects (low BP, renal impairment, potential



PATIENT

Mr Macho Carroll

SPECIES

Feline

BREED

Domestic Shorthair

SEX

Neutered male

AGE

4 years

WEIGHT

13.6 lbs

INTERPRETED BY

Bradley Harris, DVM,
DACVECC, DACVIM
(cardiology)

IMAGING PERFORMED BY

Vincent Ravancho,
CVT

HOSPITAL NAME

The Venturing Vet

REFERRING VET

Dr. Herzog

INVOICE

73860

DATE

3/26/26

exacerbation of CHF). If atenolol is used, the atenolol dose would be 1-2 mg/kg once daily (with the potential of increasing to BID if well tolerated after the first week). Given the presence of significant left atrial dilation, beta-blockers are recommended at this time. However, beta blockers do have the potential to worsen hemodynamic function, which is more of a concern in the setting of left atrial dilation. In these cases, the concurrent use of an ACEi (enalapril/benazepril 0.5mg/kg q24hr) is recommended as well. Additionally, Plavix/clopidogrel should be initiated as an anti-thrombotic (1/4 of a 75 mg tablet, or 18.75 mg PO q 24 h). Due to the bitter taste of this medication, it may be best to place it in an empty gelatin capsule or use products such as a Pill Pocket. A recheck heart rate, BP, and chemistry would be indicated 1-2 weeks after starting therapy; at that time the need for higher doses of atenolol can be assessed. A repeat echocardiogram, thoracic radiographs, blood pressure, and chemistry panel is warranted in another 6 months. Owners should monitor resting respiratory rate at home. Values above 30 breaths/minute or an increase in respiratory rate 10% above baseline should prompt veterinary re-evaluation.

Anesthesia considerations:

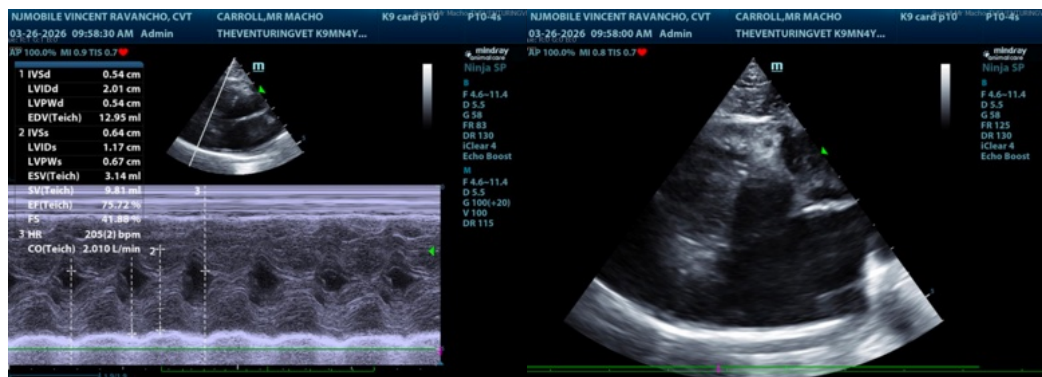
While there is no CHF present, there is likely an increased anesthetic risk which must be considered prior to any anesthetic procedure. If anesthesia is necessary, then alpha-2 agonists, ketamine, high dose acepromazine, and Telazol should be avoided. If an ACE inhibitor (enalapril, benazepril) or beta-blocker (atenolol) is being given, it should not be administered on the morning of general anesthesia. Other cardiac medications should be administered per the normal dosing schedule. Fluid therapy during anesthesia should be considered at a reduced rate (e.g., 2-3 ml/kg/hour) if possible (i.e., if not hypotensive). A shorter anesthetic duration will reduce the risk of complications. Pre-oxygenation is advised. Premedication with an opioid (i.e., butorphanol, hydromorphone, oxymorphone) with or without a benzodiazepine is generally the safest protocol. An induction agent such as Propofol, alfaxalone, or diazepam/etomidate can be used to effect. Maintenance of anesthesia with isoflurane or sevoflurane is reasonable.

Diet:

No special considerations are necessary. Any high-quality food from Hills, Royal Canin, Science Diet, Eukanuba, Iams, or Purina is reasonable.

Activity:

Avoid overly strenuous activity.





PATIENT

Mr Macho Carroll

SPECIES

Feline

BREED

Domestic Shorthair

SEX

Neutered male

AGE

4 years

WEIGHT

13.6 lbs

INTERPRETED BY

Bradley Harris, DVM,
 DACVECC, DACVIM
 (cardiology)

IMAGING PERFORMED BY

Vincent Ravancho,
 CVT

HOSPITAL NAME

The Venturing Vet

REFERRING VET

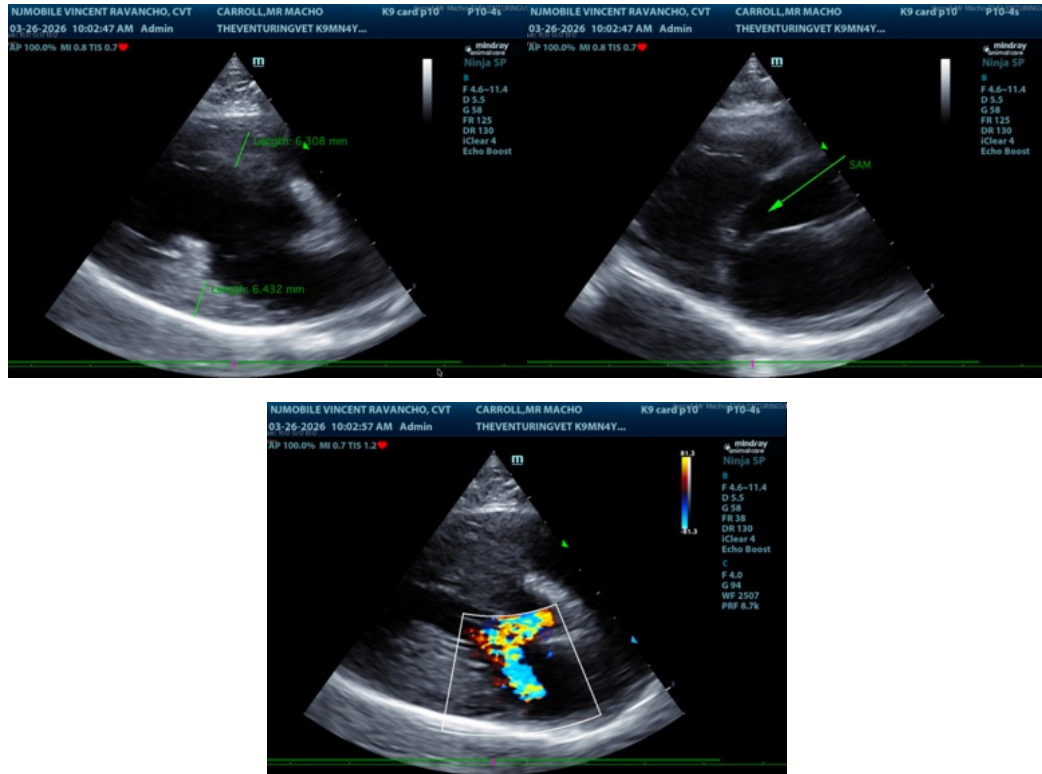
Dr. Herzog

INVOICE

73860

DATE

3/26/26



The information and recommendations provided are based on the images presented by the referring veterinarian/sonographer. No evaluation can be communicated regarding pathology that was not visible in the image/video clips provided.

Thank you for this referral. If the clinical or image interpretation does not parallel your findings or if I can be of any further assistance please contact me.

Bradley Harris, DVM, DACVECC, DACVIM (cardiology)

info@SonoPath.com