



PATIENT

Willow Choudary

SPECIES

Canine

BREED

Maltese

SEX

Spayed female

AGE

10 years

WEIGHT

15 lbs

INTERPRETED BY

Bradley Harris, DVM,
DACVECC, DACVIM
(cardiology)

IMAGING PERFORMED BY

Chloe Lowe

HOSPITAL NAME

Farview AC

REFERRING VET

Dr. Mosaad

INVOICE

72086

DATE

3/2/26

PRESENTING CLINICAL SIGNS

- chronic bronchitis
- evaluate adrenals
- Current Medications: Vetmedin 1.25mg bid

ULTRASONOGRAPHIC EXAMINATION OF THE HEART

The left atrium is normal in dimension. The left ventricle is normal in dimension, with normal systolic function. The right atrium and ventricle are normal in dimension, with normal systolic function. The anterior and posterior mitral valve leaflets are thickened and redundant consistent with myxomatous changes, and there is no significant prolapse. There is mild mitral regurgitation identified. The tricuspid valve leaflets are thickened and redundant, with mild tricuspid regurgitation and evidence of mild pulmonary hypertension. The left ventricular outflow tract demonstrated normal laminar flow and the visible aorta is unremarkable. The right ventricular outflow tract assessment revealed normal laminar flow, and appropriate diameter and distensibility. There is no pulmonic and no aortic valve insufficiency identified. There is no visible pericardial, pleural, or free peritoneal fluid documented. No evidence of hepatic venous congestion is noted. The cardiac chambers, pericardial and visible extra-cardiac regions were free of masses, spontaneous echo contrast, or thrombi.

CANINE CARDIAC PARAMETERS	Body Weight kg	HR BPM	LAD 4 ch Long	RAD 4 ch Long	La/Ao Heart Base	LVIDd	LVIDs
NORMAL PARAMETER		50-100			<1.6		
PATIENT	6.82 kg	130	2.63	2.23	1.32	2.18	1.73
CANINE CARDIAC PARAMETERS	FS	EPSS	PV V MAX (m/s)	AV V Max (m/sec)	MR Vmax	TR Vmax	RPA distensibility (normal >30%)
NORMAL PARAMETER	28-40	<0.6	0.7-1.6	0.7-1.7	4.5-5.5	< 2.7	
PATIENT	21	0.3	1.0	1.1	5.0	3.2	NM

ULTRASONOGRAPHIC FINDINGS

These findings identify degenerative mitral valve disease with minimal to no hemodynamic effects in the presence of mild pulmonary hypertension (PH). In the absence of more convincing left sided enlargement, the PH is more likely related to primary respiratory disease or other etiology (non-type 2 PH). Pulmonary hypertension in dogs is most commonly secondary to primary respiratory disease (chronic bronchitis, pulmonary fibrosis, or other forms of pulmonary interstitial disease). Pulmonary hypertension can also develop in dogs with severe heartworm disease or secondary to pulmonary thromboembolism (PTE). Less commonly, pulmonary hypertension is identified in dogs as an idiopathic condition.



PATIENT

Willow Choudary

SPECIES

Canine

BREED

Maltese

SEX

Spayed female

AGE

10 years

WEIGHT

15 lbs

INTERPRETED BY

Bradley Harris, DVM,
DACVECC, DACVIM
(cardiology)

IMAGING PERFORMED BY

Chloe Lowe

HOSPITAL NAME

Farview AC

REFERRING VET

Dr. Mosaad

INVOICE

72086

DATE

3/2/26

INTERPRETATION OF THE FINDINGS & FURTHER RECOMMENDATIONS

Given these findings, no changes or additions to cardiac therapy are recommended. There are no cardiac contraindications to anesthesia, fluid therapy, vasopressor therapy, or corticosteroids as indicated for further assessment and treatment. If not already performed, baseline thoracic radiographs and blood pressure are recommended. A recheck echocardiogram is recommended in 6 months.

Anesthesia considerations:

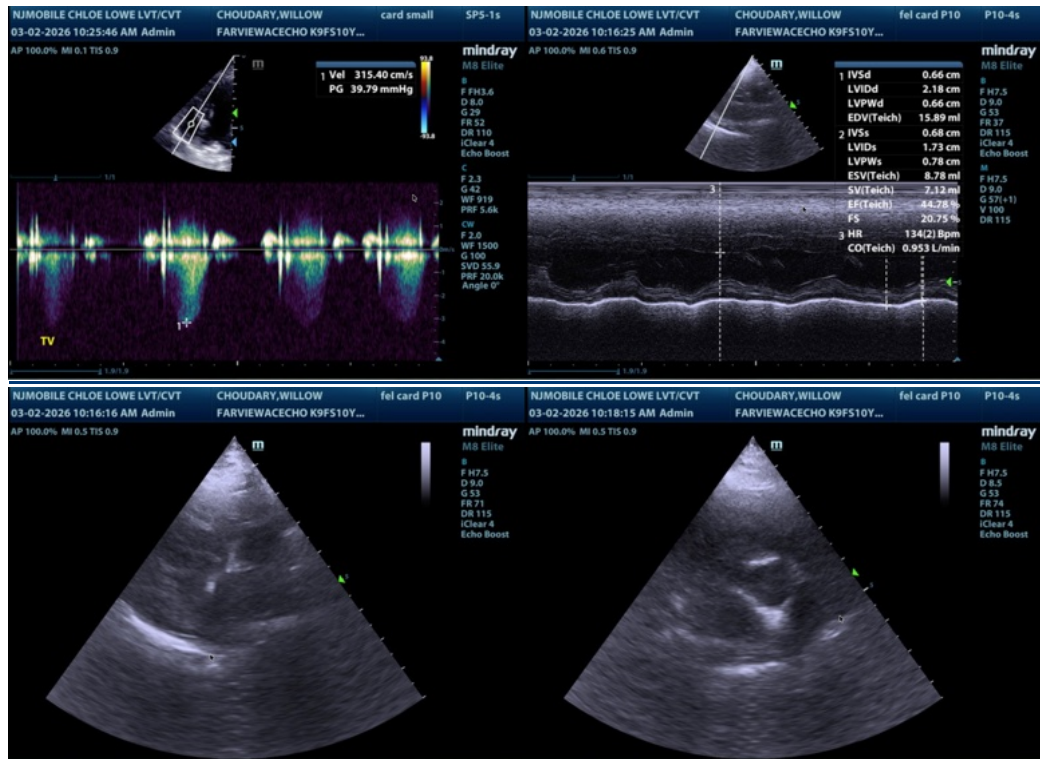
If anesthesia is necessary, alpha-2 agonists, ketamine, high dose acepromazine, and Telazol should be avoided. Fluid therapy during anesthesia should be considered at a conservative rate (e.g., 5 ml/kg/hour) if possible.

Diet:

A high-quality food from Hills, Royal Canin, Science Diet, Eukanuba, Iams, or Purina that is highly palatable with adequate protein and calories for maintaining optimal body condition is reasonable.

Activity:

No special considerations are necessary.





PATIENT

Willow Choudary

SPECIES

Canine

BREED

Maltese

SEX

Spayed female

AGE

10 years

WEIGHT

15 lbs

INTERPRETED BY

Bradley Harris, DVM,
 DACVECC, DACVIM
 (cardiology)

IMAGING PERFORMED BY

Chloe Lowe

HOSPITAL NAME

Farview AC

REFERRING VET

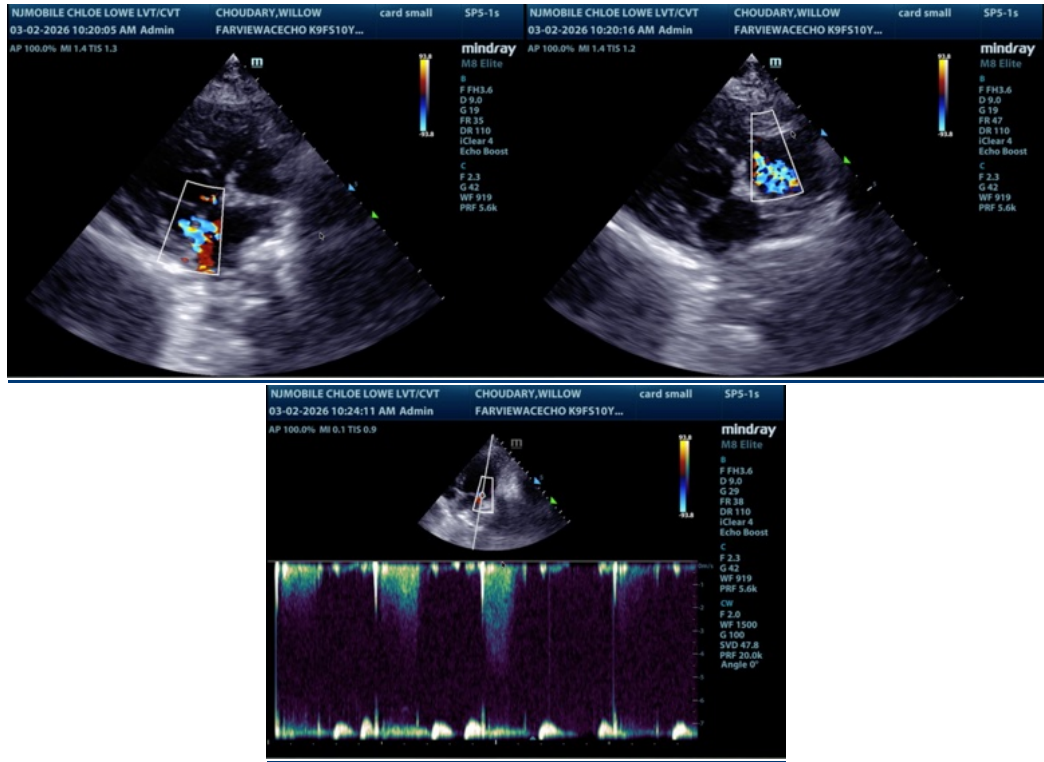
Dr. Mosaad

INVOICE

72086

DATE

3/2/26



The information and recommendations provided are based on the images presented by the referring veterinarian/sonographer. No evaluation can be communicated regarding pathology that was not visible in the image/video clips provided.

Thank you for this referral. If the clinical or image interpretation does not parallel your findings or if I can be of any further assistance please contact me.

Bradley Harris, DVM, DACVECC, DACVIM (cardiology)

info@SonoPath.com