



PATIENT

Rosie Rodriguez

SPECIES

Canine

BREED

Maltipoo

SEX

Spayed Female

AGE

8 year

WEIGHT

13.9 lbs

PRESENTING CLINICAL SIGNS

- Not eating, lethargic, was heavy breathing
- PE revealed mild wheezes in chest, Grade 5 heart murmur, xrays showed increased size of Left side of heart and poss. effusion of the left caudal lung.
- Meds: Furosemide 12.5 mg 1/2 tab Twice daily
- WBC 17.01 ^, HCT 58.27 ^, MCHC 30 dec. MPV 14.3 6, Neu 12.47 ^, Phos 2.6 dec. Gluc 171 ^

ULTRASONOGRAPHIC EXAMINATION OF THE HEART

The left atrium is normal in dimension. The left ventricle is normal in dimension with normal systolic function. The right atrium and ventricle are normal in dimension with normal systolic function. The anterior and posterior mitral valve leaflets are thickened and redundant consistent with myxomatous changes, and there is minimal prolapse. There is mild to moderate mitral regurgitation identified. The tricuspid valve leaflets are appropriately thin with adequate apposition and intact chordae, with no significant tricuspid regurgitation and no evidence of pulmonary hypertension. The left ventricular outflow tract demonstrated normal laminar flow and the visible aorta is unremarkable. The right ventricular outflow tract assessment revealed normal laminar flow and appropriate diameter and distensibility. There is no pulmonic and no aortic valve insufficiency identified. There is no visible pericardial, pleural, or free peritoneal fluid documented. No evidence of hepatic venous congestion is noted. The cardiac chambers, pericardial, and visible extra-cardiac regions were free of masses, spontaneous echo contrast, or thrombi.

INTERPRETED BY

Bradley Harris, DVM,
DACVECC, DACVIM
(cardiology)

IMAGING PERFORMED BY

Rebecca Hamilton

HOSPITAL NAME

Farview AC

REFERRING VET

Dr. Mosaad

INVOICE

73598

DATE

3/19/26

| CANINE CARDIAC PARAMETERS | Body Weight kg | HR BPM | LAD 4 ch Long | RAD 4 ch Long | La/Ao Heart Base | LVIDd | LVIDs |
|---------------------------|----------------|--------|----------------|------------------|------------------|---------|----------------------------------|
| NORMAL PARAMETER | | 50-100 | | | <1.6 | | |
| PATIENT | 6.32 | 1.4 | 2.65 | 2.06 | 1.34 | 2.5 | 1.22 |
| CANINE CARDIAC PARAMETERS | FS | EPSS | PV V MAX (m/s) | AV V Max (m/sec) | MR Vmax | TR Vmax | RPA distensibility (normal >30%) |
| NORMAL PARAMETER | 28-40 | <0.6 | 0.7-1.6 | 0.7-1.7 | 4.5-5.5 | < 2.7 | |
| PATIENT | 51 | 0.1 | 1.2 | 1.4 | 6.6 | NM | NM |

ULTRASONOGRAPHIC FINDINGS

These findings are consistent with degenerative/myxomatous mitral valve disease with minimal to mild hemodynamic effects consistent with ACVIM Stage B1 disease. It is unlikely that any current morbidity is of cardiac origin.



PATIENT

Rosie Rodriguez

SPECIES

Canine

BREED

Maltipoo

SEX

Spayed Female

AGE

8 year

WEIGHT

13.9 lbs

INTERPRETED BY

Bradley Harris, DVM,
 DACVECC, DACVIM
 (cardiology)

IMAGING PERFORMED BY

Rebecca Hamilton

HOSPITAL NAME

Farview AC

REFERRING VET

Dr. Mosaad

INVOICE

73598

DATE

3/19/26

INTERPRETATION OF THE FINDINGS & FURTHER RECOMMENDATIONS

Given these findings, no cardiac therapy is recommended. There are no cardiac contraindications to anesthesia, fluid therapy, vasopressor therapy, or corticosteroids as indicated for further assessment and treatment. If not already performed, baseline thoracic radiographs and blood pressure are recommended. A recheck echocardiogram is recommended in 6 months.

Anesthesia considerations:

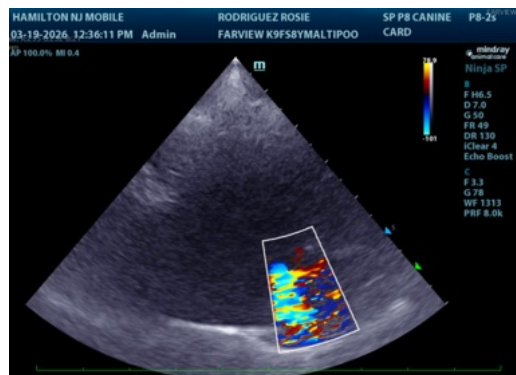
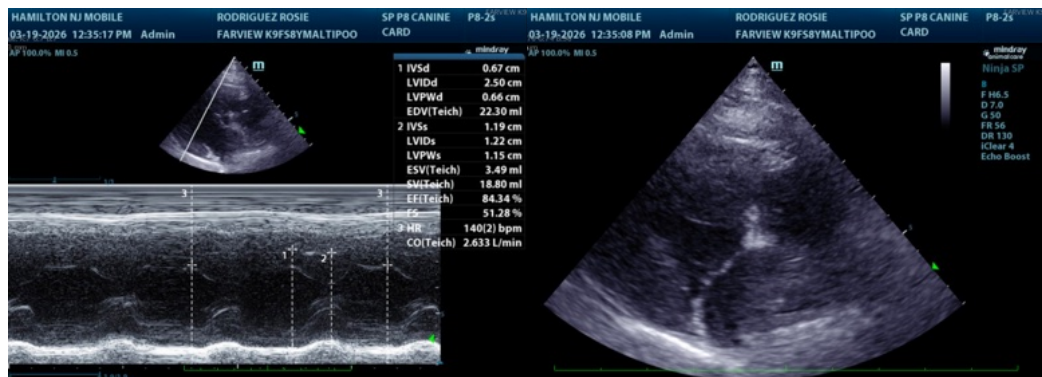
If anesthesia is necessary, alpha-2 agonists, ketamine, high dose acepromazine, and Telazol should be avoided. Fluid therapy during anesthesia should be considered at a conservative rate (e.g., 5 ml/kg/hour) if possible.

Diet:

A high-quality food from Hills, Royal Canin, Science Diet, Eukanuba, Iams, or Purina that is highly palatable with adequate protein and calories for maintaining optimal body condition is reasonable.

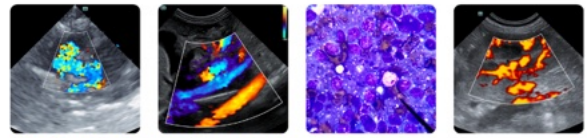
Activity:

No special considerations are necessary.



The information and recommendations provided are based on the images presented by the referring veterinarian/sonographer. No evaluation can be communicated regarding pathology that was not visible in the image/video clips provided.

Thank you for this referral. If the clinical or image interpretation does not parallel your findings or if I



PATIENT

Rosie Rodriguez

can be of any further assistance please contact me.

Bradley Harris, DVM, DACVECC, DACVIM (cardiology)

SPECIES

Canine

info@SonoPath.com

BREED

Maltipoo

SEX

Spayed Female

AGE

8 year

WEIGHT

13.9 lbs

INTERPRETED BY

Bradley Harris, DVM,
DACVECC, DACVIM
(cardiology)

**IMAGING
PERFORMED BY**

Rebecca Hamilton

HOSPITAL NAME

Farview AC

REFERRING VET

Dr. Mosaad

INVOICE

73598

DATE

3/19/26