



PATIENT

Lucky Kim

SPECIES

Canine

BREED

Maltese

SEX

Neutered male

AGE

13 years

WEIGHT

11.3 lbs

PRESENTING CLINICAL SIGNS

- Coughing over past 2 months.
- Was better on dx but C+ returned more frequent
- X-rays revealed slightly enlarged heart
- Was on Doxycycline 100mg 1/4th tab BID and Tamaril-P

ULTRASONOGRAPHIC EXAMINATION OF THE HEART

The left atrium is upper limits of normal to mildly enlarged. The left ventricle is normal in dimension with normal systolic function. The right atrium and ventricle are normal in dimension with normal systolic function. The anterior and posterior mitral valve leaflets are thickened and redundant consistent with myxomatous changes, and there is mild prolapse. There is mild to moderate mitral regurgitation identified. The tricuspid valve leaflets are thickened and redundant with mild tricuspid regurgitation and no evidence of pulmonary hypertension. The left ventricular outflow tract demonstrated normal laminar flow and the visible aorta is unremarkable. The right ventricular outflow tract assessment revealed normal laminar flow and appropriate diameter and distensibility. There is no pulmonic and moderate aortic valve insufficiency identified. There is no visible pericardial, pleural, or free peritoneal fluid documented. No evidence of hepatic venous congestion is noted. The cardiac chambers, pericardial, and visible extra-cardiac regions were free of masses, spontaneous echo contrast, or thrombi.

INTERPRETED BY

Bradley Harris, DVM,
 DACVECC, DACVIM
 (cardiology)

IMAGING PERFORMED BY

Vincent Ravancho,
 CVT

HOSPITAL NAME

Farview AC

REFERRING VET

Dr. Mosaad

INVOICE

73440

DATE

3/16/26

CANINE CARDIAC PARAMETERS	Body Weight kg	HR BPM	LAD 4 ch Long	RAD 4 ch Long	La/Ao Heart Base	LVIDd	LVIDs
NORMAL PARAMETER		50-100			<1.6		
PATIENT	5.14 kg	120	3.1	1.76	1.28	2.03	1.21
CANINE CARDIAC PARAMETERS	FS	EPSS	PV V MAX (m/s)	AV V Max (m/sec)	MR Vmax	TR Vmax	RPA distensibility (normal >30%)
NORMAL PARAMETER	28-40	<0.6	0.7-1.6	0.7-1.7	4.5-5.5	< 2.7	
PATIENT	40	0.2	1.0	1.4	5.5	2.2	51

ULTRASONOGRAPHIC FINDINGS

These findings are consistent with degenerative/myxomatous mitral valve disease with minimal to mild hemodynamic effects consistent with ACVIM Stage B1 disease. It is unlikely that any current morbidity is of cardiac origin.



PATIENT

Lucky Kim

SPECIES

Canine

BREED

Maltese

SEX

Neutered male

AGE

13 years

WEIGHT

11.3 lbs

INTERPRETED BY

Bradley Harris, DVM,
 DACVECC, DACVIM
 (cardiology)

IMAGING PERFORMED BY

Vincent Ravancho,
 CVT

HOSPITAL NAME

Farview AC

REFERRING VET

Dr. Mosaad

INVOICE

73440

DATE

3/16/26

INTERPRETATION OF THE FINDINGS & FURTHER RECOMMENDATIONS

Given these findings, no cardiac therapy is recommended. There are no cardiac contraindications to anesthesia, fluid therapy, vasopressor therapy, or corticosteroids as indicated for further assessment and treatment. If not already performed, baseline thoracic radiographs and blood pressure are recommended. A recheck echocardiogram is recommended in 6 months.

Anesthesia considerations:

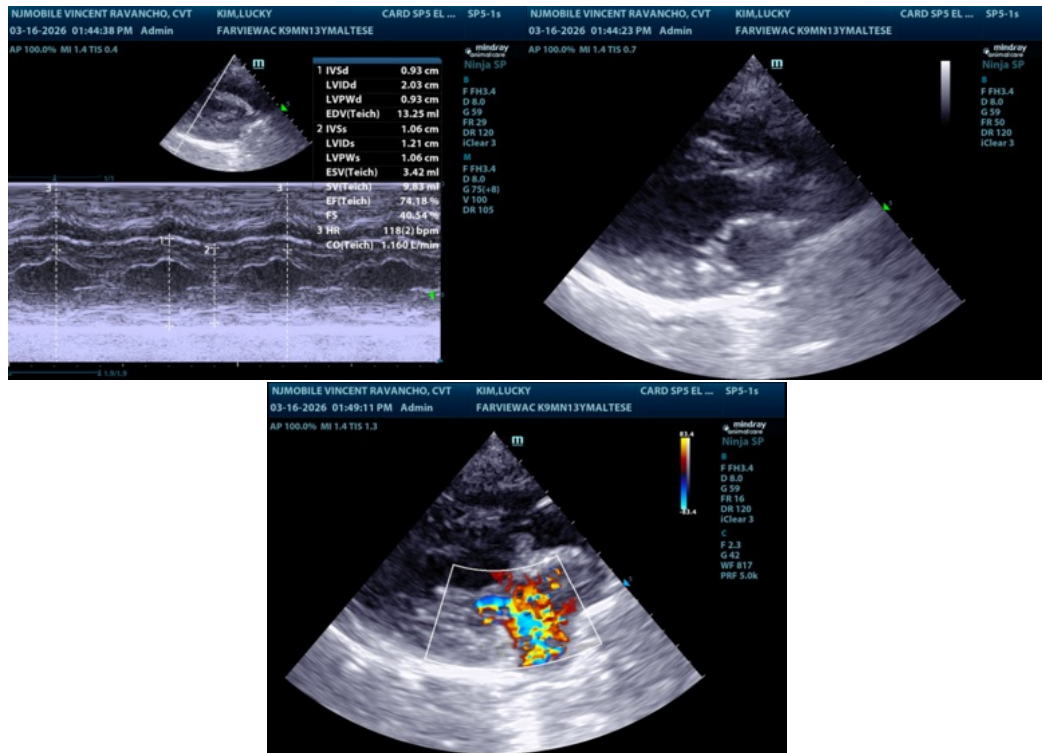
If anesthesia is necessary, alpha-2 agonists, ketamine, high dose acepromazine, and Telazol should be avoided. Fluid therapy during anesthesia should be considered at a conservative rate (e.g., 5 ml/kg/hour) if possible.

Diet:

A high-quality food from Hills, Royal Canin, Science Diet, Eukanuba, Iams, or Purina that is highly palatable with adequate protein and calories for maintaining optimal body condition is reasonable.

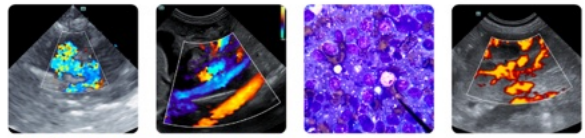
Activity:

No special considerations are necessary.



The information and recommendations provided are based on the images presented by the referring veterinarian/sonographer. No evaluation can be communicated regarding pathology that was not visible in the image/video clips provided.

Thank you for this referral. If the clinical or image interpretation does not parallel your findings or if I



PATIENT

Lucky Kim

SPECIES

Canine

BREED

Maltese

SEX

Neutered male

AGE

13 years

WEIGHT

11.3 lbs

INTERPRETED BY

Bradley Harris, DVM,
DACVECC, DACVIM
(cardiology)

**IMAGING
PERFORMED BY**

Vincent Ravancho,
CVT

HOSPITAL NAME

Farview AC

REFERRING VET

Dr. Mosaad

INVOICE

73440

DATE

3/16/26

can be of any further assistance please contact me.

Bradley Harris, DVM, DACVECC, DACVIM (cardiology)

info@SonoPath.com