



PATIENT

Momo Liu

SPECIES

Canine

BREED

Mix

SEX

Neutered male

AGE

9 year

WEIGHT

13 lbs

INTERPRETED BY

Bradley Harris, DVM,
DACVECC, DACVIM
(cardiology)

IMAGING PERFORMED BY

Rebecca Hamilton

HOSPITAL NAME

Marsh AH

REFERRING VET

Dr. Armani

INVOICE

71744

DATE

2/19/26

PRESENTING CLINICAL SIGNS

- Needs to have growth resection
- Hx murmur grade 3, coughs
- hx of tracheal collapse
- Meds: Hydrocodone
- Spleen prev. removed
- USG 1.037, Glob 4.0 (1.6-3.6) AST 13 (15-66) PLT 938 (170-400)

ULTRASONOGRAPHIC EXAMINATION OF THE HEART

The left atrium is normal in dimension. The left ventricle is normal in dimension, with normal systolic function. The right atrium and ventricle are normal in dimension, with normal systolic function. The anterior and posterior mitral valve leaflets are thickened and redundant consistent with myxomatous changes, and there is moderate prolapse. There is mild to moderate mitral regurgitation identified. The tricuspid valve leaflets are thickened and redundant, with moderate tricuspid regurgitation and evidence of moderate pulmonary hypertension. The left ventricular outflow tract demonstrated normal laminar flow and the visible aorta is unremarkable. The right ventricular outflow tract assessment revealed normal laminar flow, appropriate diameter and decreased distensibility. There is no pulmonic and no aortic valve insufficiency identified. There is no visible pericardial, pleural, or free peritoneal fluid documented. No evidence of hepatic venous congestion is noted. The cardiac chambers, pericardial and visible extra-cardiac regions were free of masses, spontaneous echo contrast, or thrombi.

CANINE CARDIAC PARAMETERS	Body Weight kg	HR BPM	LAD 4 ch Long	RAD 4 ch Long	La/Ao Heart Base	LVIDd	LVIDs
NORMAL PARAMETER		50-100			<1.6		
PATIENT	5.91 kg	100	2.41	1.87	1.06	2.51	1.67
CANINE CARDIAC PARAMETERS	FS	EPSS	PV V MAX (m/s)	AV V Max (m/sec)	MR Vmax	TR Vmax	RPA distensibility (normal >30%)
NORMAL PARAMETER	28-40	<0.6	0.7-1.6	0.7-1.7	4.5-5.5	< 2.7	
PATIENT	37	0.3	0.9	1.0	5.9	3.9	15

ULTRASONOGRAPHIC FINDINGS

These findings identify significant pulmonary hypertension (PH) in the absence of any clinically relevant left sided disease, making the PH more likely related to primary respiratory disease or other etiology (non-type 2 PH). Pulmonary hypertension in dogs is most commonly secondary to primary respiratory disease (chronic bronchitis, pulmonary fibrosis, or other forms of pulmonary interstitial disease).



PATIENT

Momo Liu

SPECIES

Canine

BREED

Mix

SEX

Neutered male

AGE

9 year

WEIGHT

13 lbs

INTERPRETED BY

Bradley Harris, DVM,
DACVECC, DACVIM
(cardiology)

IMAGING PERFORMED BY

Rebecca Hamilton

HOSPITAL NAME

Marsh AH

REFERRING VET

Dr. Armani

INVOICE

71744

DATE

2/19/26

Pulmonary hypertension can also develop in dogs with severe heartworm disease or secondary to pulmonary thromboembolism (PTE). Less commonly, pulmonary hypertension is identified in dogs as an idiopathic condition. Pulmonary hypertension commonly causes syncope, and a patient's signs may be attributable to this condition.

INTERPRETATION OF THE FINDINGS & FURTHER RECOMMENDATIONS

No cardiac therapy is indicated at this time. Treatment for the PH/presumed respiratory disease is warranted, as clinical signs are present. The use of sildenafil (2 mg/kg BID) and +/-theophylline (10 mg/kg BID) is appropriate. The merits of an airway scope/wash should be discussed with the owner, especially prior to any steroid use. A repeat echo is indicated in another 6 months, or sooner if progression is suspected, clinical signs develop/worsen, or cardiac therapy is being contemplated.

Anesthesia considerations:

While there is no CHF present, there is likely an increased anesthetic risk which must be considered prior to any anesthetic procedure. If anesthesia is necessary, then alpha-2 agonists, ketamine, and Telazol should be avoided. Fluid therapy during anesthesia does not necessarily need to be adjusted. A shorter anesthetic duration will reduce the risk of complications. Pre-oxygenation is mandatory. Premedication with an opioid (e.g., butorphanol, hydromorphone, oxymorphone) with or without a benzodiazepine is generally the safest protocol. An induction agent such as Propofol, alfaxalone, or diazepam/etomidate can be used to effect. Maintenance of anesthesia with isoflurane or sevoflurane is reasonable.

Diet:

No special considerations are necessary. Any high-quality food from Hills, Royal Canin, Science Diet, Eukanuba, Iams, or Purina is reasonable.

Activity:

Moderate physical activity (meandering walks, exploring the backyard, playing with toys inside, getting excited when family gets home, etc.) is encouraged, but periods of strenuous aerobic activity (jogging, strenuous outdoor ball play, prolonged play at the dog park, etc.) should be avoided, especially during periods of high heat (> 80 F) and humidity. Dogs with heart disease tend to tolerate cool and cold temperatures much better than high temperatures. Avoid sudden increases in activity (e.g. 2 block walks during the week but 2 mile walks followed by 30 minutes at the dog park on the weekends) as this may be difficult for the cardiovascular system to deal with.



PATIENT

Momo Liu

SPECIES

Canine

BREED

Mix

SEX

Neutered male

AGE

9 year

WEIGHT

13 lbs

INTERPRETED BY

Bradley Harris, DVM,
 DACVECC, DACVIM
 (cardiology)

IMAGING PERFORMED BY

Rebecca Hamilton

HOSPITAL NAME

Marsh AH

REFERRING VET

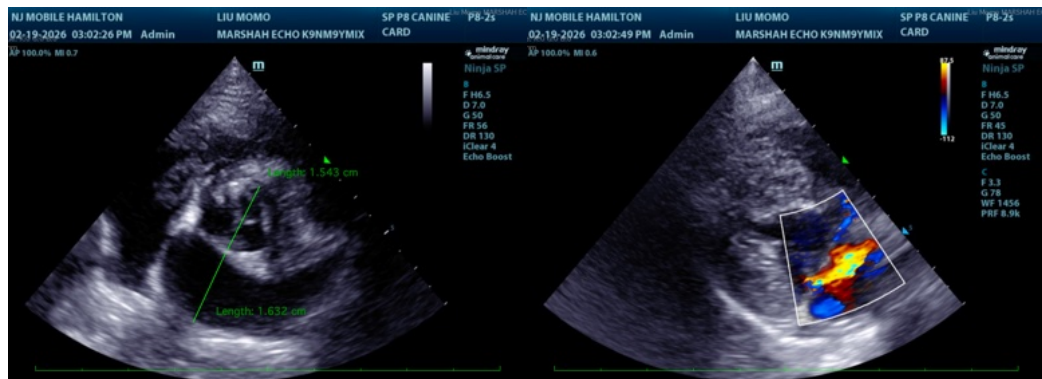
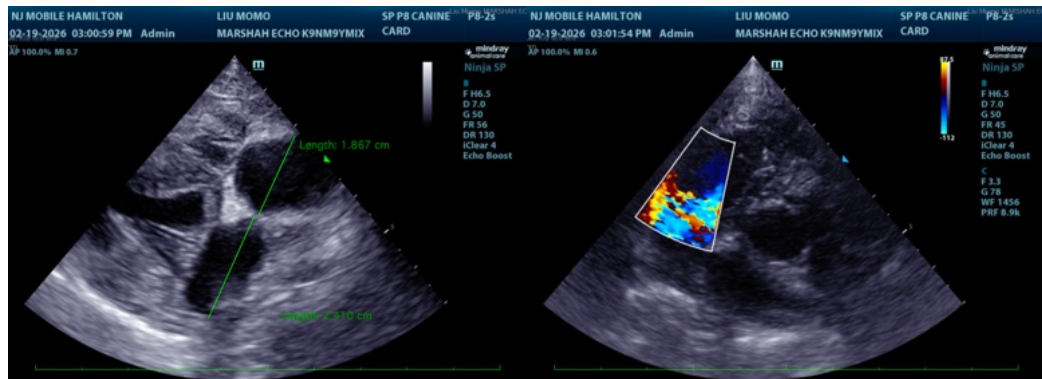
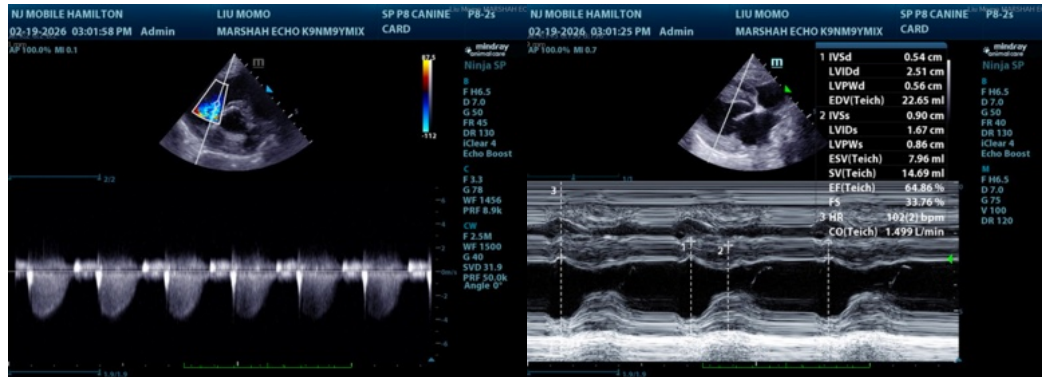
Dr. Armani

INVOICE

71744

DATE

2/19/26



The information and recommendations provided are based on the images presented by the referring veterinarian/sonographer. No evaluation can be communicated regarding pathology that was not visible in the image/video clips provided.

Thank you for this referral. If the clinical or image interpretation does not parallel your findings or if I can be of any further assistance please contact me.

Bradley Harris, DVM, DACVECC, DACVIM (cardiology)

info@SonoPath.com