



**PATIENT**

Harley Hudak

**SPECIES**

Feline

**BREED**

Domestic Shorthair

**SEX**

Spayed female

**AGE**

14 years

**WEIGHT**

7.3 lbs

**INTERPRETED BY**

Bradley Harris, DVM,  
DACVECC, DACVIM  
(cardiology)

**IMAGING PERFORMED BY**

Vincent Ravancho,  
CVT

**HOSPITAL NAME**

St George VH

**REFERRING VET**

Dr. Patel

**INVOICE**

71763

**DATE**

2/19/26

**PRESENTING CLINICAL SIGNS**

- Grade 3/6 HM
- Recurrent UTI. Blood Clot in Urine. AXR: no bladder stone
- Medications - Miralax, Amoxicillin
- U/A: trace protein, blood 3+, WBC 4-10, USG 1.033 Urine culture E.Coli, lab: NSF

**ULTRASONOGRAPHIC EXAMINATION OF THE HEART**

The left atrium is normal in dimension. There are no distinct left atrial thrombi/clots or spontaneous echo contrast appreciated. The left ventricle is normal in dimension as well as wall thickness, and no evidence of restriction. Left ventricular systolic function is normal, with adequate contractility based on fractional shortening and systolic left ventricular dimensions. The right atrium and ventricle are subjectively normal in dimension and systolic function. There is evidence of a dynamic left ventricular outflow tract obstruction (mid-systolic narrowing/pinch) with no mitral regurgitation. The tricuspid valve leaflets presented normal linear structure, extension in systole, and union in diastole without regurgitation. The left ventricular outflow tract demonstrated turbulent flow and subjective structural valvular integrity. The visible aorta is unremarkable. Pulmonary outflow tract assessment revealed normal valve structure, laminar flow, and appropriate diameter and distensibility. There is no evidence of semilunar valve insufficiency or pulmonary hypertension documented. There is no visible pericardial, pleural, or free peritoneal fluid noted.

FELINE CARDIAC PARAMETERS	BODY WEIGHT (kg)	HR (BPM)	IVSd (cm)	LVIDd (cm)	LVWd (cm)	FS (%)	EF (%)
NORMAL PARAMETER	-----	150-240	0.3-0.6	1.0-2.1	0.25-0.6	35-67	80-100
PATIENT	3.32 kg	140	0.52	1.67	0.54	40	74
FELINE CARDIAC PARAMETERS	LA/AO (M-mode)	LA/AO HEART BASE (Sisson)	LAD LA MAX 4 Chamber		LVOT VEL. (m/s)	RVOT VEL. (m/s)	IVRT (m/)
NORMAL PARAMETER	<1.5	1.6	0.7-1.7		<1.6	<1.3	40-60
PATIENT	1.46	1.34	1.5		1.2	1.0	NM
Adapted from June Boon, Veterinary Echocardiography, 1998							
Sisson D et al. JVIM 1991; 5: 232, Jacobs et al. Am J Vet Res 1985; 46:1705							

**ULTRASONOGRAPHIC FINDINGS**

These findings are consistent with dynamic subaortic stenosis, as there is an outflow tract obstruction present, but no convincing hypertrophy is identified. It is unlikely that any of the clinical/radiographic signs are related to underlying heart disease.



**PATIENT**

Harley Hudak

**SPECIES**

Feline

**BREED**

Domestic Shorthair

**SEX**

Spayed female

**AGE**

14 years

**WEIGHT**

7.3 lbs

**INTERPRETATION OF THE FINDINGS & FURTHER RECOMMENDATIONS**

Given the absence of any underlying heart disease, no cardiac therapy will be recommended. In addition, there are no cardiac objections to fluid therapy or steroid use. Owing to the presence of an outflow tract obstruction, a follow up echo is recommended in another 6-12 months to make sure no progression has occurred.

Anesthesia considerations:

If anesthesia is necessary, then alpha-2 agonists, ketamine, high dose acepromazine, and Telazol should be avoided. Fluid therapy during anesthesia should be considered at a reduced rate (e.g., 5 ml/kg/hour) if possible (i.e., if not hypotensive). A shorter anesthetic duration will reduce the risk of complications. Pre-oxygenation is advised. Premedication with an opioid (i.e., butorphanol, hydromorphone, oxymorphone) with or without a benzodiazepine is generally the safest protocol. An induction agent such as Propofol, alfaxalone can be used to effect. Maintenance of anesthesia with isoflurane or sevoflurane is reasonable.

Diet:

No special considerations are necessary. Any high-quality food from Hills, Royal Canin, Science Diet, Eukanuba, Iams, or Purina is reasonable.

Activity:

No special considerations are necessary.

**INTERPRETED BY**

Bradley Harris, DVM,  
DACVECC, DACVIM  
(cardiology)

**IMAGING PERFORMED BY**

Vincent Ravancho,  
CVT

**HOSPITAL NAME**

St George VH

**REFERRING VET**

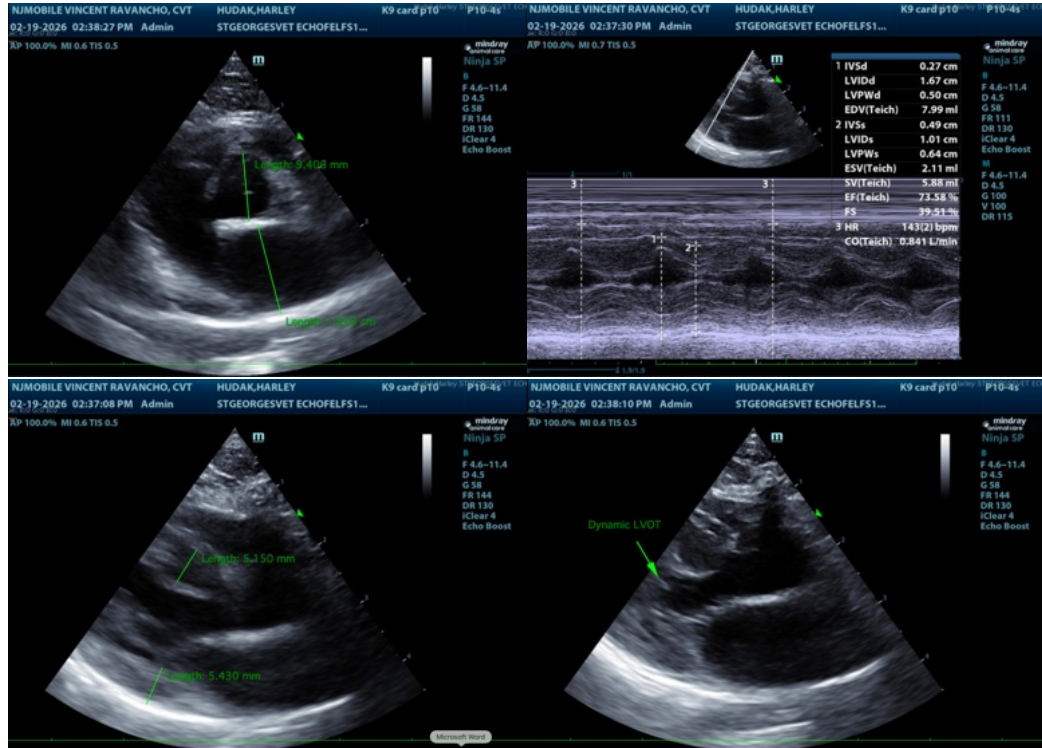
Dr. Patel

**INVOICE**

71763

**DATE**

2/19/26





**PATIENT**

Harley Hudak

**SPECIES**

Feline

**BREED**

Domestic Shorthair

**SEX**

Spayed female

**AGE**

14 years

**WEIGHT**

7.3 lbs

**INTERPRETED BY**

Bradley Harris, DVM,  
DACVECC, DACVIM  
(cardiology)

**IMAGING PERFORMED BY**

Vincent Ravancho,  
CVT

**HOSPITAL NAME**

St George VH

**REFERRING VET**

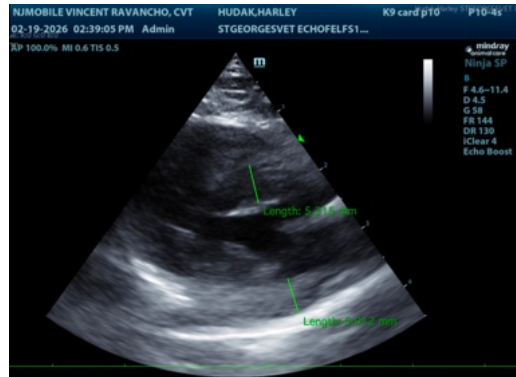
Dr. Patel

**INVOICE**

71763

**DATE**

2/19/26



The information and recommendations provided are based on the images presented by the referring veterinarian/sonographer. No evaluation can be communicated regarding pathology that was not visible in the image/video clips provided.

Thank you for this referral. If the clinical or image interpretation does not parallel your findings or if I can be of any further assistance please contact me.

Bradley Harris, DVM, DACVECC, DACVIM (cardiology)

[info@SonoPath.com](mailto:info@SonoPath.com)