



PATIENT

Jazzy Katowski

SPECIES

Feline

BREED

Exotic Shorthair

SEX

Spayed female

AGE

15 years

WEIGHT

7 lbs

PRESENTING CLINICAL SIGNS

- Newly auscultated gallop on routine exam
- BP 158
- Current meds: Clopidogrel 18.75mg SID, CoQ10 10mg SID, Amoxi 50mg BID, Methimazole (gallop resolved on increased dose)
- T4 abnormal

ULTRASONOGRAPHIC EXAMINATION OF THE HEART

The left atrium is mild to moderately enlarged. There are no distinct left atrial thrombi/clots or spontaneous echo contrast appreciated. The left ventricle is mildly enlarged with normal wall thickness, and no evidence of restriction. Left ventricular systolic function is marginal. The right atrium and ventricle are subjectively prominent with normal systolic function. The anterior and posterior mitral and tricuspid valve leaflets presented normal linear structure, extension in systole, and union in diastole with mild tricuspid regurgitation. There is no evidence of systolic anterior mitral motion documented. The left ventricular outflow tract demonstrated normal laminar flow and subjective structural valvular integrity. The visible aorta is unremarkable. Pulmonary outflow tract assessment revealed normal valve structure, laminar flow, and appropriate diameter and distensibility. There is no evidence of semilunar valve insufficiency or pulmonary hypertension documented. There is no visible pericardial, pleural, or free peritoneal fluid noted.

INTERPRETED BY

Bradley Harris, DVM,
 DACVECC, DACVIM
 (cardiology)

IMAGING PERFORMED BY

Meghan Morse, LVT,
 CVT

HOSPITAL NAME

Four Paws Holistic VH

REFERRING VET

Dr. Edoff

INVOICE

70334

DATE

1/20/26

FELINE CARDIAC PARAMETERS	BODY WEIGHT (kg)	HR (BPM)	IVSd (cm)	LVIDd (cm)	LVWd (cm)	FS (%)	EF (%)
NORMAL PARAMETER	-----	150-240	0.3-0.6	1.0-2.1	0.25-0.6	35-67	80-100
PATIENT	3.18 kg	NM	0.48	1.89	0.46	40	74
FELINE CARDIAC PARAMETERS	LA/AO (M-mode)	LA/AO HEART BASE (Sisson)	LAD LA MAX 4 Chamber	LVOT VEL. (m/s)	RVOT VEL. (m/s)	IVRT (m/)	
NORMAL PARAMETER	<1.5	1.6	0.7-1.7	<1.6	<1.3	40-60	
PATIENT	1.58	1.61	1.7	1.0	0.7	NM	
Adapted from June Boon, Veterinary Echocardiography, 1998 Sisson D et al. JVIM 1991; 5: 232, Jacobs et al. Am J Vet Res 1985; 46:1705							

ULTRASONOGRAPHIC FINDINGS

These findings identify left atrial dilation in the absence of any left ventricular hypertrophy or outflow tract obstruction. In the absence of any intrinsic disease (hyperthyroidism or severe anemia) or iatrogenic factors (steroid or fluid administration), these findings would be most consistent with the myocardial form of restrictive cardiomyopathy (RCM formerly unclassified).



PATIENT

Jazzy Katowski

SPECIES

Feline

BREED

Exotic Shorthair

SEX

Spayed female

AGE

15 years

WEIGHT

7 lbs

INTERPRETED BY

Bradley Harris, DVM,
DACVECC, DACVIM
(cardiology)

IMAGING PERFORMED BY

Meghan Morse, LVT,
CVT

HOSPITAL NAME

Four Paws Holistic VH

REFERRING VET

Dr. Edoff

INVOICE

70334

DATE

1/20/26

INTERPRETATION OF THE FINDINGS & FURTHER RECOMMENDATIONS

Therapy with Vetmedin (2.5mg BID) is reasonable at this time. Enalapril/benazepril (2.5mg q24) can also be considered, pending BP and kidney function. If an ACEi is started, a recheck chemistry panel and blood pressure should be performed 1-2 weeks after starting therapy. Additionally, Plavix/clopidogrel should be initiated as an anti-thrombotic (1/4 of a 75 mg tablet, or 18.75 mg PO q 24 h). Due to the bitter taste of this medication, it may be best to place it in an empty gelatin capsule or use products such as a Pill Pocket. Barring any setbacks or complications, a repeat echocardiogram, thoracic radiographs, blood pressure, and chemistry panel are indicated in another 3-6 months.

Anesthesia considerations:

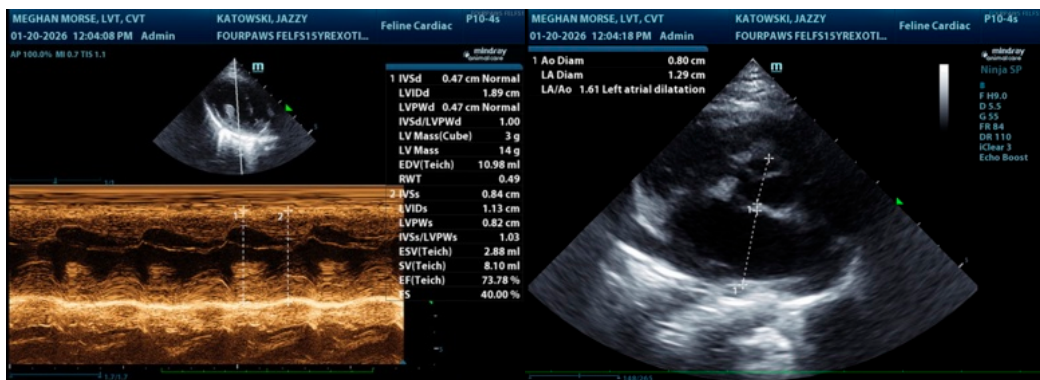
While there is no CHF present, there is likely an increased anesthetic risk which must be considered prior to any anesthetic procedure. If anesthesia is necessary, then alpha-2 agonists, ketamine, high dose acepromazine, and Telazol should be avoided. If an ACE inhibitor (enalapril, benazepril) or spironolactone is being given, it should not be administered on the morning of general anesthesia. Other cardiac medications should be administered per the normal dosing schedule. Fluid therapy during anesthesia should be considered at a reduced rate (e.g., 2-5 ml/kg/hour) if possible (i.e., if not hypotensive). A shorter anesthetic duration will reduce the risk of complications. Pre-oxygenation is advised. Premedication with an opioid (i.e., butorphanol, hydromorphone, oxymorphone) with or without a benzodiazepine is generally the safest protocol. An induction agent such as Propofol, alfaxalone, or diazepam/etomidate can be used to effect. Maintenance of anesthesia with isoflurane or sevoflurane is reasonable.

Diet:

No special considerations are necessary. Any high-quality food from Hills, Royal Canin, Science Diet, Eukanuba, Iams, or Purina is reasonable.

Activity:

Avoid strenuous activity.





PATIENT

Jazzy Katowski

SPECIES

Feline

BREED

Exotic Shorthair

SEX

Spayed female

AGE

15 years

WEIGHT

7 lbs

INTERPRETED BY

Bradley Harris, DVM,
 DACVECC, DACVIM
 (cardiology)

IMAGING PERFORMED BY

Meghan Morse, LVT,
 CVT

HOSPITAL NAME

Four Paws Holistic VH

REFERRING VET

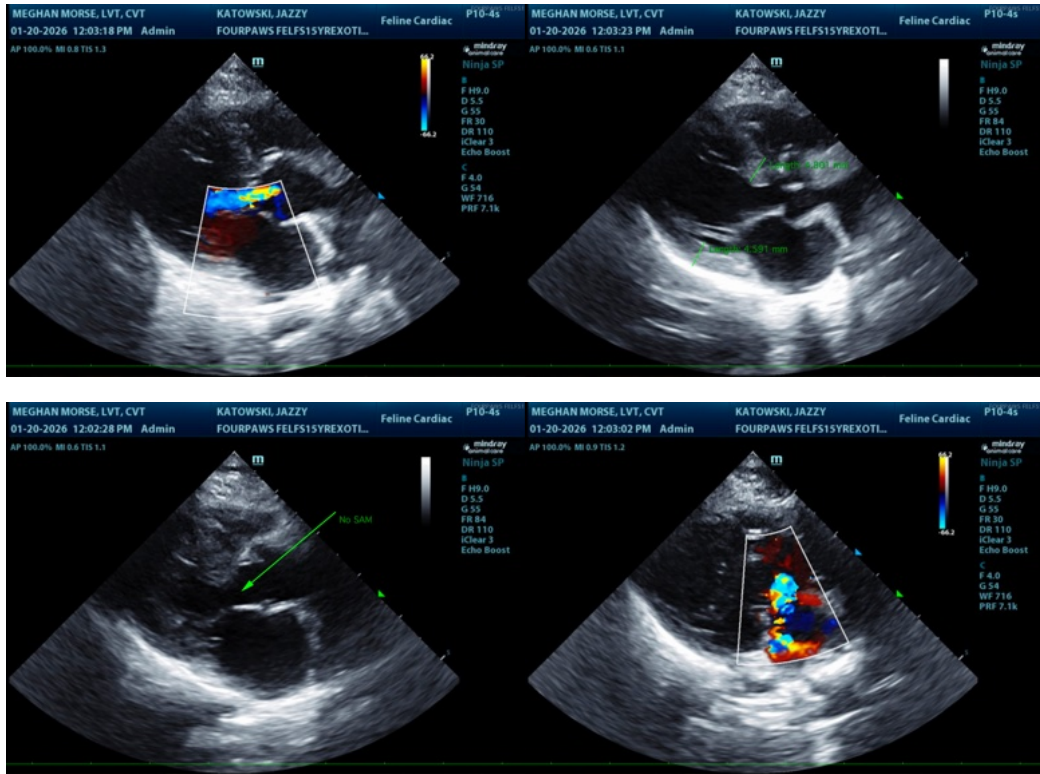
Dr. Edoff

INVOICE

70334

DATE

1/20/26



The information and recommendations provided are based on the images presented by the referring veterinarian/sonographer. No evaluation can be communicated regarding pathology that was not visible in the image/video clips provided.

Thank you for this referral. If the clinical or image interpretation does not parallel your findings or if I can be of any further assistance please contact me.

Bradley Harris, DVM, DACVECC, DACVIM (cardiology)

info@SonoPath.com