



PATIENT

Bonnie Fleming

SPECIES

Other

BREED

Chinchilla

SEX

Female

AGE

14 years

WEIGHT

0.77 kg

INTERPRETED BY

Bradley Harris, DVM,
DACVECC, DACVIM
(cardiology)

IMAGING PERFORMED BY

Kerri Becker

HOSPITAL NAME

Animal Care Center of
Flanders

REFERRING VET

Dr. Hallihan

INVOICE

70346

DATE

1/20/26

PRESENTING CLINICAL SIGNS

- Grade 3-4/6 systolic murmur L- side- losing weight

ULTRASONOGRAPHIC EXAMINATION OF THE HEART

The left atrium is normal in dimension. The left ventricle appears subjectively normal in dimension as well as wall thickness, and no evidence of restriction. Left ventricular systolic function is normal, with adequate contractility. The right atrium and ventricle are subjectively normal in dimension and systolic function. The anterior and posterior mitral and tricuspid valve leaflets presented normal linear structure, extension in systole, and union in diastole without regurgitation. The left ventricular outflow tract demonstrated normal laminar flow and subjective structural valvular integrity. The visible aorta is unremarkable. Pulmonary outflow tract assessment revealed normal valve structure, laminar flow, and appropriate diameter and distensibility. There is no evidence of pulmonary hypertension documented. There is no visible pericardial, pleural, or free peritoneal fluid noted.

CARDIAC PARAMETERS	BODY WEIGHT (kg)	HR (BPM)	IVSd (cm)	LVIDd (cm)	LVWd (cm)	FS (%)	EF (%)
NORMAL PARAMETER	-----					35-67	80-100
PATIENT	0.77 kg	240	0.25	0.87	0.25	43	79
CARDIAC PARAMETERS	LA/AO (M-mode)	LA/AO HEART BASE (Sisson)	LAD LA MAX 4 Chamber		LVOT VEL. (m/s)	RVOT VEL. (m/s)	IVRT (m)
NORMAL PARAMETER		1.6			<1.6	<1.3	
PATIENT	NM	1.21	NM		1.1	1.3	NM

Adapted from June Boon, Veterinary Echocardiography, 1998
Sisson D et al. JVIM 1991; 5: 232, Jacobs et al. Am J Vet Res 1985; 46:1705

ULTRASONOGRAPHIC FINDINGS

These findings are consistent with an essentially normal echocardiogram. The murmur will be considered functional in origin.

INTERPRETATION OF THE FINDINGS & FURTHER RECOMMENDATIONS

Given these findings, no cardiac therapy is recommended. There are no cardiac contraindications to corticosteroids or fluid therapy as indicated for further treatment. No specific recheck echocardiogram is recommended.

Anesthesia considerations:

No special cardiac considerations are necessary



PATIENT

Bonnie Fleming

SPECIES

Other

BREED

Chinchilla

SEX

Female

AGE

14 years

WEIGHT

0.77 kg

INTERPRETED BY

Bradley Harris, DVM,
 DACVECC, DACVIM
 (cardiology)

IMAGING PERFORMED BY

Kerri Becker

HOSPITAL NAME

Animal Care Center of
 Flanders

REFERRING VET

Dr. Hallihan

INVOICE

70346

DATE

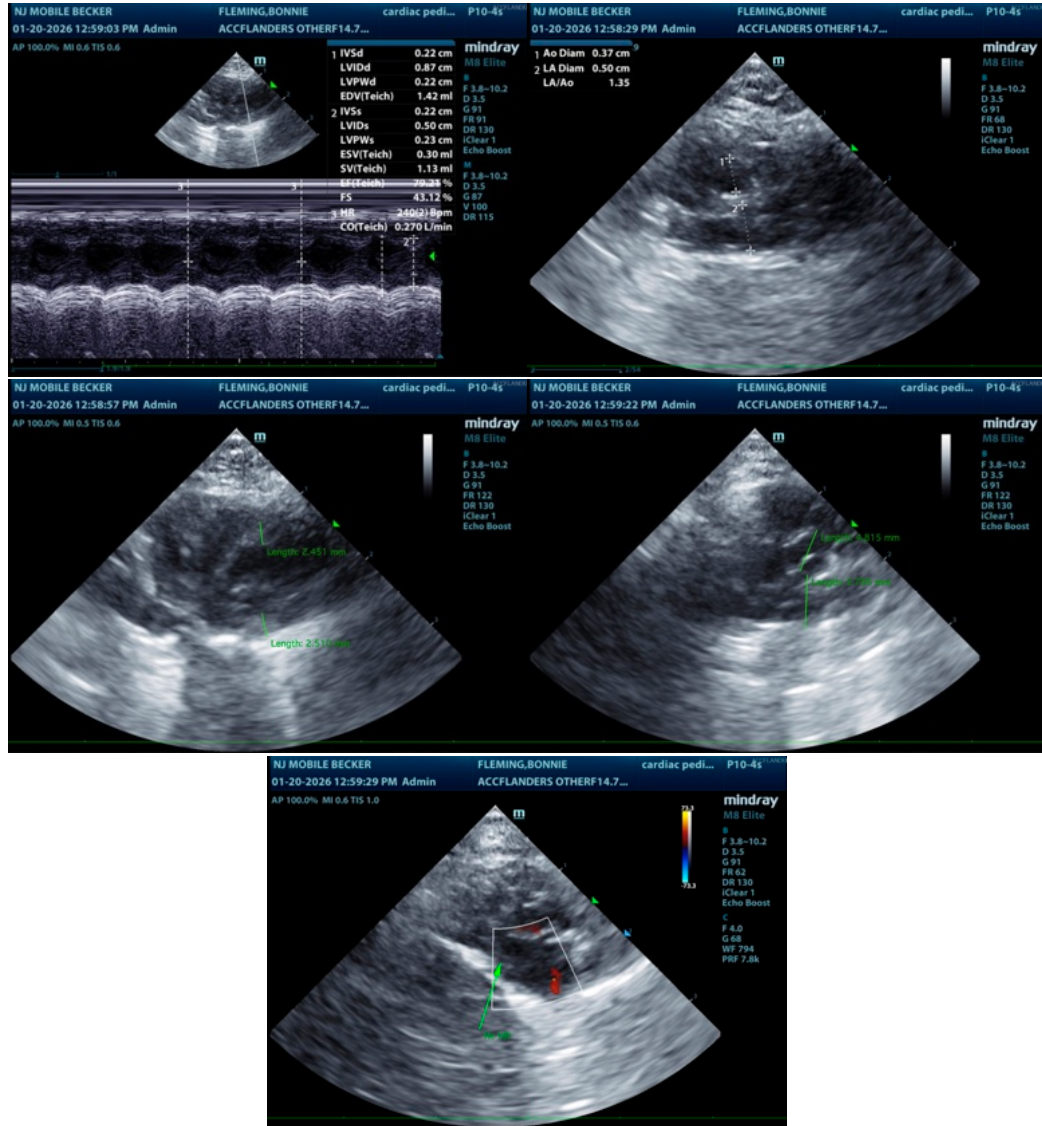
1/20/26

Diet:

No special considerations are necessary. Any high-quality food from Hills, Royal Canin, Science Diet, Eukanuba, Iams, or Purina is reasonable.

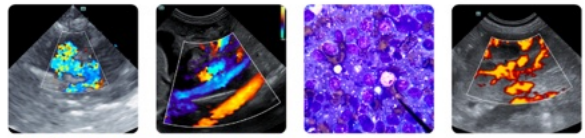
Activity:

No special considerations are necessary.



The information and recommendations provided are based on the images presented by the referring veterinarian/sonographer. No evaluation can be communicated regarding pathology that was not visible in the image/video clips provided.

Thank you for this referral. If the clinical or image interpretation does not parallel your findings or if I can be of any further assistance please contact me.



PATIENT

Bradley Harris, DVM, DACVECC, DACVIM (cardiology)

Bonnie Fleming

info@SonoPath.com

SPECIES

Other

BREED

Chinchilla

SEX

Female

AGE

14 years

WEIGHT

0.77 kg

INTERPRETED BY

Bradley Harris, DVM,
DACVECC, DACVIM
(cardiology)

**IMAGING
PERFORMED BY**

Kerri Becker

HOSPITAL NAME

Animal Care Center of
Flanders

REFERRING VET

Dr. Hallihan

INVOICE

70346

DATE

1/20/26