

PATIENT

Patches Ewert

SPECIES

Canine

BREED

Terrier Cross

SEX

Neutered male

AGE

13 years

WEIGHT

14.5 kg

INTERPRETED BY

Bradley Harris, DVM,
 DACVECC, DACVIM
 (cardiology)

IMAGING PERFORMED BY

Kelly Reschny

HOSPITAL NAME

Fairview AC

REFERRING VET

Dr. Combe

PRESENTING CLINICAL SIGNS

History: Presented for annual wellness 5-22-26. Had been a rescue from the US, previously HW + and treated with melarsomine prior to adoption. On a preventative until 2018 then was not on anything. HW and microfilaria + 5-22-2026.
 II/VI systolic HM, PMI left heart base, pulses synchronous, no arrhythmia. Moderate dental disease.
 Current Medications
 doxycycline 150mg q12h; prednisone 7.5 mg q12h (on for 1 week); Heartguard, bravecto
 Abnormal PE/Chem/CBC/UA Results: HW Ag + microfilaria 21-50/LPF mild increase BUN 11.2 mmol/L mild increase albumin 42g/L ALT increased 348 ALP increased 1911 Radiographic Findings
 VHS 11, enlarged r/o slight loss of caudal cardiac waist

ULTRASONOGRAPHIC EXAMINATION OF THE HEART

The left atrium is normal in dimension. The left ventricle is normal in dimension, with normal systolic function. The right atrium and ventricle are normal in dimension, with normal systolic function. The anterior and posterior mitral valve leaflets are thickened and redundant consistent with myxomatous changes, and there is no significant prolapse. There is mild mitral regurgitation identified. The tricuspid valve leaflets are minimally thickened, with trivial tricuspid regurgitation and no evidence of pulmonary hypertension. The left ventricular outflow tract demonstrated normal laminar flow and the visible aorta is unremarkable. The right ventricular outflow tract assessment revealed normal laminar flow, with appropriate main pulmonary artery diameter and right pulmonary artery distensibility. There is no pulmonic and no aortic valve insufficiency identified. There is no visible pericardial, pleural, or free peritoneal fluid documented. No evidence of hepatic venous congestion is noted. The cardiac chambers, pericardial and visible extra-cardiac regions were free of masses, spontaneous echo contrast, or thrombi.

CANINE CARDIAC PARAMETERS	Body Weight kg	HR BPM	LAD 4 ch Long	RAD 4 ch Long	La/Ao Heart Base	LVIDd	LVIDs
NORMAL PARAMETER		50-100			<1.6		
PATIENT	14.5 kg	NM	3.42	2.39	1.24	2.88	2.0
CANINE CARDIAC PARAMETERS	FS	EPSS	PV V MAX (m/s)	AV V Max (m/sec)	MR Vmax	TR Vmax	RPA distensibility (normal >30%)
NORMAL PARAMETER	28-40	<0.6	0.7-1.6	0.7-1.7	4.5-5.5	< 2.7	
PATIENT	31	0.4	1.3	1.7	6.3	1.2	34

INVOICE

78358

DATE

6/4/26

ULTRASONOGRAPHIC FINDINGS

These findings are consistent with degenerative/myxomatous mitral valve disease with minimal to mild hemodynamic effects consistent with ACVIM Stage B1 disease. There is no cardiac remodeling or pulmonary hypertension secondary to the historic heartworm infestation identified.



PATIENT

Patches Ewert

SPECIES

Canine

BREED

Terrier Cross

SEX

Neutered male

AGE

13 years

WEIGHT

14.5 kg

INTERPRETED BY

Bradley Harris, DVM,
 DACVECC, DACVIM
 (cardiology)

IMAGING PERFORMED BY

Kelly Reschny

HOSPITAL NAME

Fairview AC

REFERRING VET

Dr. Combe

INVOICE

78358

DATE

6/4/26

INTERPRETATION OF THE FINDINGS & FURTHER RECOMMENDATIONS

Given these findings, no cardiac therapy is recommended. There are no cardiac contraindications to anesthesia, fluid therapy, vasopressor therapy, or corticosteroids as indicated for further assessment and treatment. If not already performed, baseline thoracic radiographs and blood pressure are recommended. A recheck echocardiogram is recommended in 6 months.

Anesthesia considerations:

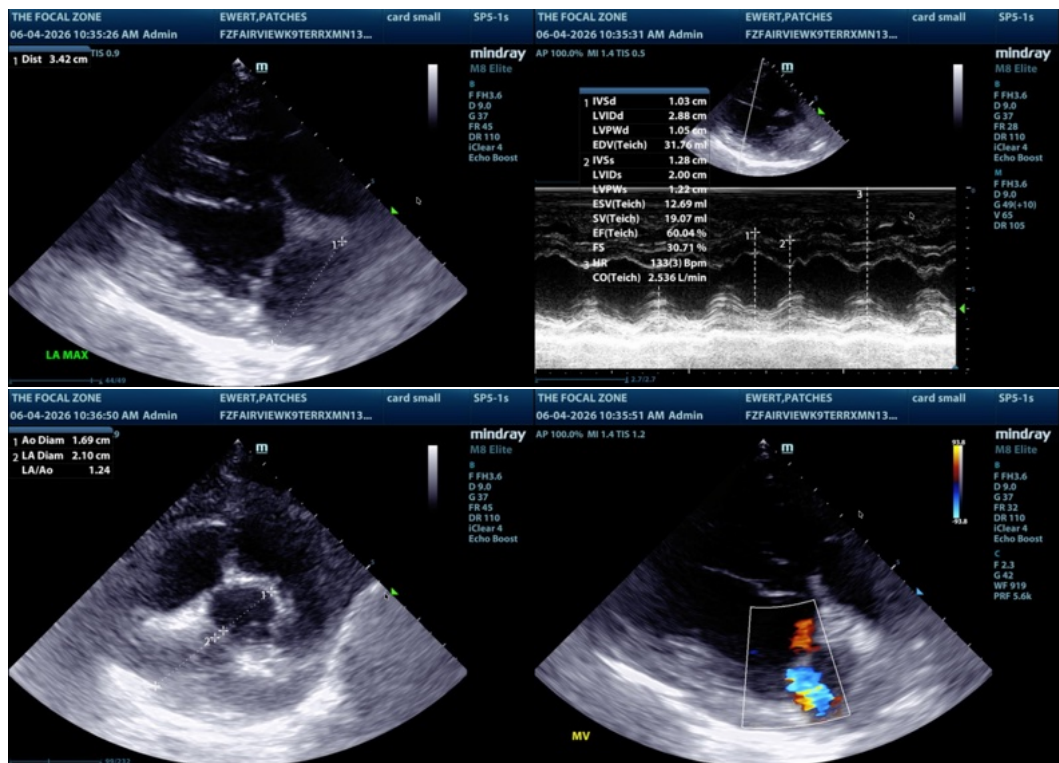
If anesthesia is necessary, alpha-2 agonists, ketamine, high dose acepromazine, and Telazol should be avoided. Fluid therapy during anesthesia should be considered at a conservative rate (e.g., 5 ml/kg/hour) if possible.

Diet:

A high-quality food from Hills, Royal Canin, Science Diet, Eukanuba, Iams, or Purina that is highly palatable with adequate protein and calories for maintaining optimal body condition is reasonable.

Activity:

No special considerations are necessary.



The information and recommendations provided are based on the images presented by the referring veterinarian/sonographer. No evaluation can be communicated regarding pathology that was not visible in the image/video clips provided.

Thank you for this referral. If the clinical or image interpretation does not parallel your findings or if I



PATIENT

Patches Ewert

SPECIES

Canine

BREED

Terrier Cross

SEX

Neutered male

AGE

13 years

WEIGHT

14.5 kg

INTERPRETED BY

Bradley Harris, DVM,
DACVECC, DACVIM
(cardiology)

**IMAGING
PERFORMED BY**

Kelly Reschny

HOSPITAL NAME

Fairview AC

REFERRING VET

Dr. Combe

INVOICE

78358

DATE

6/4/26

can be of any further assistance please contact me.

Bradley Harris, DVM, DACVECC, DACVIM (cardiology)

info@SonoPath.com