

**PATIENT PRESENTING CLINICAL SIGNS**

**Jake Gaspar** History: Grade 2/6 heart murmur, focal, cranial left, systolic (first noted Sept 2025)  
 No arrhythmia present on recheck Sept 24, 25  
**SPECIES** Recheck Feb 2026 and noted a grade 1/6 murmur only heard for a moment before he moved. No meds.  
 Assess for anesthetic safety.  
 Canine Abnormal PE/Chem/CBC/UA Results: Please read attached ECG

**BREED**

Canine

**SEX**

Boxer

**AGE**

3 years

**WEIGHT**

26.9 kg

**ULTRASONOGRAPHIC EXAMINATION OF THE HEART**

The left atrium is normal in dimension. The left ventricle is normal in dimension, with normal systolic function. The right atrium and ventricle are normal in dimension, with normal systolic function. The anterior and posterior mitral valve leaflets are appropriately thin with adequate apposition, intact chordae, and there is no significant prolapse. There is no significant mitral regurgitation identified. The tricuspid valve leaflets are appropriately thin with adequate apposition, intact chordae, no significant tricuspid regurgitation and no evidence of pulmonary hypertension. The left ventricular outflow tract demonstrated normal laminar flow and the visible aorta is unremarkable. The right ventricular outflow tract assessment revealed normal laminar flow, with appropriate main pulmonary artery diameter and right pulmonary artery distensibility. There is no pulmonic and no aortic valve insufficiency identified. There is no visible pericardial, pleural, or free peritoneal fluid documented. No evidence of hepatic venous congestion is noted. The cardiac chambers, pericardial and visible extra-cardiac regions were free of masses, spontaneous echo contrast, or thrombi.

**INTERPRETED BY**

Bradley Harris, DVM,  
 DACVECC, DACVIM  
 (cardiology)

**IMAGING PERFORMED BY**

Crystal Hill

**HOSPITAL NAME**

Main Street AH

**REFERRING VET**

Dr. Murphy

**INVOICE**

78326

**DATE**

6/3/26

CANINE CARDIAC PARAMETERS	Body Weight kg	HR BPM	LAD 4 ch Long	RAD 4 ch Long	La/Ao Heart Base	LVIDd	LVIDs
NORMAL PARAMETER		50-100			<1.6		
PATIENT	26.9 kg	NM	3.92	NM	1.45	3.51	2.54
CANINE CARDIAC PARAMETERS	FS	EPSS	PV V MAX (m/s)	AV V Max (m/sec)	MR Vmax	TR Vmax	RPA distensibility (normal >30%)
NORMAL PARAMETER	28-40	<0.6	0.7-1.6	0.7-1.7	4.5-5.5	< 2.7	
PATIENT	28	NM	1.5	2.2	NM	NM	NM

ECG:

The underlying rhythm is sinus in origin with a varying R-R interval and average heart rate of 110bpm. The majority of the QRS complexes are supraventricular in origin with consistent P-Q intervals. There are rare (1) QRS complexes that are prolonged in duration (>70ms), suggesting a ventricular origin. There is no evidence of atrioventricular block or atrial ectopy identified. This is most consistent with a respiratory sinus arrhythmia with rare ventricular ectopy.

**ULTRASONOGRAPHIC FINDINGS**

These findings are consistent with an essentially normal echocardiogram. Any murmur will be considered functional in origin (dynamic left and right ventricular outflow tracts). No cardiac cause of the morbidity is identified. Ventricular arrhythmias occur in many clinical settings, generally divided



**PATIENT**

Jake Gaspar

**SPECIES**

Canine

**BREED**

Canine

**SEX**

Boxer

**AGE**

3 years

**WEIGHT**

26.9 kg

**INTERPRETED BY**

Bradley Harris, DVM,  
 DACVECC, DACVIM  
 (cardiology)

**IMAGING PERFORMED BY**

Crystal Hill

**HOSPITAL NAME**

Main Street AH

**REFERRING VET**

Dr. Murphy

**INVOICE**

78326

**DATE**

6/3/26

into cardiac and non-cardiac causes. Cardiac conditions include structural heart disease, pericardial effusion/cardiac neoplasia, and rarely myocarditis. Non-cardiac causes are common and include splenic disease, metabolic disease, electrolyte disturbances, tick-borne disease, fever, anemia, trauma, GDV, hepatic disease, GI disease, pancreatitis, DIC, and sepsis. Given the breed, arrhythmogenic right ventricular cardiomyopathy is a concern.

**INTERPRETATION OF THE FINDINGS & FURTHER RECOMMENDATIONS**

Given these findings, no cardiac therapy is recommended. There are no cardiac contraindications to fluid therapy or corticosteroid therapy, as indicated for further assessment and treatment. While therapy is not specifically indicated based on these findings, further diagnostics might help tailor therapeutic recommendations. Consider the following:

- Abdominal ultrasound to look for abdominal causes of VPCs (e.g., splenic/adrenal changes)
- Consider 24-48 hour ambulatory ECG (Holter) monitor to assess significance of arrhythmia

Anesthesia considerations:

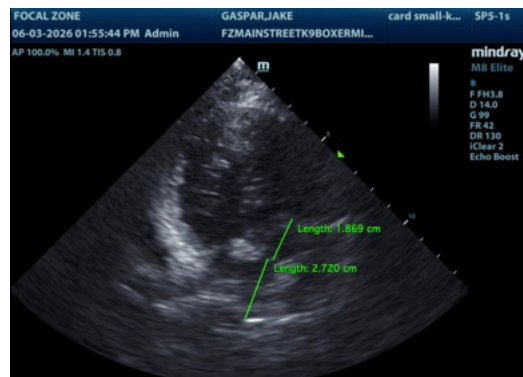
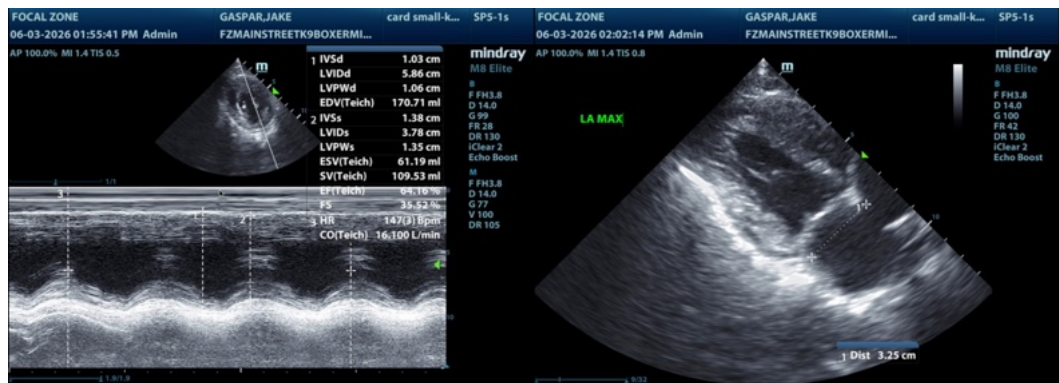No special considerations are necessary.

Diet:

No special considerations are necessary. Any high-quality food from Hills, Royal Canin, Science Diet, Eukanuba, Iams, or Purina is reasonable.

Activity:

No special considerations are necessary.





**PATIENT**

Jake Gaspar

**SPECIES**

Canine

**BREED**

Canine

**SEX**

Boxer

**AGE**

3 years

**WEIGHT**

26.9 kg

**INTERPRETED BY**

Bradley Harris, DVM,  
DACVECC, DACVIM  
(cardiology)

**IMAGING PERFORMED BY**

Crystal Hill

**HOSPITAL NAME**

Main Street AH

**REFERRING VET**

Dr. Murphy

**INVOICE**

78326

**DATE**

6/3/26

The information and recommendations provided are based on the images presented by the referring veterinarian/sonographer. No evaluation can be communicated regarding pathology that was not visible in the image/video clips provided.

Thank you for this referral. If the clinical or image interpretation does not parallel your findings or if I can be of any further assistance please contact me.

Bradley Harris, DVM, DACVECC, DACVIM (cardiology)

[info@SonoPath.com](mailto:info@SonoPath.com)