

PATIENT PRESENTING CLINICAL SIGNS

Winston Wulvhill

History: Grade 3-4/6 systolic heart murmur with PMI cranial sternum
 No progression of heart murmur and no development of new clinical signs
 Due for a recheck echocardiogram as it has been just over 1 year since the last
 Current Medications

SPECIES

Feline

Amlodipine

BREED

Siamese

Abnormal PE/Chem/CBC/UA Results: Monocytosis - Monocytes 0.58 (0.04 - 0.47 x10⁹/L) H IDEXX
 SDMA - 17 (0 - 14 µg/dL) H Creatinine - 254 (80 - 203 µmol/L) H Urea (BUN) - 15.1 (5.7 - 13.2 mmol/L) L

SEX

Neutered male

AGE

18 years

WEIGHT

5.3 kg

ULTRASONOGRAPHIC EXAMINATION OF THE HEART

The left atrium is normal in dimension. There are no distinct left atrial thrombi/clots or spontaneous echo contrast appreciated. The left ventricle is normal in dimension as well as wall thickness, and no evidence of restriction. Left ventricular systolic function is normal, with adequate contractility. The right atrium and ventricle are subjectively normal in dimension and systolic function. The anterior and posterior mitral and tricuspid valve leaflets presented normal linear structure, extension in systole, and union in diastole without regurgitation. There is no evidence of systolic anterior mitral valve motion documented. The left ventricular outflow tract demonstrated normal laminar flow and subjective structural valvular integrity. The visible aorta is unremarkable. Pulmonary outflow tract assessment revealed normal valve structure, laminar flow, and appropriate diameter and distensibility. There is no evidence of pulmonary hypertension documented. There is no visible pericardial, pleural, or free peritoneal fluid noted.

INTERPRETED BY

Bradley Harris, DVM,
 DACVECC, DACVIM
 (cardiology)

IMAGING PERFORMED BY

Kelly Reschny

HOSPITAL NAME

Chippawa AH

REFERRING VET

Dr. Kilkenny

INVOICE

75244

DATE

5/6/26

| FELINE CARDIAC PARAMETERS | BODY WEIGHT (kg) | HR (BPM) | IVSd (cm) | LVIDd (cm) | LVWd (cm) | FS (%) | EF (%) |
|--|------------------|---------------------------|----------------------|------------|-----------------|-----------------|----------|
| NORMAL PARAMETER | ----- | 150-240 | 0.3-0.6 | 1.0-2.1 | 0.25-0.6 | 35-67 | 80-100 |
| PATIENT | 5.3 kg | 220 | 0.44 | 1.23 | 0.41 | 71 | 97 |
| FELINE CARDIAC PARAMETERS | LA/AO (M-mode) | LA/AO HEART BASE (Sisson) | LAD LA MAX 4 Chamber | | LVOT VEL. (m/s) | RVOT VEL. (m/s) | IVRT (m) |
| NORMAL PARAMETER | <1.5 | 1.6 | 0.7-1.7 | | <1.6 | <1.3 | 40-60 |
| PATIENT | 1.09 | 1.16 | 1.63 | | 0.8 | 1.2 | NM |
| Adapted from June Boon, Veterinary Echocardiography, 1998 Sisson D et al. JVIM 1991; 5: 232, Jacobs et al. Am J Vet Res 1985; 46:1705 | | | | | | | |

ULTRASONOGRAPHIC FINDINGS

These findings are consistent with an essentially normal echocardiogram. Any murmur auscultated will be considered functional in origin (secondary to the previously noted dynamic right ventricular outflow tract).



PATIENT

Winston Wulvhill

SPECIES

Feline

BREED

Siamese

SEX

Neutered male

AGE

18 years

WEIGHT

5.3 kg

INTERPRETED BY

Bradley Harris, DVM,
 DACVECC, DACVIM
 (cardiology)

IMAGING PERFORMED BY

Kelly Reschny

HOSPITAL NAME

Chippawa AH

REFERRING VET

Dr. Kilkenny

INVOICE

75244

DATE

5/6/26

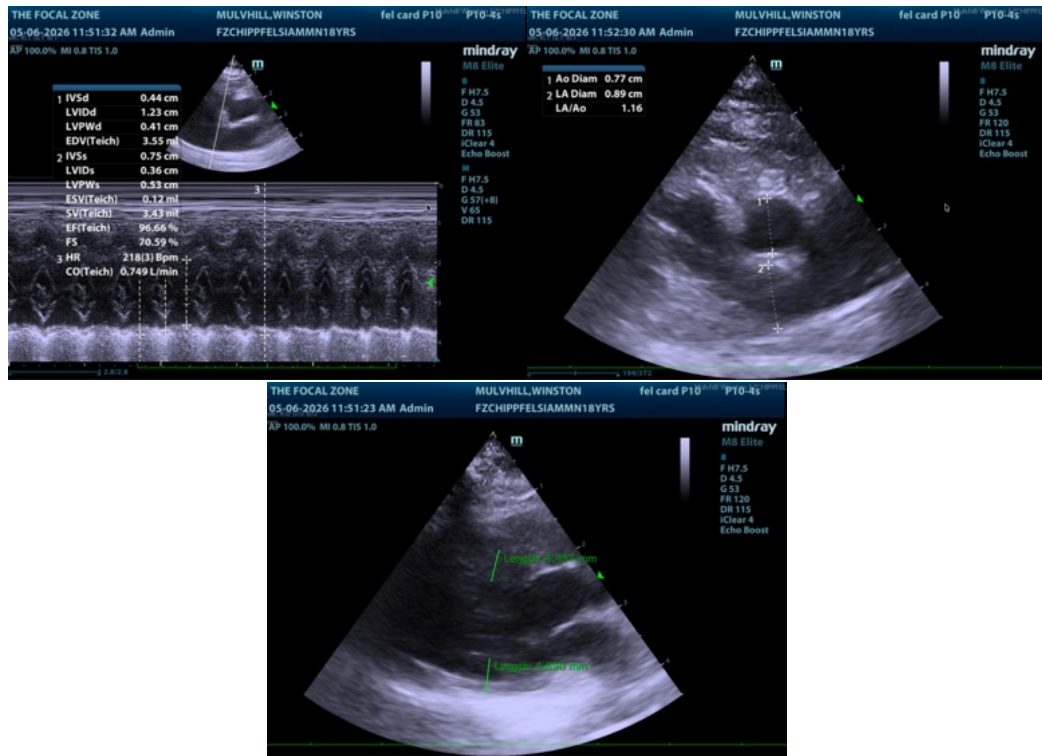
INTERPRETATION OF THE FINDINGS & FURTHER RECOMMENDATIONS

Given these findings, no cardiac therapy is recommended. There are no cardiac contraindications to corticosteroids or fluid therapy as indicated for further treatment. No specific recheck echocardiogram is recommended.

Anesthesia considerations:
 No special cardiac considerations are necessary

Diet:
 No special considerations are necessary. Any high-quality food from Hills, Royal Canin, Science Diet, Eukanuba, Iams, or Purina is reasonable.

Activity:
 No special considerations are necessary.



The information and recommendations provided are based on the images presented by the referring veterinarian/sonographer. No evaluation can be communicated regarding pathology that was not visible in the image/video clips provided.

Thank you for this referral. If the clinical or image interpretation does not parallel your findings or if I can be of any further assistance please contact me.



PATIENT

Bradley Harris, DVM, DACVECC, DACVIM (cardiology)

Winston Wulvhill

info@SonoPath.com

SPECIES

Feline

BREED

Siamese

SEX

Neutered male

AGE

18 years

WEIGHT

5.3 kg

INTERPRETED BY

Bradley Harris, DVM,
DACVECC, DACVIM
(cardiology)

**IMAGING
PERFORMED BY**

Kelly Reschny

HOSPITAL NAME

Chippawa AH

REFERRING VET

Dr. Kilkenny

INVOICE

75244

DATE

5/6/26