

PATIENT

Jamby Busby

SPECIES

Canine

BREED

Chihuahua

SEX

Intact female

AGE

16 years

WEIGHT

7 lbs

INTERPRETED BY

Bradley Harris, DVM,
 DACVECC, DACVIM
 (cardiology)

IMAGING PERFORMED BY

Crystal Hill

HOSPITAL NAME

Creditview Eglington
 AH

REFERRING VET

Dr. Ghobrial

INVOICE

77924

DATE

5/25/26

PRESENTING CLINICAL SIGNS

History: Last echo and ECG done Sept 2025, was diagnosed with Chronic Degenerative Valve disease. Has not been on any meds. Assess progression of heart disease.

ULTRASONOGRAPHIC EXAMINATION OF THE HEART

The left atrium is normal in dimension. The left ventricle is normal in dimension, with normal systolic function. The right atrium and ventricle are normal in dimension, with normal systolic function. The anterior and posterior mitral valve leaflets are thickened and redundant consistent with myxomatous changes, and there is minimal prolapse. There is mild mitral regurgitation identified. The tricuspid valve leaflets are minimally thickened, with trivial tricuspid regurgitation and no evidence of pulmonary hypertension. The left ventricular outflow tract demonstrated normal laminar flow and the visible aorta is unremarkable. The right ventricular outflow tract assessment revealed normal laminar flow, with appropriate main pulmonary artery diameter and right pulmonary artery distensibility. There is no pulmonic and no aortic valve insufficiency identified. There is no visible pericardial, pleural, or free peritoneal fluid documented. No evidence of hepatic venous congestion is noted. The cardiac chambers, pericardial and visible extra-cardiac regions were free of masses, spontaneous echo contrast, or thrombi.

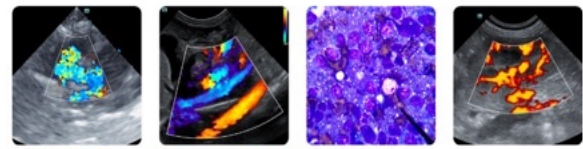
| CANINE CARDIAC PARAMETERS | Body Weight kg | HR BPM | LAD 4 ch Long | RAD 4 ch Long | La/Ao Heart Base | LVIDd | LVIDs |
|---------------------------|----------------|--------|----------------|------------------|------------------|---------|----------------------------------|
| NORMAL PARAMETER | | 50-100 | | | <1.6 | | |
| PATIENT | 3.18 kg | 190 | 1.93 | 1.72 | 1.44 | 1.83 | 1.22 |
| CANINE CARDIAC PARAMETERS | FS | EPSS | PV V MAX (m/s) | AV V Max (m/sec) | MR Vmax | TR Vmax | RPA distensibility (normal >30%) |
| NORMAL PARAMETER | 28-40 | <0.6 | 0.7-1.6 | 0.7-1.7 | 4.5-5.5 | < 2.7 | |
| PATIENT | 33 | 0.2 | 1.0 | 1.1 | 4.8 | <2.0 | NM |

ECG:

A six-lead ECG at a paper speed of 25mm/s, 10mm/mV is available for review. The average heart rate is approximately 190bpm, with a normal mean electrical axis. The QRS complexes are sinus in origin, with appropriate P-Q intervals. There are irregular R-R intervals, consistent with respiratory variation. There is no evidence of atrial or ventricular ectopy, nor any atrioventricular block. The underlying rhythm is most consistent with a respiratory sinus arrhythmia (normal physiologic change).

ULTRASONOGRAPHIC FINDINGS

These findings are consistent with degenerative/myxomatous mitral valve disease with minimal to mild hemodynamic effects consistent with ACVIM Stage B1 disease. It is unlikely that any current morbidity is of cardiac origin.



PATIENT

Jamby Busby

SPECIES

Canine

BREED

Chihuahua

SEX

Intact female

AGE

16 years

WEIGHT

7 lbs

INTERPRETED BY

Bradley Harris, DVM,
 DACVECC, DACVIM
 (cardiology)

IMAGING PERFORMED BY

Crystal Hill

HOSPITAL NAME

Creditview Eglington
 AH

REFERRING VET

Dr. Ghobrial

INVOICE

77924

DATE

5/25/26

INTERPRETATION OF THE FINDINGS & FURTHER RECOMMENDATIONS

Given these findings, no cardiac therapy is recommended. There are no cardiac contraindications to anesthesia, fluid therapy, vasopressor therapy, or corticosteroids as indicated for further assessment and treatment. If not already performed, baseline thoracic radiographs and blood pressure are recommended. A recheck echocardiogram is recommended in 6 months.

Anesthesia considerations:

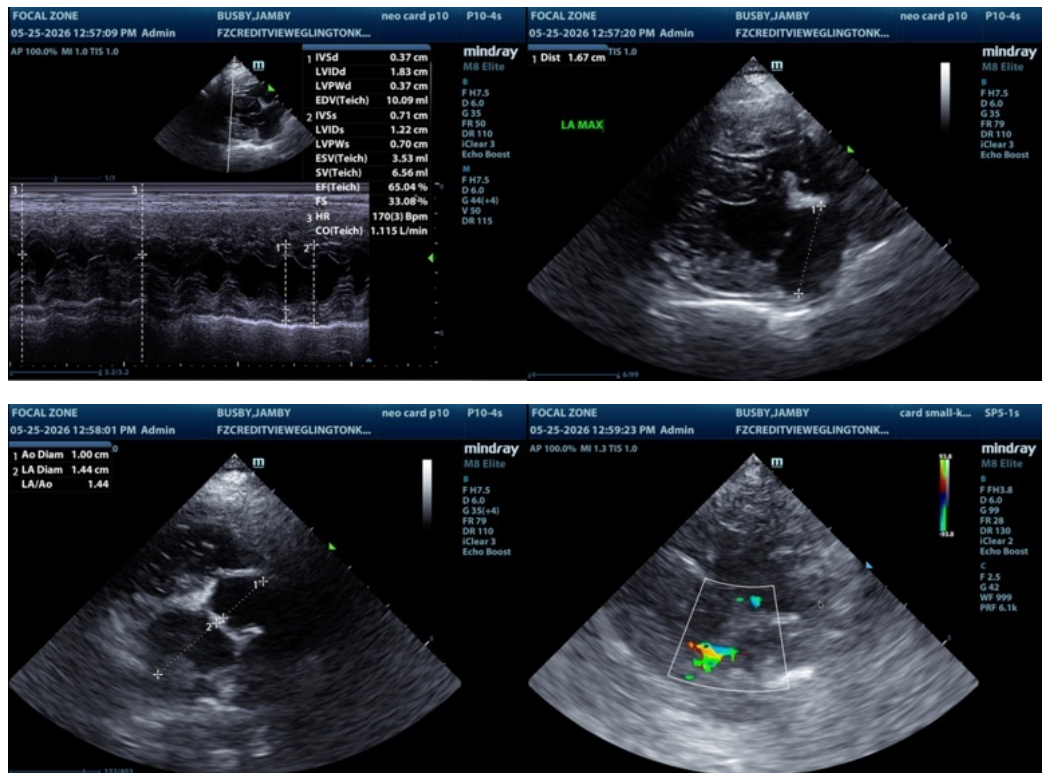
If anesthesia is necessary, alpha-2 agonists, ketamine, high dose acepromazine, and Telazol should be avoided. Fluid therapy during anesthesia should be considered at a conservative rate (e.g., 5 ml/kg/hour) if possible.

Diet:

A high-quality food from Hills, Royal Canin, Science Diet, Eukanuba, Iams, or Purina that is highly palatable with adequate protein and calories for maintaining optimal body condition is reasonable.

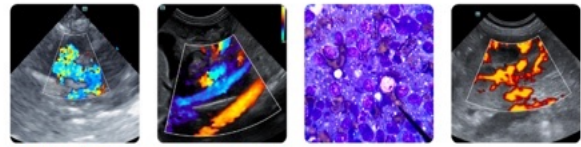
Activity:

No special considerations are necessary.



The information and recommendations provided are based on the images presented by the referring veterinarian/sonographer. No evaluation can be communicated regarding pathology that was not visible in the image/video clips provided.

Thank you for this referral. If the clinical or image interpretation does not parallel your findings or if I can be of any further assistance please contact me.



PATIENT

Bradley Harris, DVM, DACVECC, DACVIM (cardiology)

Jamby Busby

info@SonoPath.com

SPECIES

Canine

BREED

Chihuahua

SEX

Intact female

AGE

16 years

WEIGHT

7 lbs

INTERPRETED BY

Bradley Harris, DVM,
DACVECC, DACVIM
(cardiology)

**IMAGING
PERFORMED BY**

Crystal Hill

HOSPITAL NAME

Creditview Eglington
AH

REFERRING VET

Dr. Ghobrial

INVOICE

77924

DATE

5/25/26